A 28-year-old African American man is given prophylactic medications and vaccinations before a business trip to Africa. Five days later, he comes to the emergency department due to jaundice and dark urine. Laboratory results are as follows:

Hemoglobin	8.2 g/dL
Reticulocytes	8.0%
Total bilirubin	3.5 mg/dL
Direct bilirubin	1.1 mg/dL
Lactate dehydrogenase	342 U/L
Haptoglobin	42 mg/dL (normal: 50-150 mg/dL)

A peripheral smear shows red blood cells with dark inclusions when stained with supravital stain. This patient's condition most likely has which of the following inheritance patterns?

- A. Autosomal dominant inheritance
- B. Autosomal recessive inheritance
- C. Mitochondrial inheritance
- D. X-linked dominant inheritance
- E. X-linked recessive inheritance

Submit

A 28-year-old African American man is given prophylactic medications and vaccinations before a business trip to Africa. Five days later, he comes to the emergency department due to jaundice and dark urine. Laboratory results are as follows:

Hemoglobin	8.2 g/dL
Reticulocytes	8.0%
Total bilirubin	3.5 mg/dL
Direct bilirubin	1.1 mg/dL
Lactate dehydrogenase	342 U/L
Haptoglobin	42 mg/dL (normal: 50-150 mg/dL)

A peripheral smear shows red blood cells with dark inclusions when stained with supravital stain. This patient's condition most likely has which of the following inheritance patterns?

A. Autosomal dominant inheritance (7%)
B. Autosomal recessive inheritance (31%)
C. Mitochondrial inheritance (1%)
D. X-linked dominant inheritance (3%)
✓ E. X-linked recessive inheritance (57%)

Omitted
Correct answer

57%
Answered correctly

30 secs
Time Spent

01/21/2020
Last Updated

Explanation

This patient has the classic history of hemolytic anemia due to medication-induced oxidative stress. The antimalarial drugs usually prescribed for travelers to affected regions (eg, certain parts of Africa) are notorious instigators of **hemolysis** in individuals with **glucose-6-phosphate dehydrogenase (G6PD) deficiency**. Laboratory studies reflect intravascular and extravascular hemolysis with anemia, reticulocytosis, indirect hyperbilirubinemia, and low haptoglobin (due to the removal of free hemoglobin-haptoglobin complexes). Peripheral blood smear shows red blood cells with **Heinz bodies**, dark, intracellular inclusions that stain with supravital stain and represent hemoglobin that has denatured/precipitated from oxidative stress. Heinz bodies are strongly associated with G6PD deficiency and other unstable hemoglobinopathies.

The expression of G6PD is determined by a gene located on the X chromosome and has **X-linked recessive** inheritance. Among individuals with the mutation, males are affected and females are generally carriers.

(Choices A and B) Most structural abnormalities follow an autosomal dominant pattern, whereas most enzyme deficiencies follow an autosomal recessive pattern. For example, hereditary spherocytosis is most often autosomal dominant.

(Choice C) In a zygote, all of the mitochondria are inherited from the mother. These mitochondria have a small genome, so defects are transmitted only from mothers but affect offspring of both genders. Mitochondrial diseases generally affect oxidative phosphorylation (eg, Leber hereditary optic neuropathy).

(Choice D) In X-linked dominant inheritance, there is 100% risk to female offspring of an affected male. For example, vitamin D-resistant rickets has an X-linked dominant inheritance pattern.

Educational objective:
Glucose-6-phosphate dehydrogenase deficiency has an X-linked recessive inheritance. Hereditary spherocytosis follows an autosomal dominant inheritance pattern.

Pathology	Hematology & Oncology	G6PD deficiency
Subject	System	Topic

Copyright © UWorld. All rights reserved.

The age-adjusted mortality trends for 5 cancers in women in the United States are shown in the graph below.

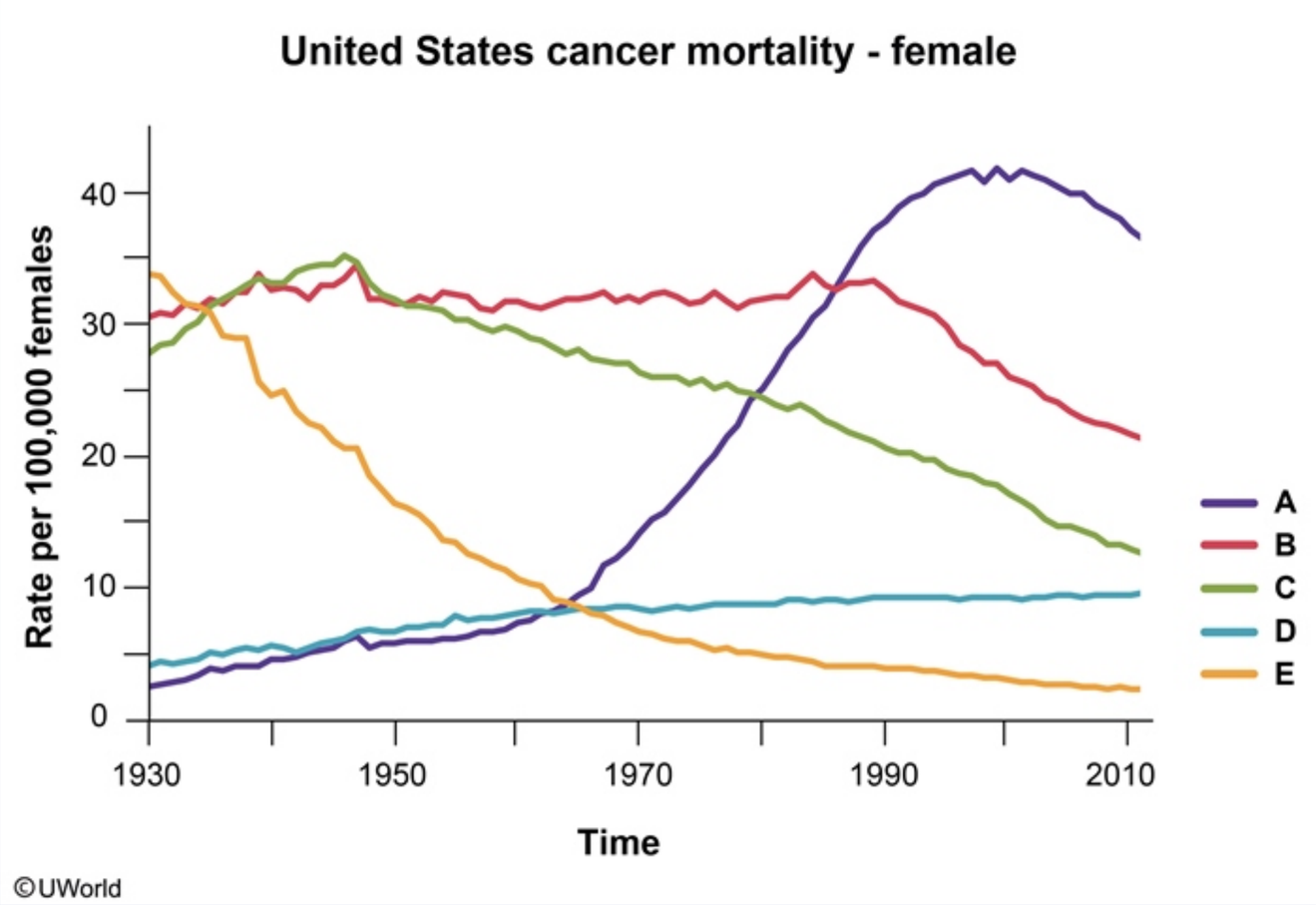

Which of the following curves best corresponds to lung cancer?

A. A

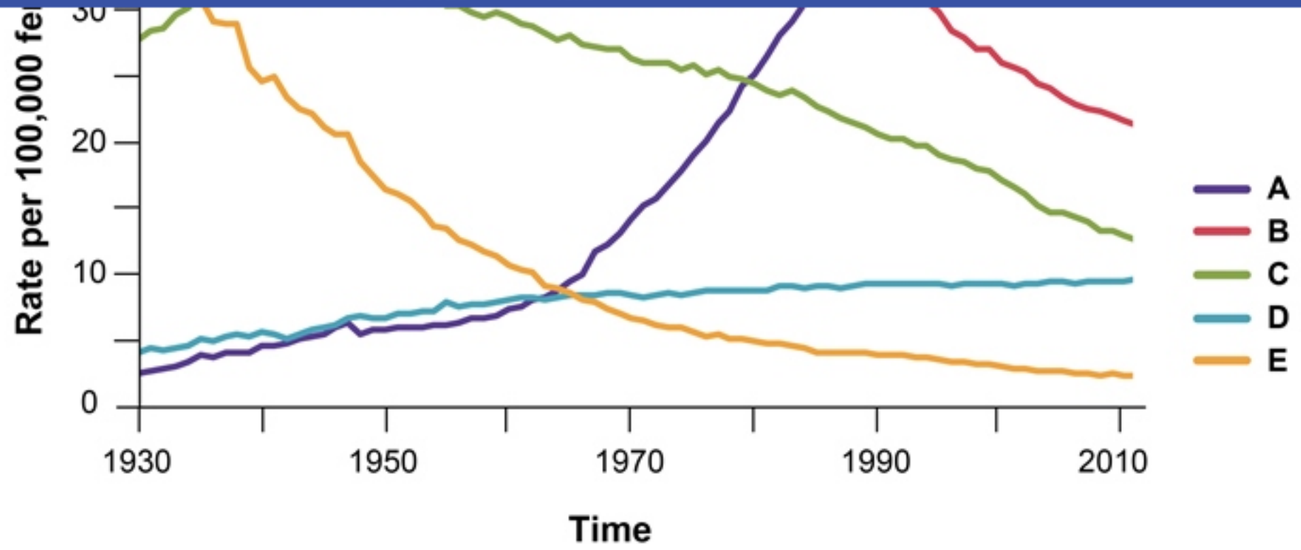

©UWorld

Which of the following curves best corresponds to lung cancer?

- A. A
- B. B
- C. C
- D. D
- E. E

Submit

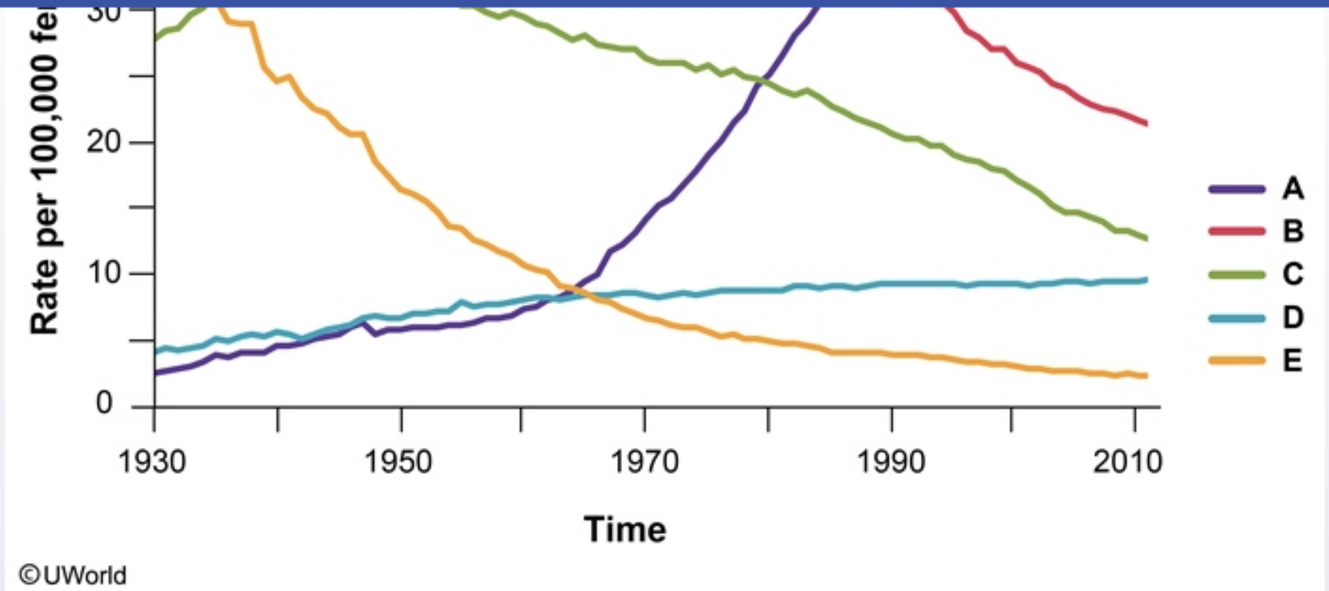

Which of the following curves best corresponds to lung cancer?

- ✓ A. A (78%)
- B. B (12%)
- C. C (3%)
- D. D (5%)
- E. E (0%)

Omitted
Correct answer

78%
Answered correctly

03 secs
Time Spent

06/21/2020
Last Updated

Explanation

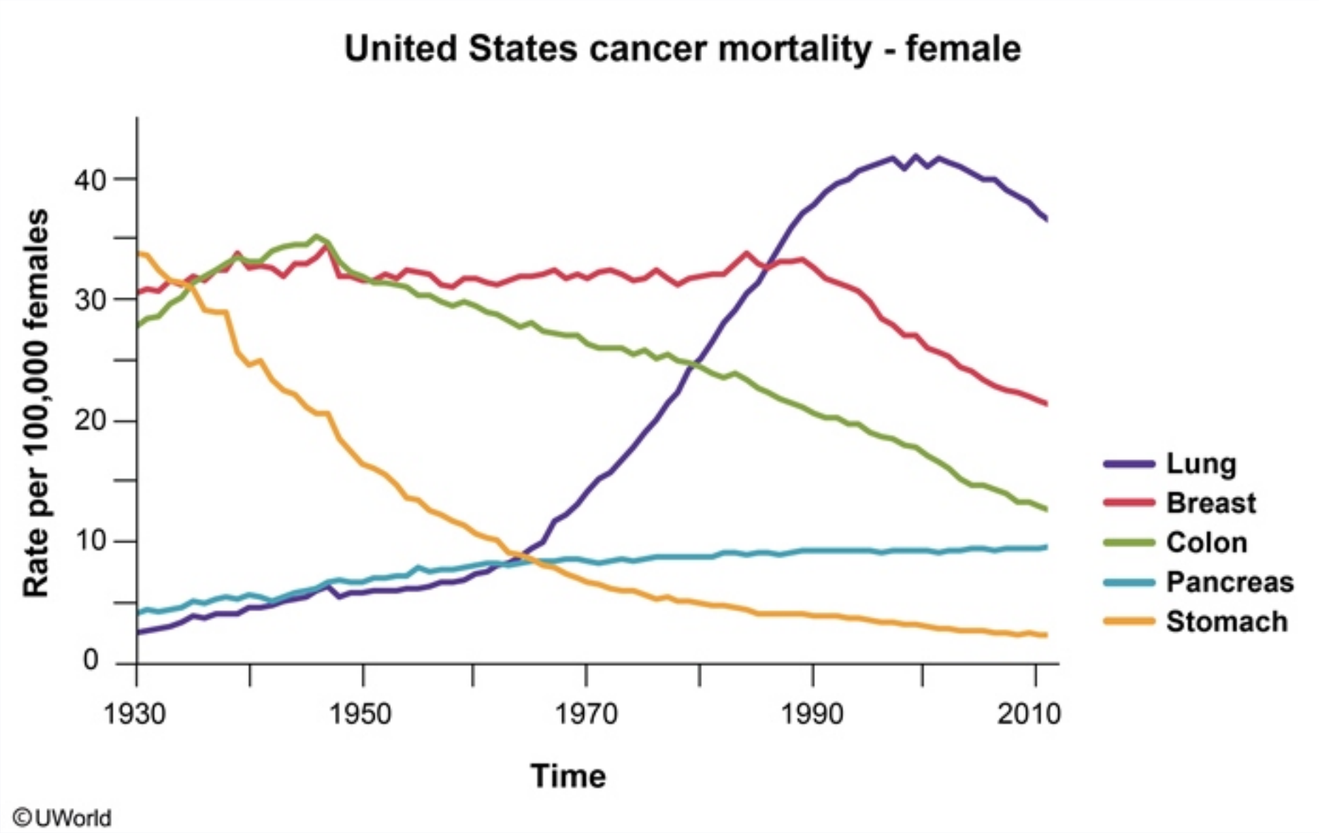

Lung cancer has been the leading cause of **cancer mortality** in both **women** and men in the United States since the 1980s. **Tobacco use** (primary and secondhand) is the most important cause of lung cancer, particularly **non-small cell** lung cancer. Female use of cigarettes peaked in 1955, and mortality rates increased 20-50 years after smoking onset. Lung cancer mortality began to decrease after 2000, corresponding to a decline in tobacco use.

Tobacco is a causative factor for numerous other cancers (eg, leukemia, nasopharyngeal, larynx, esophagus, pancreas, cervix, colon). It is

©UWorld

Lung cancer has been the leading cause of **cancer mortality** in both **women** and men in the United States since the 1980s. **Tobacco use** (primary and secondhand) is the most important cause of lung cancer, particularly **non-small cell** lung cancer. Female use of cigarettes peaked in 1955, and mortality rates increased 20-50 years after smoking onset. Lung cancer mortality began to decrease after 2000, corresponding to a decline in tobacco use.

Tobacco is a causative factor for numerous other cancers (eg, leukemia, nasopharyngeal, larynx, esophagus, pancreas, cervix, colon). It is directly carcinogenic to tissue by causing irritation and inflammation of the body's natural protective barriers. Patient education about tobacco's harmful effects is extremely important, as smoking cessation for even longtime users can be beneficial for reducing cancer risk and improving life expectancy.

(Choice B) Breast cancer is the most common non-skin cancer and the second most common cause of cancer death among women in the United States. Mortality from breast cancer began to decrease in the 1990s. Increased use of adjuvant chemotherapy and/or radiation and more frequent breast cancer screening are likely contributing factors to this decline.

(Choice C) Colon cancer mortality has decreased since the 1950s due to advances in surgical technique and adjuvant chemotherapy. Additional protective factors may include colorectal cancer screening, menopausal hormone therapy in women, and aspirin use.

(Choice D) The incidence and mortality of pancreatic cancer have increased in women over the last century and recently became the fourth most common cause of cancer death in women. Pancreatic cancer trends, like those of lung cancer, follow the pattern of increased smoking in women. However, lung cancer is responsible for three times more deaths than pancreatic cancer in women.

(Choice E) Stomach cancer incidence and mortality decreased drastically over the first half of the twentieth century. Proposed reasons include advances in refrigeration and food preservation (leading to decreased salt intake), and better sanitation and more adequate housing (reducing *Helicobacter pylori* infection rates).

Educational objective:
Between 1950 and 2000, rising rates of tobacco use resulted in an increase in female lung cancer incidence and mortality. Lung cancer is currently the most common cause of cancer death in both women and men in the United States.

References

©UWorld

Exhibit Display

Cancer in United States populations: 2008-2012		
	Highest incidence	**Highest mortality**
Female	1. Breast 2. Lung 3. Colon 4. Uterus 5. Thyroid	1. Lung 2. Breast 3. Colon 4. Pancreas 5. Ovary
Male	1. Prostate 2. Lung 3. Colon 4. Bladder 5. Melanoma	1. Lung 2. Prostate 3. Colon 4. Pancreas 5. Bladder

©UWorld

Zoom In | Zoom Out | Reset | Add To New Card | Existing Card

References

Tobacco is a causative factor for numerous other cancers (eg, leukemia, nasopharyngeal, larynx, esophagus, pancreas, cervix, colon). It is directly carcinogenic to tissue by causing irritation and inflammation of the body's natural protective barriers. Patient education about tobacco's harmful effects is extremely important, as smoking cessation for even longtime users can be beneficial for reducing cancer risk and improving life expectancy.

(Choice B) Breast cancer is the most common non-skin cancer and the second most common cause of cancer death among women in the United States. Mortality from breast cancer began to decrease in the 1990s. Increased use of adjuvant chemotherapy and/or radiation and more frequent breast cancer screening are likely contributing factors to this decline.

(Choice C) Colon cancer mortality has decreased since the 1950s due to advances in surgical technique and adjuvant chemotherapy. Additional protective factors may include colorectal cancer screening, menopausal hormone therapy in women, and aspirin use.

(Choice D) The incidence and mortality of pancreatic cancer have increased in women over the last century and recently became the fourth most common cause of cancer death in women. Pancreatic cancer trends, like those of lung cancer, follow the pattern of increased smoking in women. However, lung cancer is responsible for three times more deaths than pancreatic cancer in women.

(Choice E) Stomach cancer incidence and mortality decreased drastically over the first half of the twentieth century. Proposed reasons include advances in refrigeration and food preservation (leading to decreased salt intake), and better sanitation and more adequate housing (reducing *Helicobacter pylori* infection rates).

Educational objective:
Between 1950 and 2000, rising rates of tobacco use resulted in an increase in female lung cancer incidence and mortality. Lung cancer is currently the most common cause of cancer death in both women and men in the United States.

References

- Lung cancer incidence trends among men and women--United States, 2005-2009.
- Impact of reduced tobacco smoking on lung cancer mortality in the United States during 1975-2000.
- Long-term trends in cancer mortality in the United States, 1930-1998.
- Deaths: Final data for 2011.

A 28-year-old previously healthy man comes to the office due to episodic fevers, night sweats, and weight loss for several months. He emigrated from Kenya with his family at age 14. He does not use tobacco, alcohol, or illicit drugs. The patient works as a driving instructor and volunteers at a homeless shelter. His temperature is 37.2 C (99 F). Physical examination is normal with the exception of cervical lymphadenopathy. A lymph node biopsy is performed, and a histopathology slide is shown in the image below.

a homeless shelter. His temperature is 37.2 °C (99 °F). Physical examination is normal with the exception of cervical lymphadenopathy. A lymph node biopsy is performed, and a histopathology slide is shown in the image below.

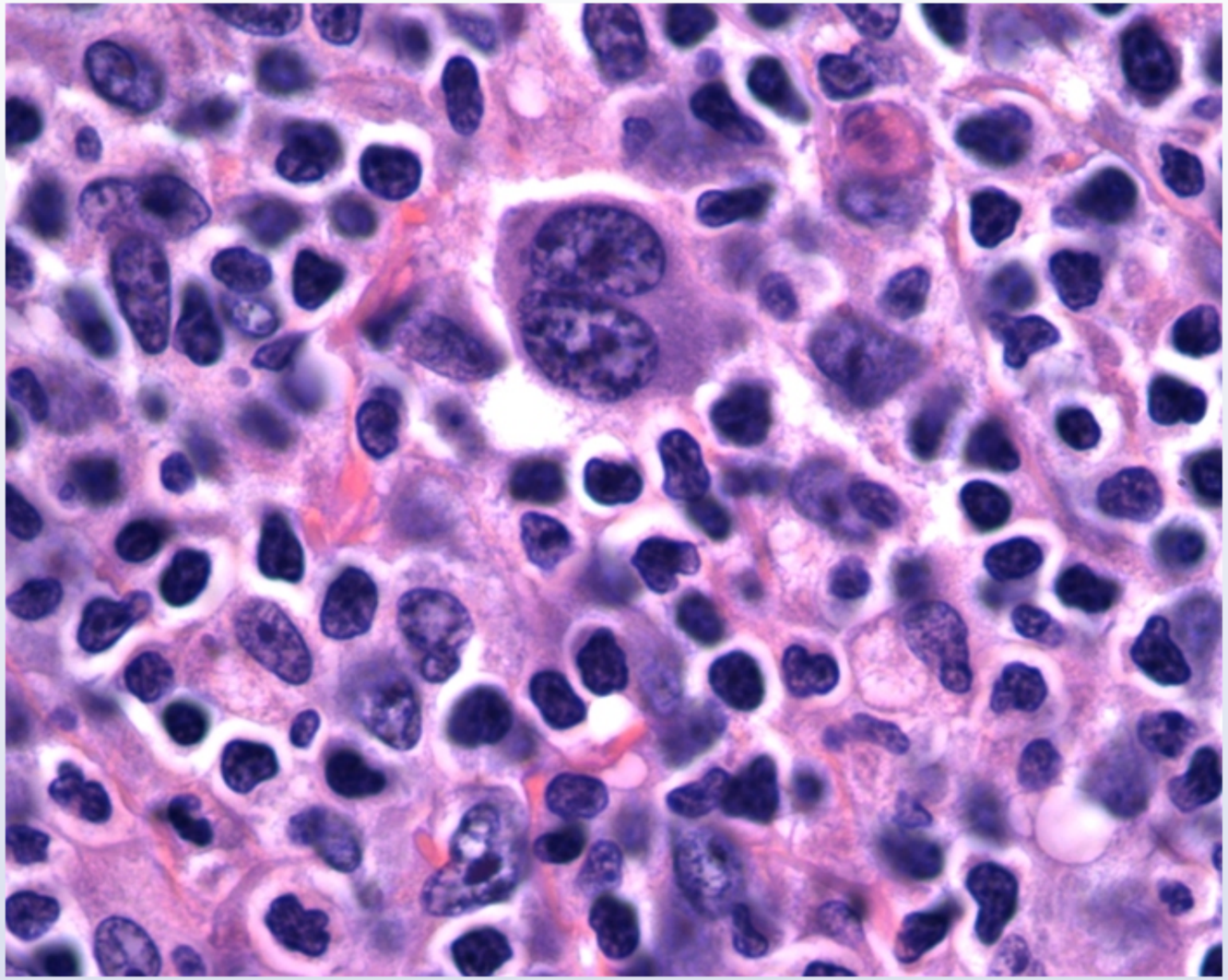

Which of the following is the most likely diagnosis?

1
2
3
4
5
6
7
8
9
10
11
12
13
14
15
16
17
18
19
20
21
22
23
24
25
26
27
28
29
30

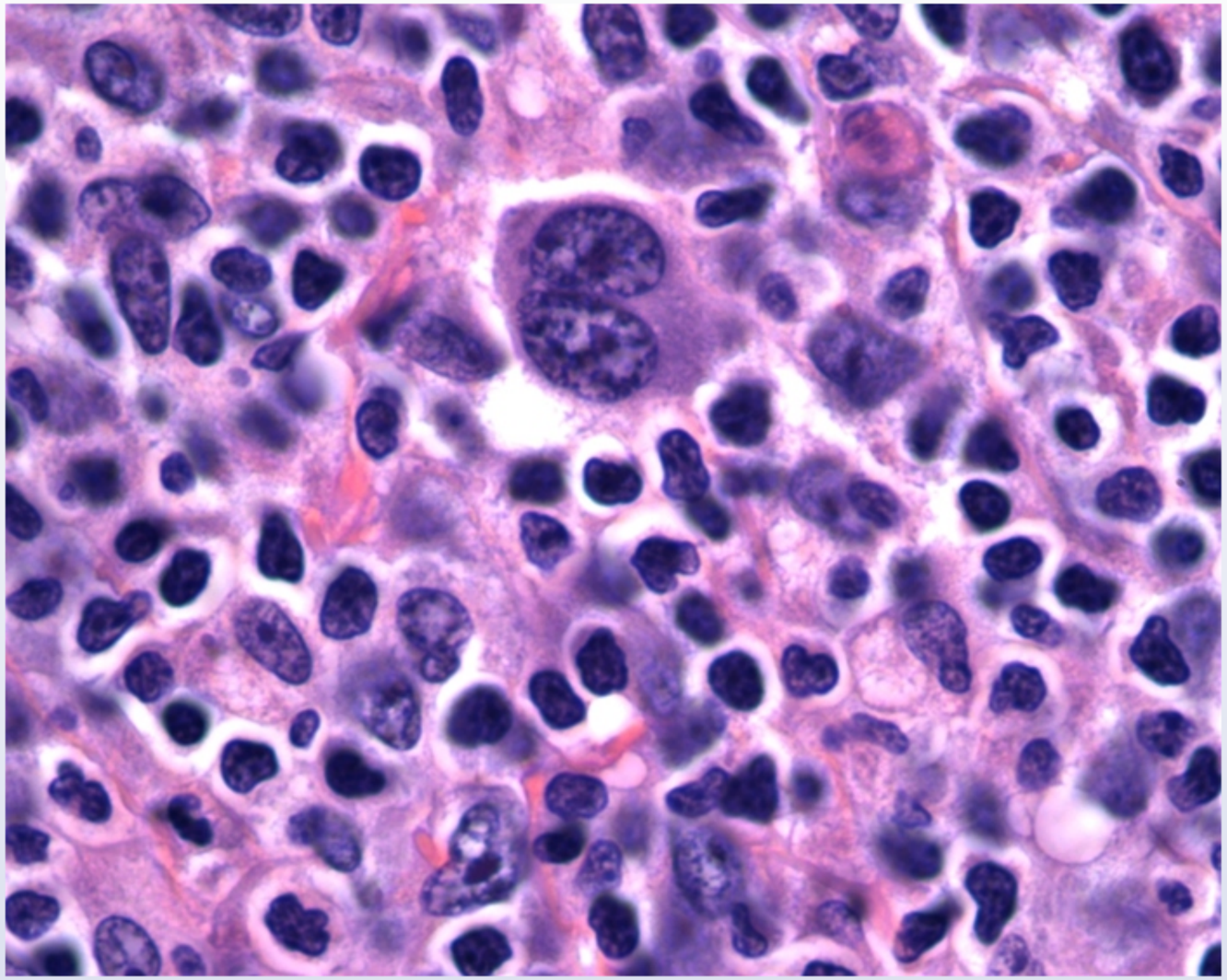

Which of the following is the most likely diagnosis?

A. Burkitt lymphoma

1
2
3
4
5
6
7
8
9
10
11
12
13
14
15
16
17
18
19
20
21
22
23
24
25
26
27
28
29
30

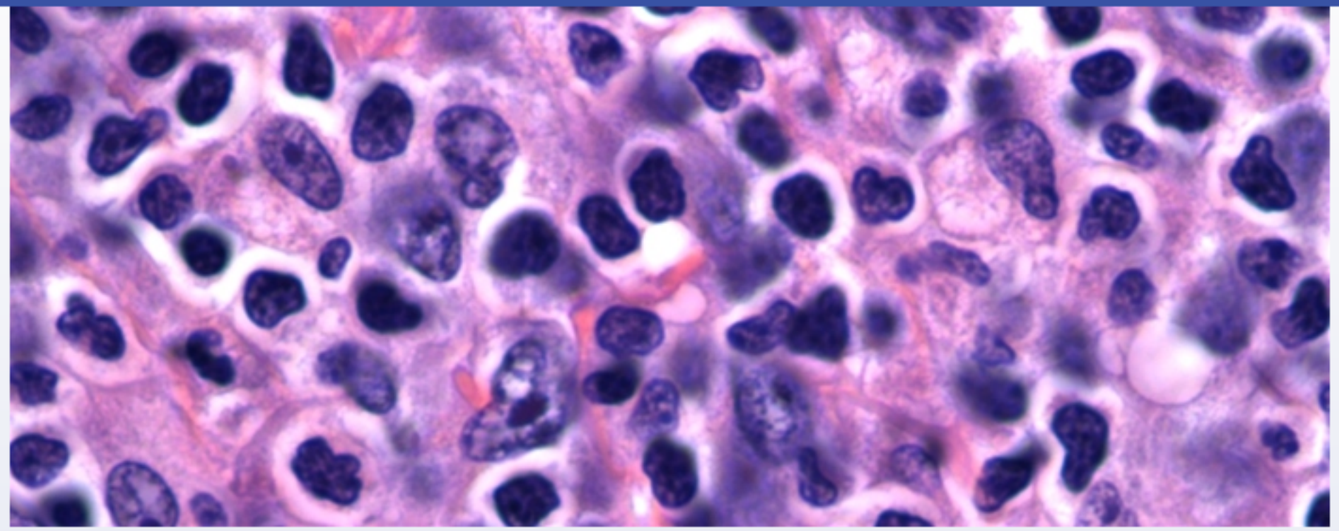

Which of the following is the most likely diagnosis?

A. Burkitt lymphoma
B. Follicular lymphoma
C. Hodgkin lymphoma
D. Large B-cell lymphoma
E. Multiple myeloma
F. Tuberculosis

Submit

1
2
3
4
5
6
7
8
9
10
11
12
13
14
15
16
17
18
19
20
21
22
23
24
25
26
27
28
29
30

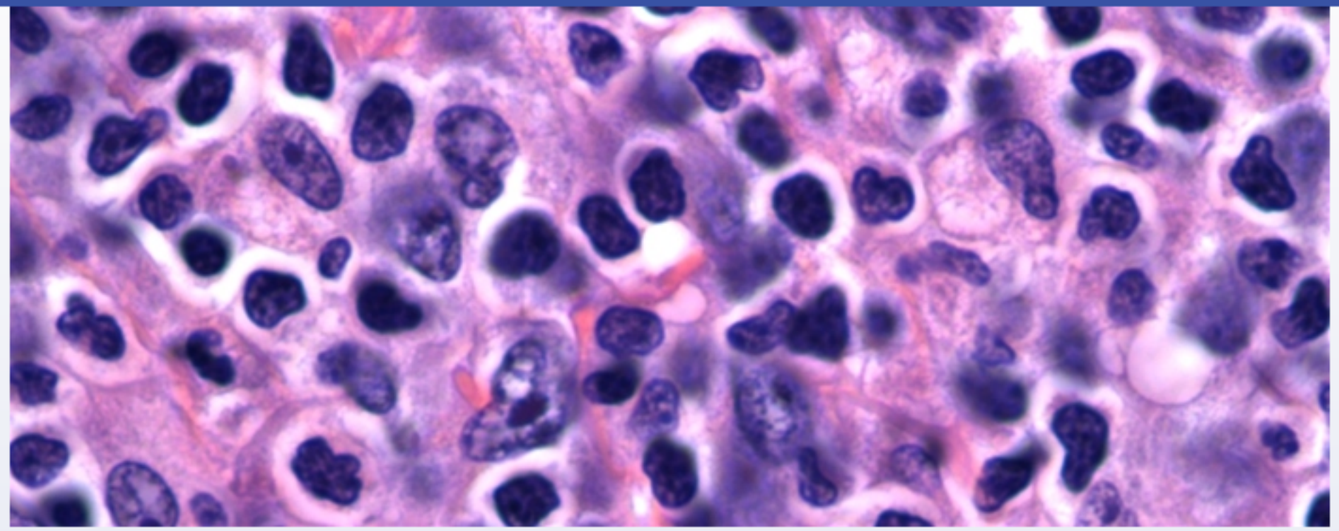

Which of the following is the most likely diagnosis?

- A. Burkitt lymphoma (11%)
- B. Follicular lymphoma (1%)
- ✓ C. Hodgkin lymphoma (83%)
- D. Large B-cell lymphoma (1%)
- E. Multiple myeloma (0%)
- F. Tuberculosis (1%)

Omitted
Correct answer

83%
Answered correctly

07 secs
Time Spent

01/29/2020
Last Updated

1
2
3
4
5
6
7
8
9
10
11
12
13
14
15
16
17
18
19
20
21
22
23
24
25
26
27
28
29
30

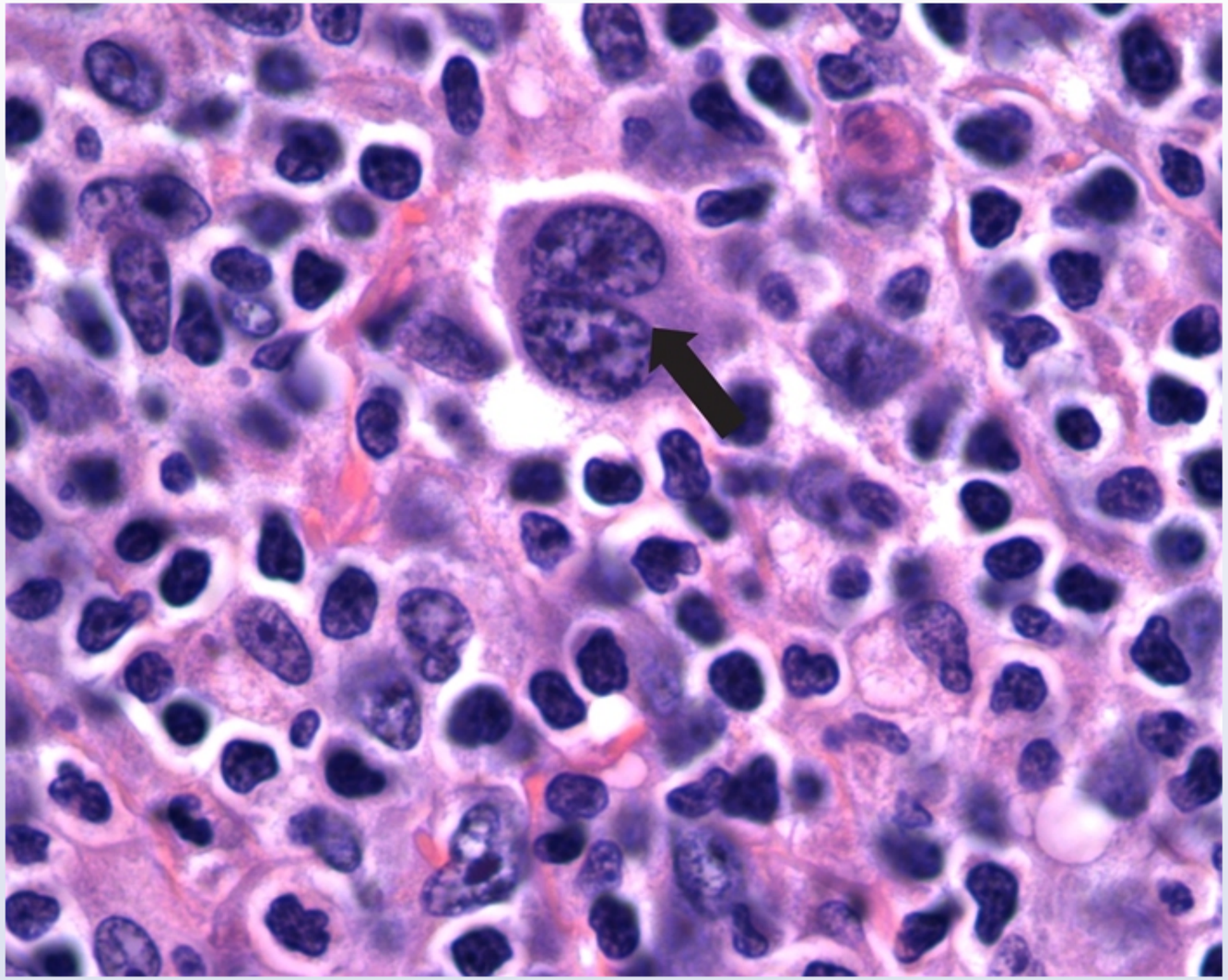

This patient most likely has classic **Hodgkin lymphoma (HL)**. The typical presentation is either nontender **lymphadenopathy** or lymphadenopathy incidentally detected on routine chest x-ray. Many patients develop associated systemic **B symptoms** (fevers, night sweats,

This patient most likely has classic **Hodgkin lymphoma (HL)**. The typical presentation is either nontender **lymphadenopathy** or lymphadenopathy incidentally detected on routine chest x-ray. Many patients develop associated systemic **B symptoms** (fevers, night sweats, weight loss). HL has a **bimodal age distribution** with a peak in the 20s (or younger in some countries) and another in the 60s. The complete blood count and peripheral blood smear are usually unremarkable. A **lymph node biopsy** can definitively distinguish this malignancy from benign causes of lymphadenopathy. The key to diagnosing classic HL is detecting the characteristic **Reed-Sternberg** (RS) cell (arrow) on hematoxylin and eosin preparation. RS cells have ample cytoplasm, bilobed or double nuclei, and inclusion-like eosinophilic nucleoli. RS cells are seen against a background of lymphocytes, histiocytes, and eosinophils in classical HL.

(Choice A) Burkitt lymphoma is a high-grade lymphoma that often presents as a mass in the abdomen, pelvis, or jaw (in endemic cases in Africa with a peak incidence in boys around age 5). However, histology would show a monotonous population of medium-sized lymphocytes with many tingible body macrophages, giving a "starry sky" appearance. High numbers of mitotic cells and apoptotic bodies would be seen.

(Choice B) Follicular lymphoma shows aggregates of closely packed lymph node follicles. Two major cell types, centrocytes (small cleaved cells) and centroblasts (large noncleaved cells), are observed. Older adults tend to be affected. Waxing and waning painless lymphadenopathy (typically without B symptoms) is common.

(Choice D) The histological presentation of large B-cell lymphoma is diffuse sheets of large lymphocytes with nuclei at least 5 times the size of small lymphocytes. No RS cells are seen.

(Choice E) Multiple myeloma, a plasma cell dyscrasia characterized by proliferation of mature and immature plasma cells (similar in appearance to normal plasma cells), is predominantly a disease of the elderly. It is characterized by osteolytic lesions, although spread to nodal and extranodal sites can occur.

(Choice F) Tuberculosis is on the differential diagnosis for this patient, who is from Kenya, volunteers at homeless shelters, and has had night sweats and weight loss. However, histology in tuberculosis would show caseating granulomas, not RS cells.

Educational objective:
The presence of Reed-Sternberg (RS) cells on lymph node biopsy is diagnostic of classic Hodgkin lymphoma. RS cells have abundant cytoplasm, bilobed or double nuclei, and inclusion-like eosinophilic nucleoli.

1
2
3
4
5
6
7
8
9
10
11
12
13
14
15
16
17
18
19
20
21
22
23
24
25
26
27
28
29
30

Exhibit Display

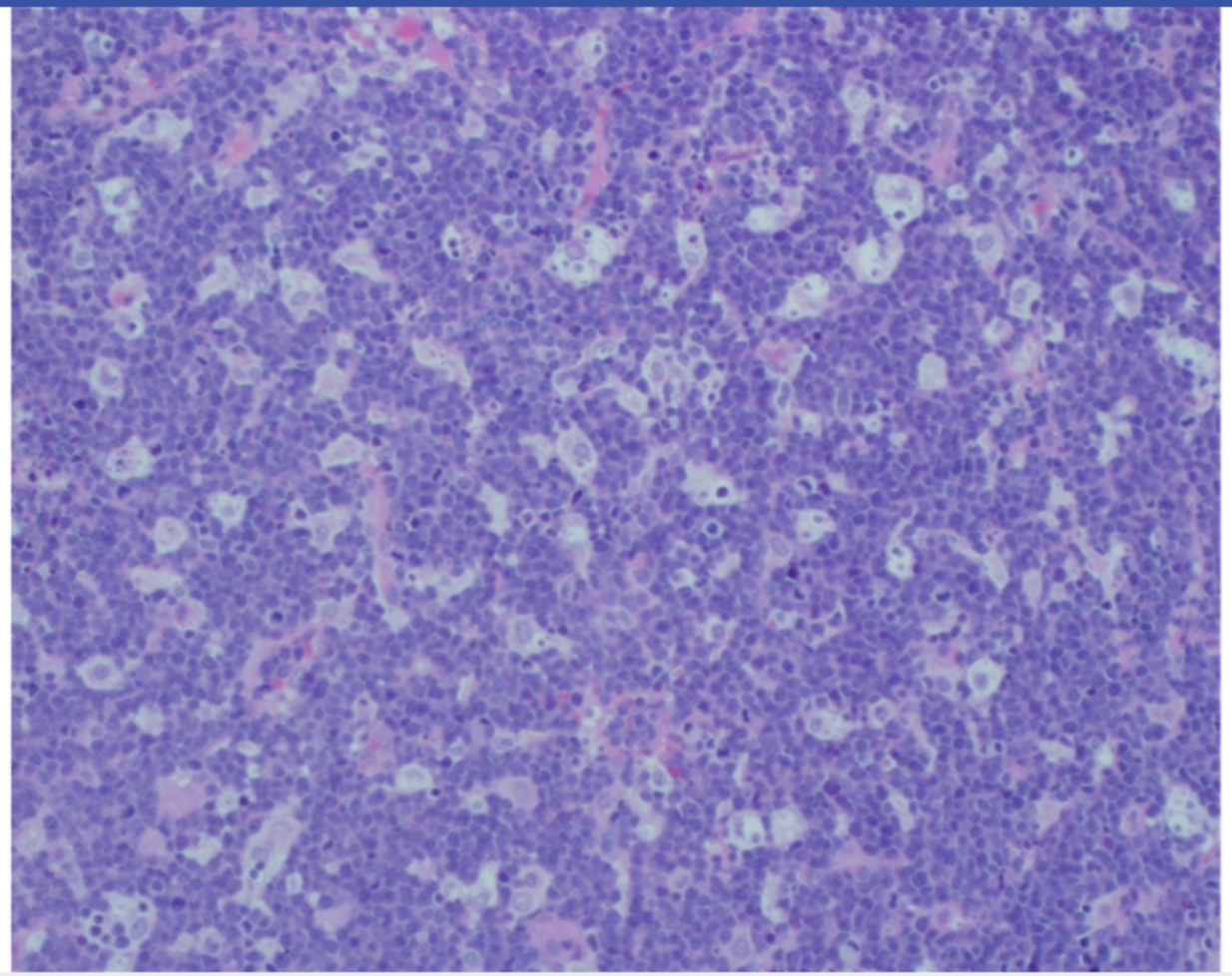

Zoom In | Zoom Out | Reset | Add To New Card | Existing Card

causes of lymphadenopathy. The key to diagnosing classic HL is detecting the characteristic **Reed-Sternberg** (RS) cell (arrow) on hematoxylin and eosin preparation. RS cells have ample cytoplasm, bilobed or double nuclei, and inclusion-like eosinophilic nucleoli. RS cells are seen against a background of lymphocytes, histiocytes, and eosinophils in classical HL.

(Choice A) Burkitt lymphoma is a high-grade lymphoma that often presents as a mass in the abdomen, pelvis, or jaw (in endemic cases in Africa with a peak incidence in boys around age 5). However, histology would show a monotonous population of medium-sized lymphocytes with many tingible body macrophages, giving a "starry sky" appearance. High numbers of mitotic cells and apoptotic bodies would be seen.

(Choice B) Follicular lymphoma shows aggregates of closely packed lymph node follicles. Two major cell types, centrocytes (small cleaved cells) and centroblasts (large noncleaved cells), are observed. Older adults tend to be affected. Waxing and waning painless lymphadenopathy (typically without B symptoms) is common.

(Choice D) The histological presentation of large B-cell lymphoma is diffuse sheets of large lymphocytes with nuclei at least 5 times the size of small lymphocytes. No RS cells are seen.

(Choice E) Multiple myeloma, a plasma cell dyscrasia characterized by proliferation of mature and immature plasma cells (similar in appearance to normal plasma cells), is predominantly a disease of the elderly. It is characterized by osteolytic lesions, although spread to nodal and extranodal sites can occur.

(Choice F) Tuberculosis is on the differential diagnosis for this patient, who is from Kenya, volunteers at homeless shelters, and has had night sweats and weight loss. However, histology in tuberculosis would show caseating granulomas, not RS cells.

Educational objective:
The presence of Reed-Sternberg (RS) cells on lymph node biopsy is diagnostic of classic Hodgkin lymphoma. RS cells have abundant cytoplasm, bilobed or double nuclei, and inclusion-like eosinophilic nucleoli.

Pathology	Hematology & Oncology	Hodgkins lymphoma
Subject	System	Topic

Copyright © UWorld. All rights reserved.

A 43-year-old Caucasian female complaining of reduced energy and fatigue is found to have hypochromic, microcytic anemia. Her past medical history is significant for stable angina treated with metoprolol and aspirin. Iron supplementation is prescribed. Several weeks later, a peripheral blood smear demonstrates numerous enlarged red blood cells that appear blue on Wright-Giemsa stain. The bluish color of these red blood cells is best explained by the presence of which of the following?

- A. Hemoglobin precipitates
- B. Nuclear membrane
- C. Ribosomal RNA
- D. Histones
- E. Mitochondria
- F. Golgi apparatus

Submit

A 43-year-old Caucasian female complaining of reduced energy and fatigue is found to have hypochromic, microcytic anemia. Her past medical history is significant for stable angina treated with metoprolol and aspirin. Iron supplementation is prescribed. Several weeks later, a peripheral blood smear demonstrates numerous enlarged red blood cells that appear blue on Wright-Giemsa stain. The bluish color of these red blood cells is best explained by the presence of which of the following?

- A. Hemoglobin precipitates (26%)
- B. Nuclear membrane (12%)
- ✓ C. Ribosomal RNA (44%)
- D. Histones (5%)
- E. Mitochondria (10%)
- F. Golgi apparatus (1%)

Omitted
Correct answer
C

44%
Answered correctly

02 secs
Time Spent

02/03/2020
Last Updated

Explanation

This patient suffers from hypochromic, microcytic anemia most likely caused by iron deficiency. Iron-deficient individuals on replacement therapy should experience hemoglobin level increases of approximately 2 g/dL per week for the first three weeks. This increase in hemoglobin results from enhanced erythropoiesis and the accelerated release of both mature red blood cells (RBCs) and reticulocytes into the bloodstream.

Omitted
Correct answer
C

44%
Answered correctly

02 secs
Time Spent

02/03/2020
Last Updated

Explanation

This patient suffers from hypochromic, microcytic anemia most likely caused by iron deficiency. Iron-deficient individuals on replacement therapy should experience hemoglobin level increases of approximately 2 g/dL per week for the first three weeks. This increase in hemoglobin results from enhanced erythropoiesis and the accelerated release of both mature red blood cells (RBCs) and reticulocytes into the bloodstream.

The reticulocyte is an immature RBC that is slightly larger and bluer than a mature RBC. It lacks a cell nucleus but retains a basophilic, reticular (mesh-like) network of residual ribosomal RNA. The ribosomal RNA appears blue microscopically after the application of the Wright-Giemsa stain.

After spending a day or so in the bloodstream, the reticulocytes are transformed into mature red blood cells that have a lifespan of approximately 120 days.

(Choices A, B, D, E, and F) The blue color of the reticulocyte is not caused by hemoglobin precipitates, nuclear membranes, histones, mitochondria, or the Golgi apparatus.

Educational Objective:
Increased bone marrow erythropoiesis results in an accelerated release of immature red blood cells (reticulocytes) into the bloodstream. Reticulocytes contain bluish cytoplasm and reticular precipitates of residual ribosomal RNA.

Pathology	Hematology & Oncology	Iron deficiency anemia
Subject	System	Topic

Copyright © UWorld. All rights reserved.

A 24-year-old African-American man comes to the office after a rapid HIV test was positive at a health fair. Additional laboratory evaluation reveals a HIV viral load of 240,000 copies/mL and a CD4 count of 180 cells/mm^3. The patient is given a prescription for antiretroviral therapy. He is also given dapsone for *Pneumocystis jiroveci* pneumonia prophylaxis due to a history of rash with trimethoprim-sulfamethoxazole. Pneumococcal and influenza vaccines are administered. A few days later, the patient returns to the office due to fatigue, jaundice, and dark urine. Laboratory results now show the following:

Complete blood count

Hemoglobin	9.0 g/dL
Mean corpuscular volume	85 μm^3
Reticulocytes	7.1%
Platelets	234,000/mm^3
Leukocytes	5,500/mm^3

Coagulation studies are within normal limits. Peripheral smear reveals red blood cell fragments, microspherocytes, and bite cells. Which of the following is the most likely underlying cause of this patient's symptoms?

A. Abnormal sickling due to medication
B. Disseminated intravascular coagulation
C. Enzyme-deficiency hemolytic anemia
D. Red blood cell cytoskeleton abnormality
E. Vaccine-induced hemolysis

A 24-year-old African-American man comes to the office after a rapid HIV test was positive at a health fair. Additional laboratory evaluation reveals a HIV viral load of 240,000 copies/mL and a CD4 count of 180 cells/mm^3. The patient is given a prescription for antiretroviral therapy. He is also given dapsone for *Pneumocystis jiroveci* pneumonia prophylaxis due to a history of rash with trimethoprim-sulfamethoxazole. Pneumococcal and influenza vaccines are administered. A few days later, the patient returns to the office due to fatigue, jaundice, and dark urine. Laboratory results now show the following:

Complete blood count

Hemoglobin	9.0 g/dL
Mean corpuscular volume	85 μm^3
Reticulocytes	7.1%
Platelets	234,000/mm^3
Leukocytes	5,500/mm^3

Coagulation studies are within normal limits. Peripheral smear reveals red blood cell fragments, microspherocytes, and bite cells. Which of the following is the most likely underlying cause of this patient's symptoms?

A. Abnormal sickling due to medication
B. Disseminated intravascular coagulation
C. Enzyme-deficiency hemolytic anemia
D. Red blood cell cytoskeleton abnormality
E. Vaccine-induced hemolysis

reveals a HIV viral load of 210,000 copies/mL and a CD4 count of 180 cells/mm³. The patient is given a prescription for antiretroviral therapy. He is also given dapsone for *Pneumocystis jiroveci* pneumonia prophylaxis due to a history of rash with trimethoprim-sulfamethoxazole. Pneumococcal and influenza vaccines are administered. A few days later, the patient returns to the office due to fatigue, jaundice, and dark urine. Laboratory results now show the following:

Complete blood count

Hemoglobin	9.0 g/dL
Mean corpuscular volume	85 μm^3
Reticulocytes	7.1%
Platelets	234,000/mm^3
Leukocytes	5,500/mm^3

Coagulation studies are within normal limits. Peripheral smear reveals red blood cell fragments, microspherocytes, and bite cells. Which of the following is the most likely underlying cause of this patient's symptoms?

- A. Abnormal sickling due to medication (4%)
- B. Disseminated intravascular coagulation (0%)
- ✓ C. Enzyme-deficiency hemolytic anemia (88%)
- D. Red blood cell cytoskeleton abnormality (3%)
- E. Vaccine-induced hemolysis (2%)

Omitted
Correct answer

88%
Answered correctly

04 secs
Time Spent

06/08/2020
Last Updated

Glucose-6-phosphate dehydrogenase deficiency	
Epidemiology	• Hemolytic anemia due to oxidative stress (infection, sulfa drugs, fava beans) • X-linked: Asian, African, or Middle Eastern descent
Manifestations	• Pallor & fatigue • Dark urine, jaundice & icterus • Abdominal/back pain
Laboratory findings	• Hemolysis: ↓ hemoglobin, ↓ haptoglobin, ↑ bilirubin & LDH, ↑ reticulocytes • Peripheral smear: bite cells & Heinz bodies • Negative Coombs test • ↓ G6PD activity level (may be normal during attack)
Management	• Remove or treat responsible agent/condition • Provide supportive care
G6PD = glucose-6-phosphate dehydrogenase; **LDH** = lactate dehydrogenase.	

This patient developed symptomatic anemia (eg, fatigue) and signs of hemolysis (eg, jaundice, dark urine) after taking dapsone for a few days, indicating likely glucose-6-phosphate dehydrogenase **(G6PD) deficiency**. G6PD catalyzes the first step of NADPH production. Because NADPH is required to generate the reduced form glutathione (a potent antioxidant), patients with G6PD deficiency lack sufficient reductive capacity to handle significant **oxidative stressors** and typically develop erythrocyte damage/lysis with acute infection, oxidative foods (eg, fava beans), and oxidative medications (eg, **dapsone**, primaquine).

Oxidative injury to erythrocytes causes hemoglobin precipitation on the erythrocyte membrane (Heinz body) and impairs erythrocyte deformation while passing through the narrow sinusoids of the spleen. The damaged erythrocytes are identified and removed by splenic macrophages, leading to extravascular **hemolysis**.

Patients typically develop manifestations 2-4 days after the oxidative injury, including acute anemia and signs of elevated bilirubin (eg, **dark urine**,

G6PD – glucose-6-phosphate dehydrogenase, **LDH** – lactate dehydrogenase.

This patient developed symptomatic anemia (eg, fatigue) and signs of hemolysis (eg, jaundice, dark urine) after taking dapsone for a few days, indicating likely glucose-6-phosphate dehydrogenase **(G6PD) deficiency**. G6PD catalyzes the first step of NADPH production. Because NADPH is required to generate the reduced form glutathione (a potent antioxidant), patients with G6PD deficiency lack sufficient reductive capacity to handle significant **oxidative stressors** and typically develop erythrocyte damage/lysis with acute infection, oxidative foods (eg, fava beans), and oxidative medications (eg, **dapsone**, primaquine).

Oxidative injury to erythrocytes causes hemoglobin precipitation on the erythrocyte membrane (Heinz body) and impairs erythrocyte deformation while passing through the narrow sinusoids of the spleen. The damaged erythrocytes are identified and removed by splenic macrophages, leading to extravascular **hemolysis**.

Patients typically develop manifestations 2-4 days after the oxidative injury, including acute anemia and signs of elevated bilirubin (eg, **dark urine**, **jaundice**). Laboratory evaluation generally shows **significant reticulocytosis** because the bone marrow increases erythrocytosis to compensate for the anemia. Peripheral smear generally shows hemoglobin precipitation (Heinz bodies) on the periphery of red blood cells and bite cells due to phagocytic removal of precipitated hemoglobin by splenic macrophages. Because mild intravascular hemolysis also occurs (due to intravascular erythrocyte lysis from oxidative damage), schistocytes (fragmented red blood cells) and microspherocytes (round, dense schistocytes) are also frequently seen on peripheral smear.

(Choice A) Sickle cell anemia is a genetic mutation associated with erythrocyte sickling in the setting of deoxygenation and dehydration. Blood smear shows sickled red blood cells (not schistocytes), bite cells, and microspherocytes.

(Choice B) Disseminated intravascular coagulation is a consumptive coagulopathy characterized by intravascular clot formation, which shears red blood cells. Although schistocytes are seen on peripheral smear, Heinz bodies and bite cells are not. In addition, these patients have significant thrombocytopenia and prolonged coagulation times.

(Choice D) Hereditary spherocytosis, a genetic disorder marked by erythrocyte cytoskeleton abnormalities, is marked by abundant spherocytes, but not bite cells or schistocytes. In addition, this patient developed symptoms after dapsone administration, making G6PD more likely.

(Choice E) Pneumococcal and influenza vaccination does not typically trigger hemolysis. These vaccines can sometimes cause Guillain-Barré syndrome or rash.

Patients typically develop manifestations 2-4 days after the oxidative injury, including acute anemia and signs of elevated bilirubin (eg, **dark urine**, **jaundice**). Laboratory evaluation generally shows **significant reticulocytosis** because the bone marrow increases erythrocytosis to compensate for the anemia. Peripheral smear generally shows hemoglobin precipitation (Heinz bodies) on the periphery of red blood cells and bite cells due to phagocytic removal of precipitated hemoglobin by splenic macrophages. Because mild intravascular hemolysis also occurs (due to intravascular erythrocyte lysis from oxidative damage), schistocytes (fragmented red blood cells) and microspherocytes (round, dense schistocytes) are also frequently seen on peripheral smear.

(Choice A) Sickle cell anemia is a genetic mutation associated with erythrocyte sickling in the setting of deoxygenation and dehydration. Blood smear shows sickled red blood cells (not schistocytes), bite cells, and microspherocytes.

(Choice B) Disseminated intravascular coagulation is a consumptive coagulopathy characterized by intravascular clot formation, which shears red blood cells. Although schistocytes are seen on peripheral smear, Heinz bodies and bite cells are not. In addition, these patients have significant thrombocytopenia and prolonged coagulation times.

(Choice D) Hereditary spherocytosis, a genetic disorder marked by erythrocyte cytoskeleton abnormalities, is marked by abundant spherocytes, but not bite cells or schistocytes. In addition, this patient developed symptoms after dapsone administration, making G6PD more likely.

(Choice E) Pneumococcal and influenza vaccination does not typically trigger hemolysis. These vaccines can sometimes cause Guillain-Barré syndrome or rash.

Educational objective:
Glucose-6-phosphate dehydrogenase deficiency is characterized by episodes of hemolytic anemia following oxidative stress (eg, fava beans, dapsone, acute infection). Patients generally have jaundice, dark urine, normocytic anemia, reticulocytosis, and evidence of bite cells and Heinz bodies on peripheral smear.

Pathology	Hematology & Oncology	G6PD deficiency
Subject	System	Topic

Copyright © UWorld. All rights reserved.

Epidemiology

- Hemolytic anemia due to oxidative stress (infection, sulfa drugs, fava beans)

Exhibit Display

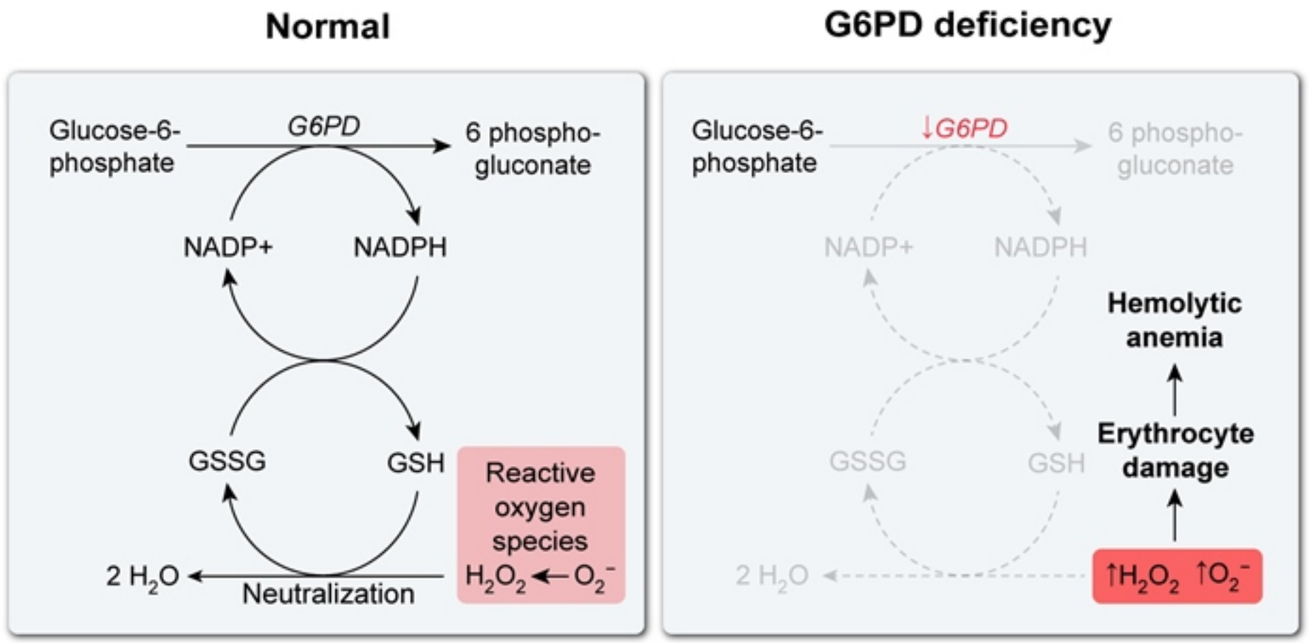

G6PD = glucose-6-phosphate dehydrogenase; **GSH** = glutathione; **GSSG** = glutathione disulfide.

©UWorld

Zoom In Zoom Out Reset Add To New Card | Existing Card

phagocytic removal of precipitated hemoglobin by splenic macrophages. Because mild intravascular hemolysis also occurs (due to intravascular

A 12-year-old boy is brought to the office by his mother due to headaches and gait instability. His symptoms began several months ago and have progressively worsened. MRI of the brain is shown in the image below.

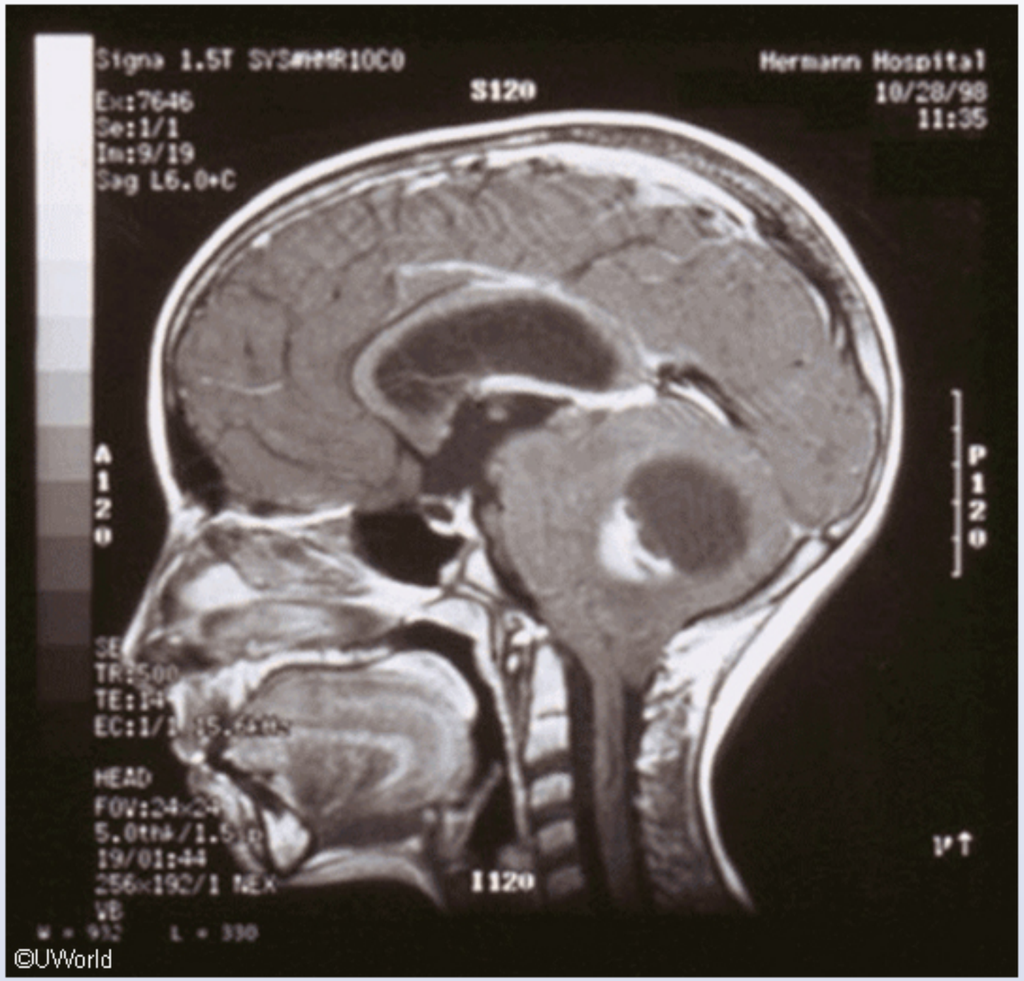

Which of the following is the most likely diagnosis?

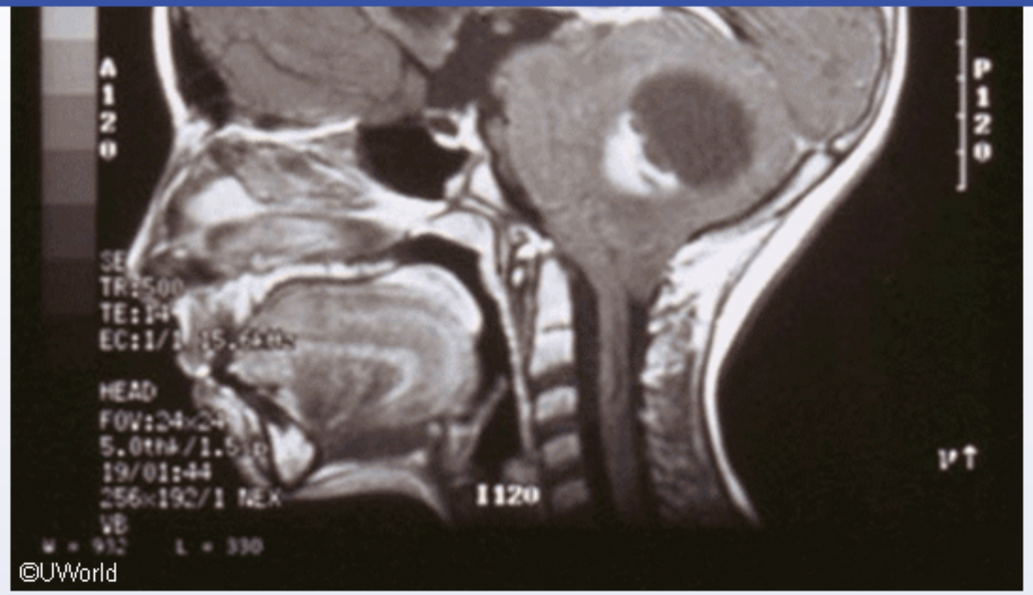

Which of the following is the most likely diagnosis?

- A. Ependymoma
- B. Glioblastoma multiforme
- C. Medulloblastoma
- D. Oligodendroglioma
- E. Pilocytic astrocytoma

Submit

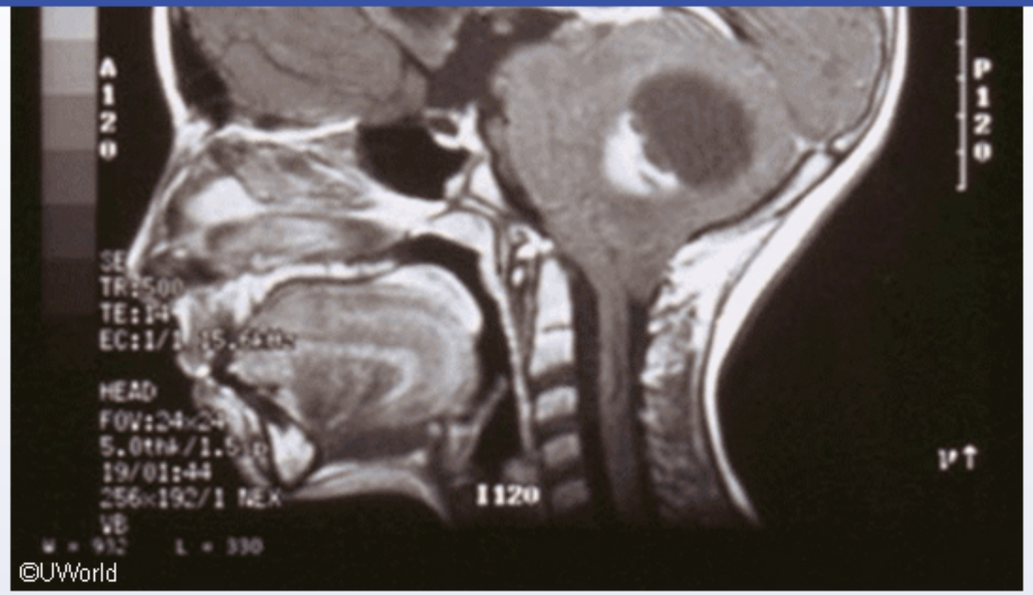

Which of the following is the most likely diagnosis?

- A. Ependymoma (9%)
- B. Glioblastoma multiforme (4%)
- C. Medulloblastoma (38%)
- D. Oligodendroglioma (1%)
- ✓ E. Pilocytic astrocytoma (46%)

Omitted
Correct answer

46%
Answered correctly

04 secs
Time Spent

06/02/2020
Last Updated

Explanation

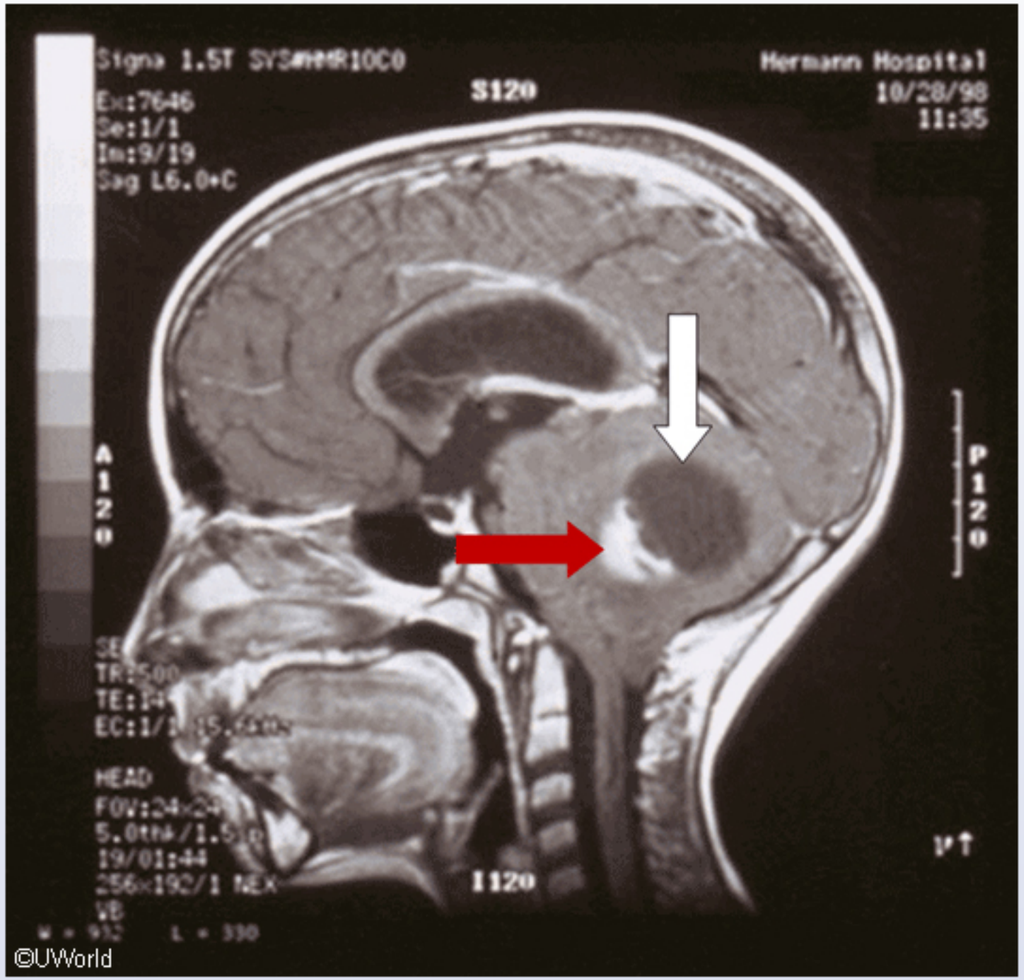

Brain tumors are the second most common childhood cancer (after leukemia) and the most common solid organ tumors of childhood. This child with a heterogeneous, well-circumscribed cerebellar mass most likely has a **pilocytic astrocytoma**, the most common type of brain tumor in

Brain tumors are the second most common childhood cancer (after leukemia) and the most common solid organ tumors of childhood. This child with a heterogeneous, well-circumscribed cerebellar mass most likely has a **pilocytic astrocytoma**, the most common type of brain tumor in children.

Pilocytic astrocytomas are **low-grade** gliomas that occur most frequently in the **cerebellum**. Patients typically have headaches and cerebellar findings (eg, loss of balance, incoordination). Imaging (shown above) reveals a well-demarcated lesion comprised of **cystic and solid components** (white and red arrows, respectively). Microscopic examination shows pilocytic astrocytes with bundles of **glial fibrillary acidic protein (GFAP)-positive** hairlike processes and classic **Rosenthal fibers** (eosinophilic intracytoplasmic inclusions). Due to the slow-growing (benign) nature, the majority of patients can be treated with surgical resection and have a favorable prognosis.

(Choice A) Ependymomas are rare tumors arising from the ependymal lining of the ventricle. They commonly occupy the 4th ventricle and can cause hydrocephalus by obstructing the flow of cerebrospinal fluid. Perivascular pseudorosettes are present on microscopy.

(Choice B) Glioblastoma multiforme, a tumor arising from GFAP-positive astrocytes, occurs most frequently in adults and is typically located within the cerebral hemispheres (often crossing the corpus callosum). Pseudopalisading pleomorphic cells with areas of necrosis are seen on microscopy.

(Choice C) Medulloblastoma is the most common *malignant* childhood brain cancer. It is located exclusively in the cerebellum; however, it is not cystic like pilocytic astrocytoma. Imaging reveals a solid lesion (encircled) that can compress the 4th ventricle, causing hydrocephalus (arrow). It is composed of small cells with hyperchromatic nuclei that form Homer Wright rosettes (groupings of cells surrounding the neuropil).

(Choice D) Oligodendrogliomas, rare in children, are frequently calcified, well-circumscribed masses located in the frontal lobe. Microscopy shows uniform cells with a "fried egg" appearance (ie, round nuclei with clear cytoplasm) surrounded by anastomosing capillaries arranged in a "chicken-wire" pattern.

Educational objective:
Pilocytic astrocytomas are the most common brain tumors in children. They frequently arise in the cerebellum and can be differentiated from medulloblastomas by the presence of both cystic and solid components on imaging.

References

- Pilocytic astrocytomas

1
2
3
4
5
6
7
8
9
10
11
12
13
14
15
16
17
18
19
20
21
22
23
24
25
26
27
28
29
30

Exhibit Display

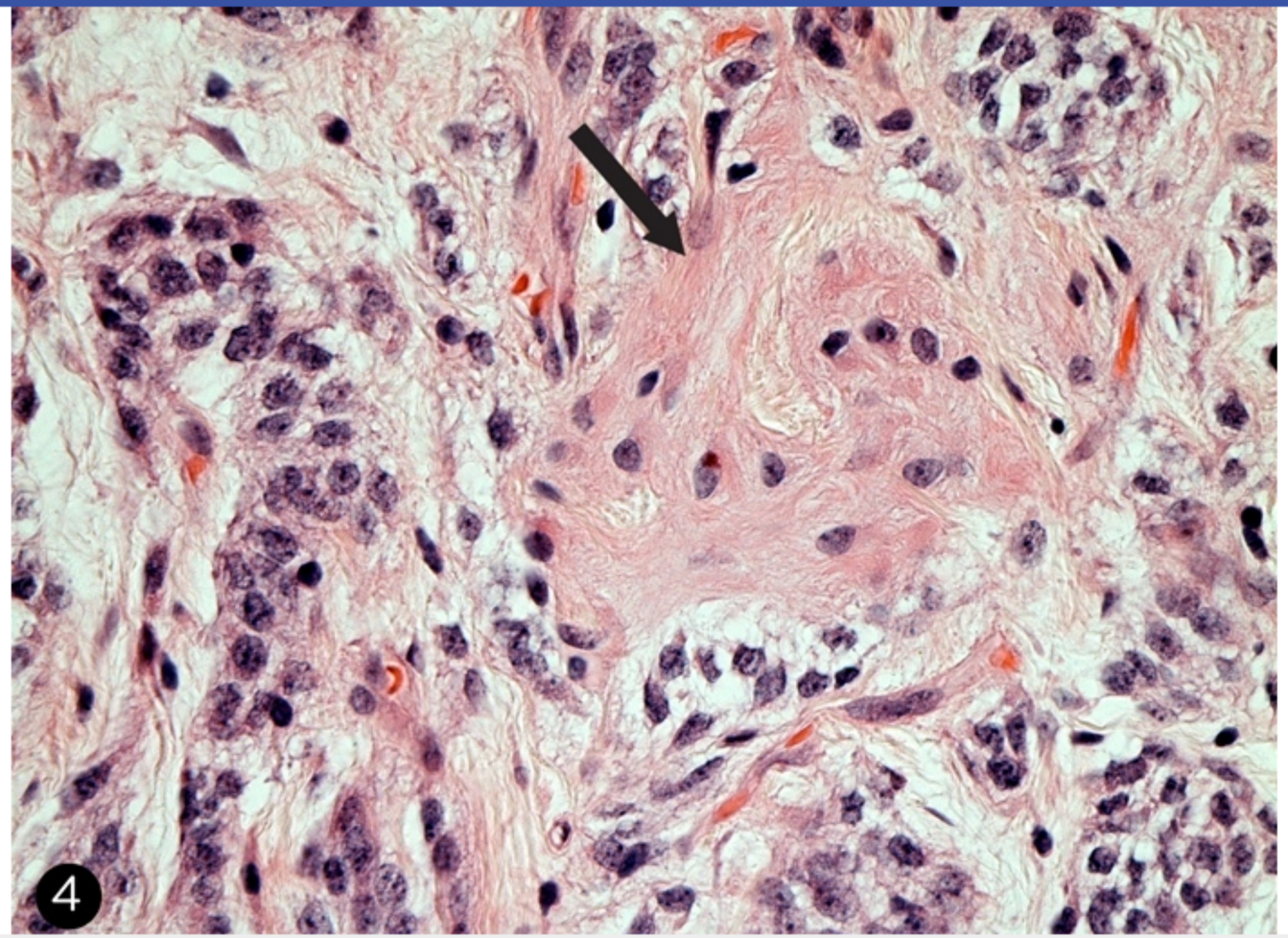

Zoom In
Zoom Out
Reset
Add To New Card | Existing Card

1
2
3
4
5
6
7
8
9
10
11
12
13
14
15
16
17
18
19
20
21
22
23
24
25
26
27
28
29
30

Exhibit Display

Ependymoma Ependymoma

Ependymoma

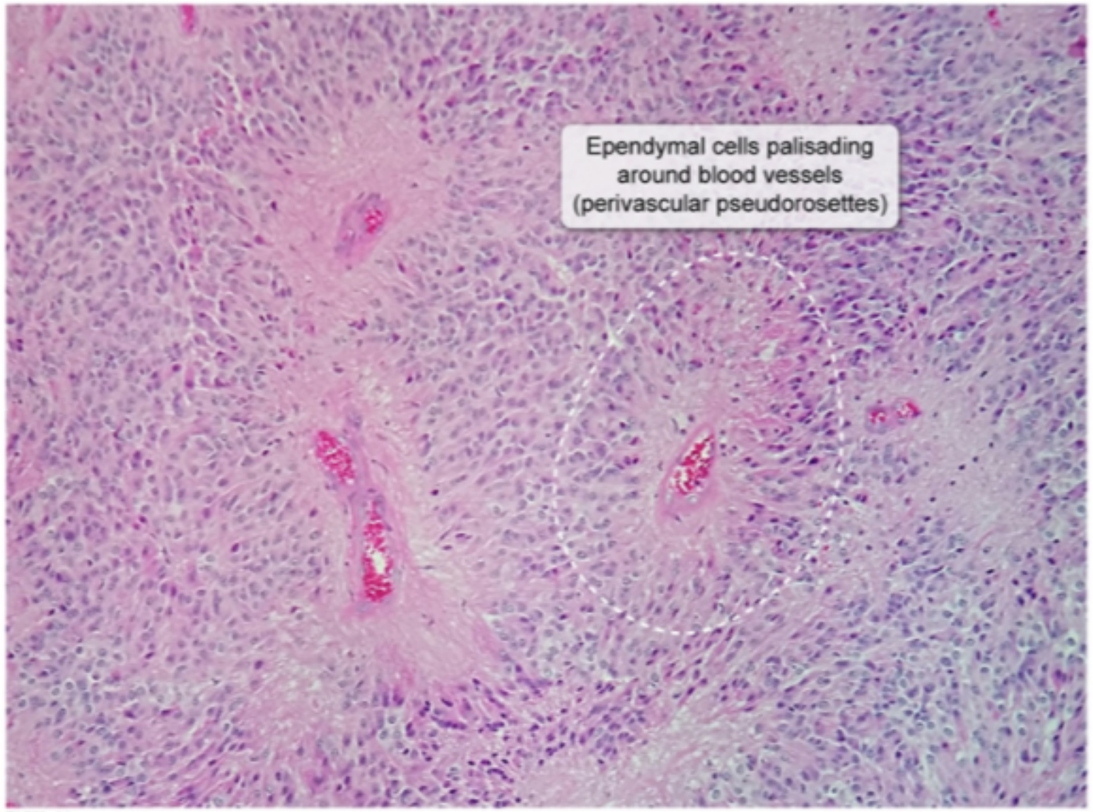

Zoom In | Zoom Out | Reset | Add To New Card | Existing Card

1
2
3
4
5
6
7
8
9
10
11
12
13
14
15
16
17
18
19
20
21
22
23
24
25
26
27
28
29
30

Exhibit Display

Ependymoma Ependymoma

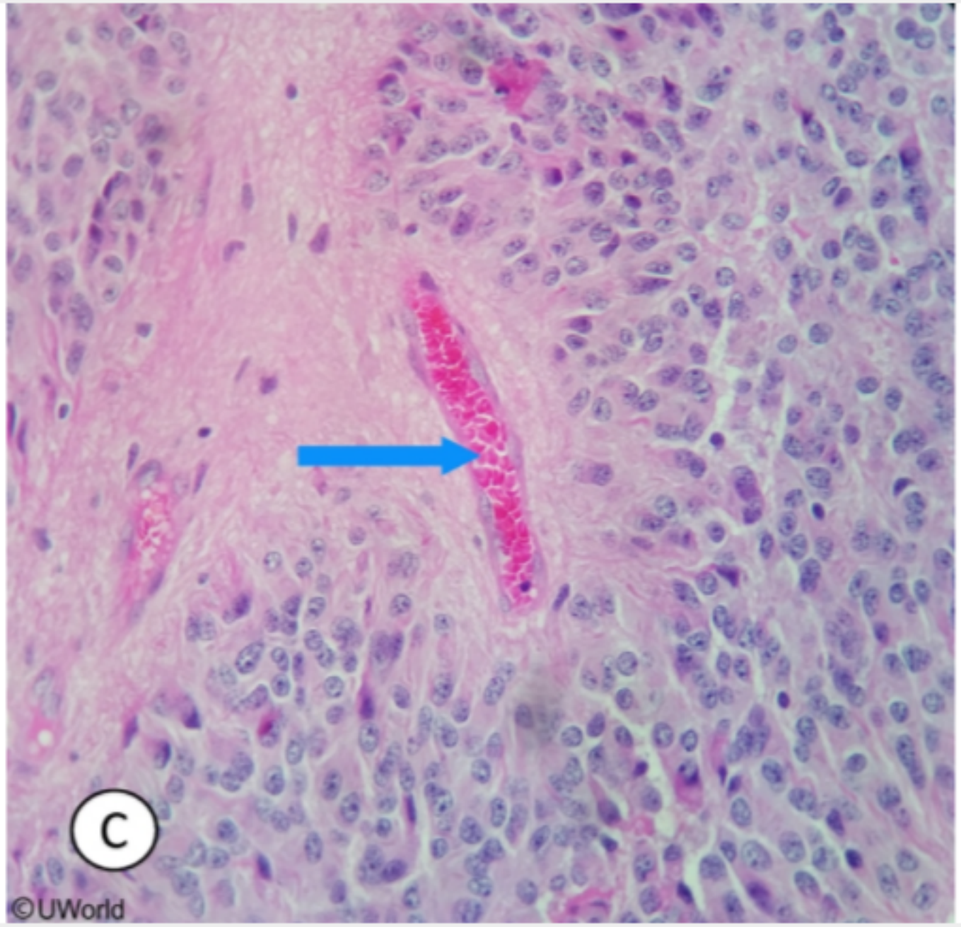

Zoom In Zoom Out Reset Add To New Card | Existing Card

with a heterogeneous, well-circumscribed cerebellar mass most likely has a **pilocytic astrocytoma**, the most common type of brain tumor in

Exhibit Display

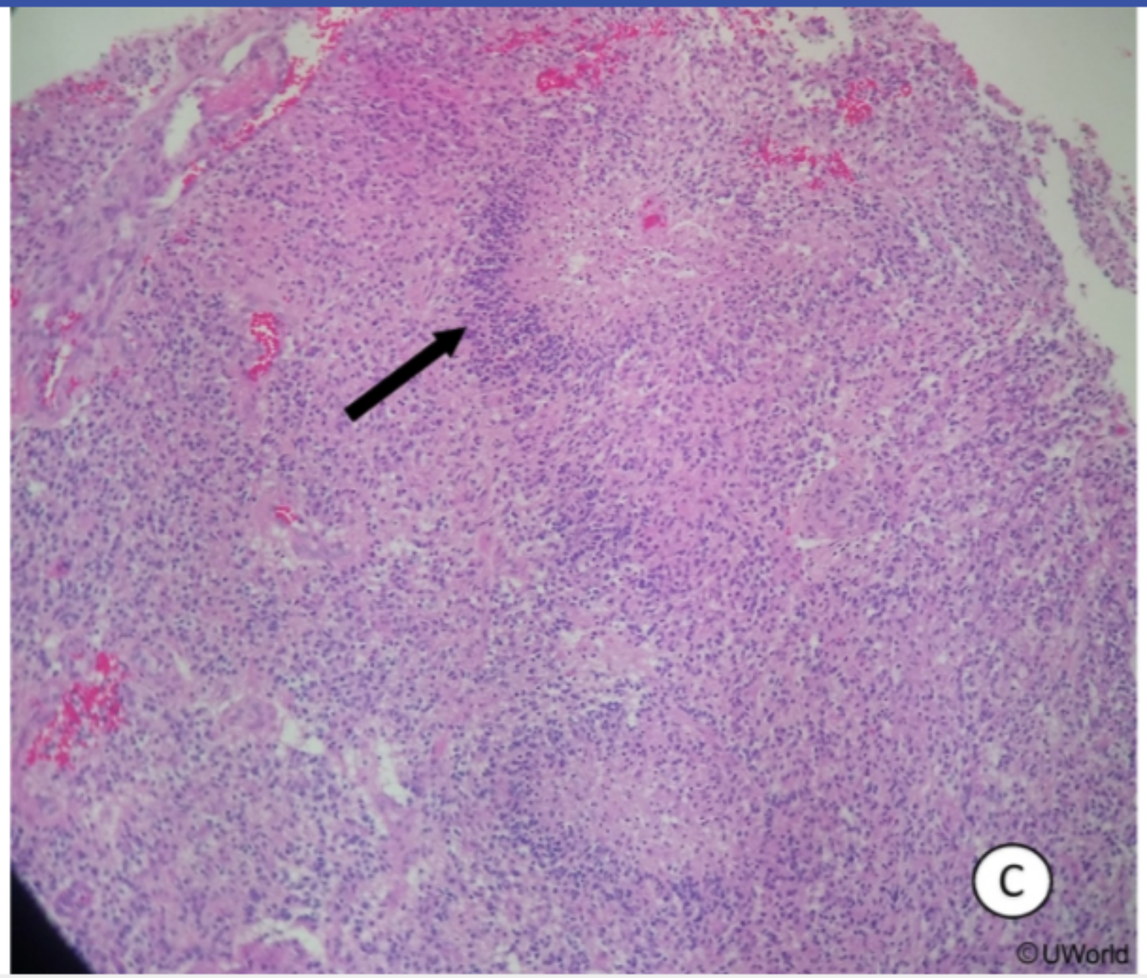

Zoom In | Zoom Out | Reset | Add To New Card | Existing Card

- Pediatric cerebellar astrocytoma: a review.

with a heterogeneous, well-circumscribed cerebellar mass most likely has a **pilocytic astrocytoma**, the most common type of brain tumor in

Exhibit Display

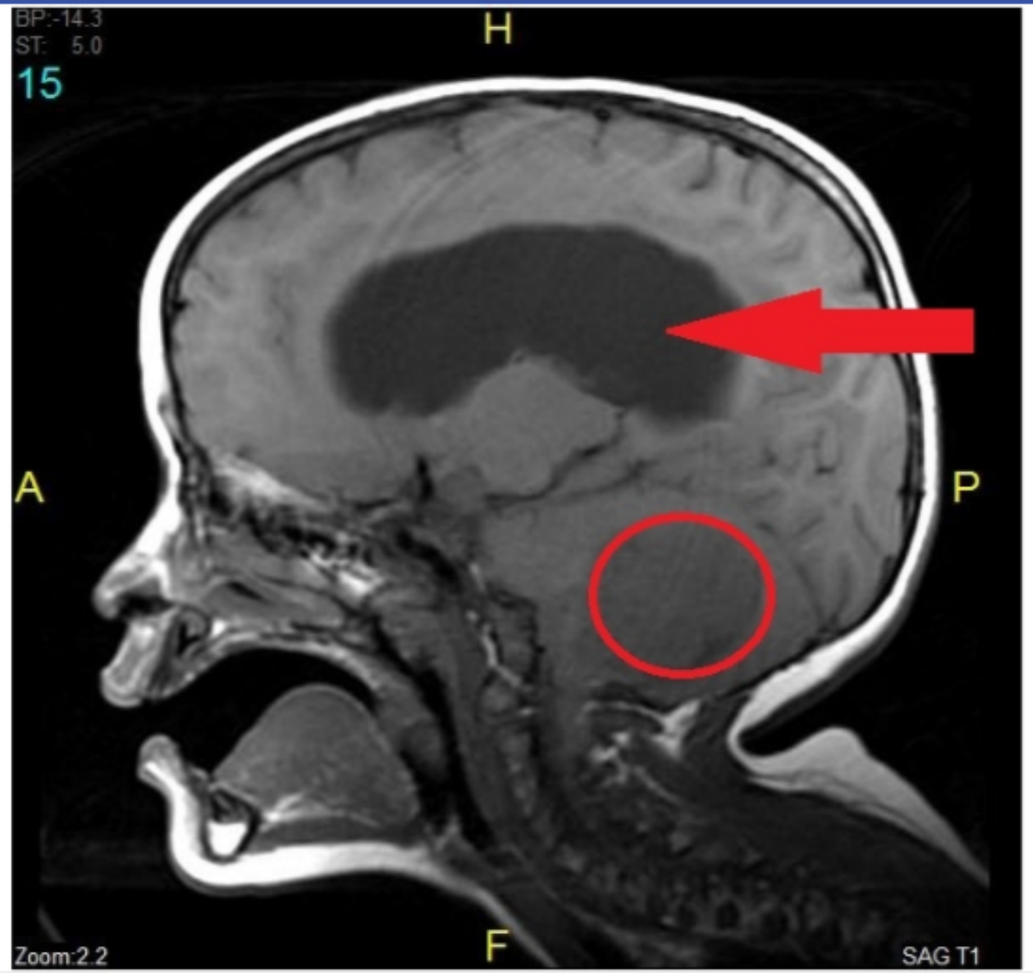

Zoom In | Zoom Out | Reset | Add To New Card | Existing Card

- Pediatric cerebellar astrocytoma: a review.

with a heterogeneous, well-circumscribed cerebellar mass most likely has a **pilocytic astrocytoma**, the most common type of brain tumor in

Exhibit Display

Zoom In | Zoom Out | Reset | Add To New Card | Existing Card

- Pediatric cerebellar astrocytoma: a review.

with a heterogeneous, well-circumscribed cerebellar mass most likely has a **pilocytic astrocytoma**, the most common type of brain tumor in

Exhibit Display

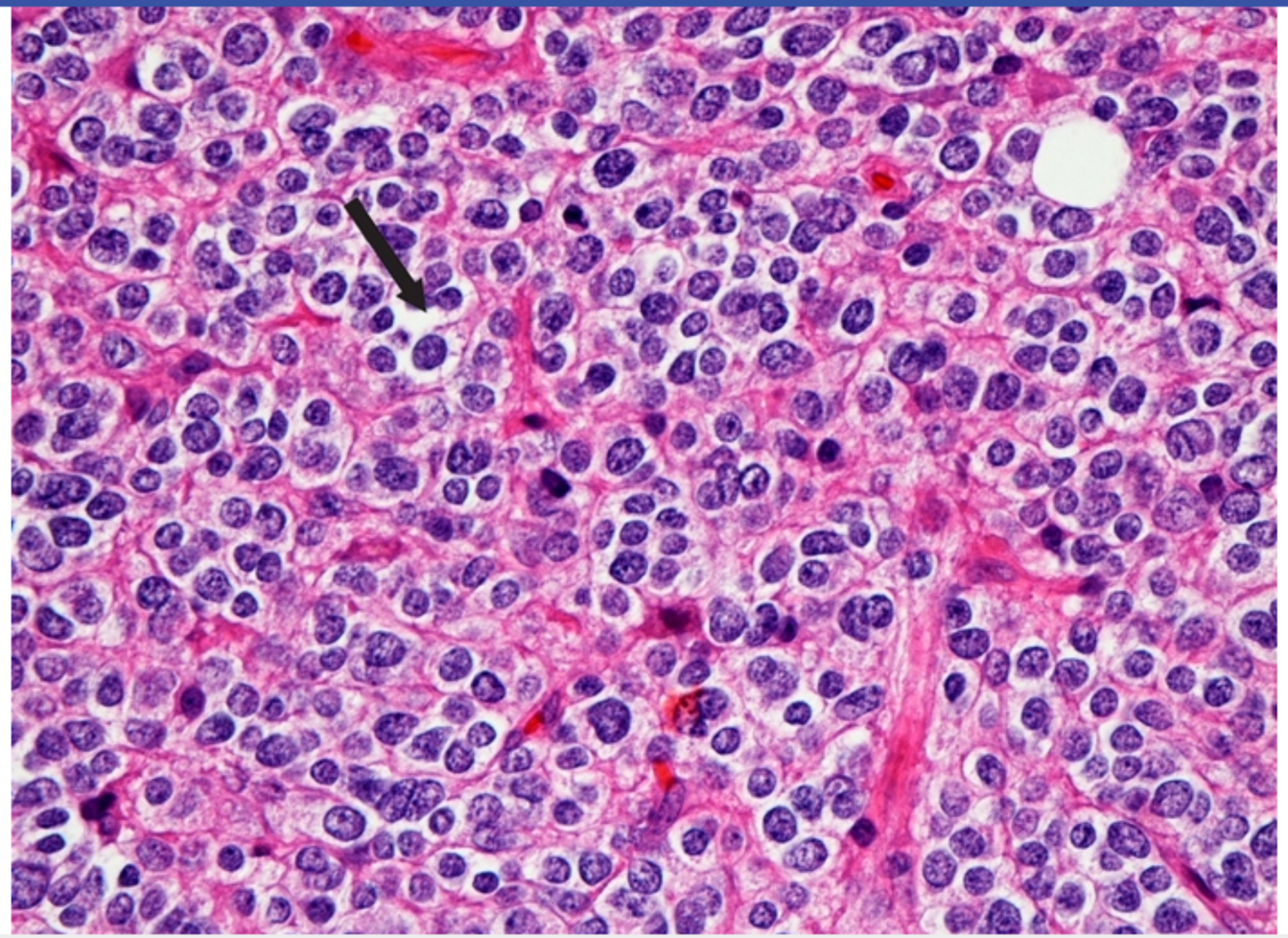

Zoom In | Zoom Out | Reset | Add To New Card | Existing Card

- Pediatric cerebellar astrocytoma: a review.

A 65-year-old man comes to the office due to 2 months of fatigue and persistent, nonproductive cough. He has a history of coronary artery disease and myocardial infarction. Three years ago, he underwent wide local excision of a melanoma on his posterior neck. The patient has a 50-pack-year smoking history. Vital signs are within normal limits. Chest radiograph reveals multiple lung lesions and hilar lymphadenopathy. Histopathology from one of the biopsied lung lesions is shown below after staining with hematoxylin and eosin.

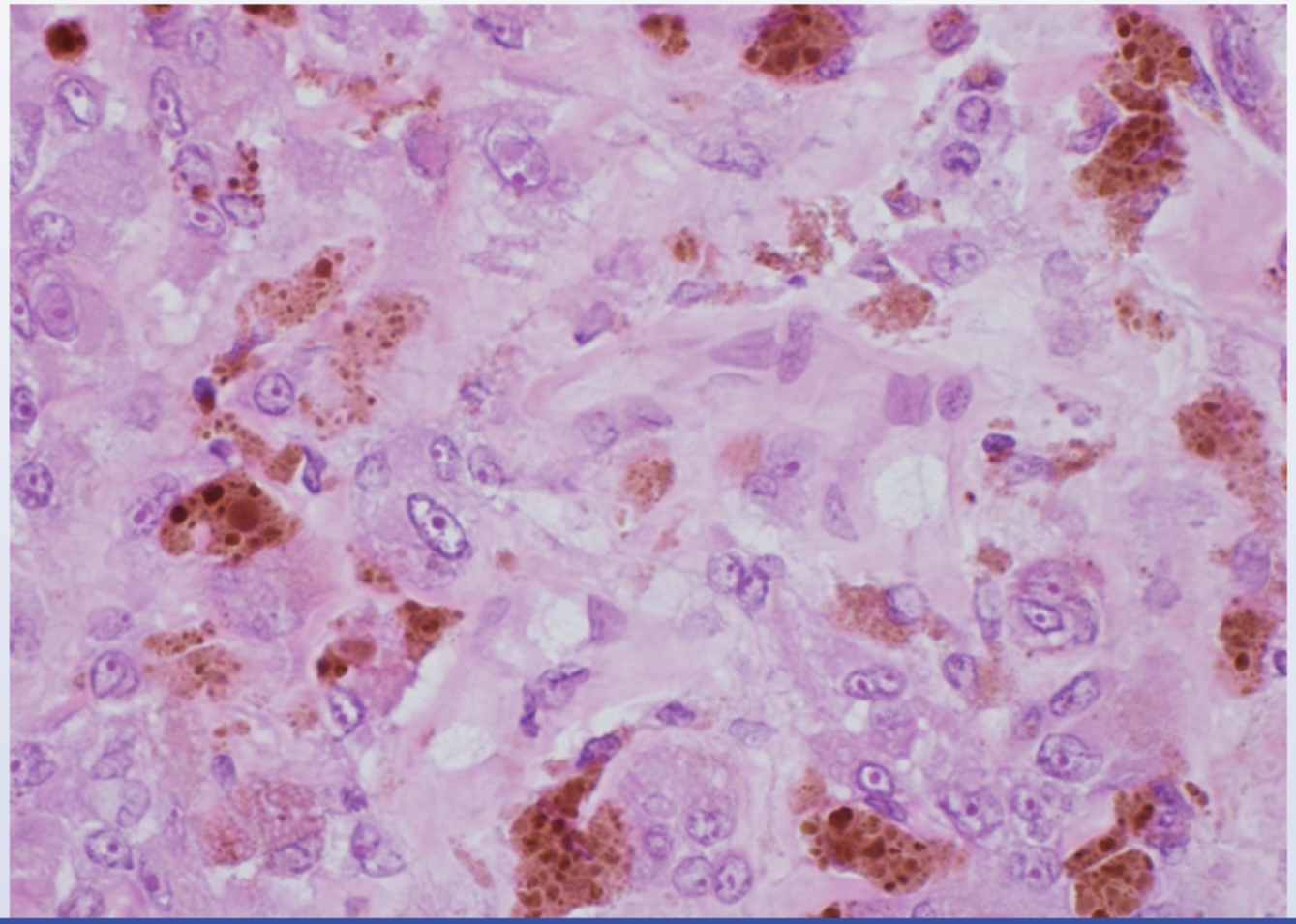

1
2
3
4
5
6
7
8
9
10
11
12
13
14
15
16
17
18
19
20
21
22
23
24
25
26
27
28
29
30

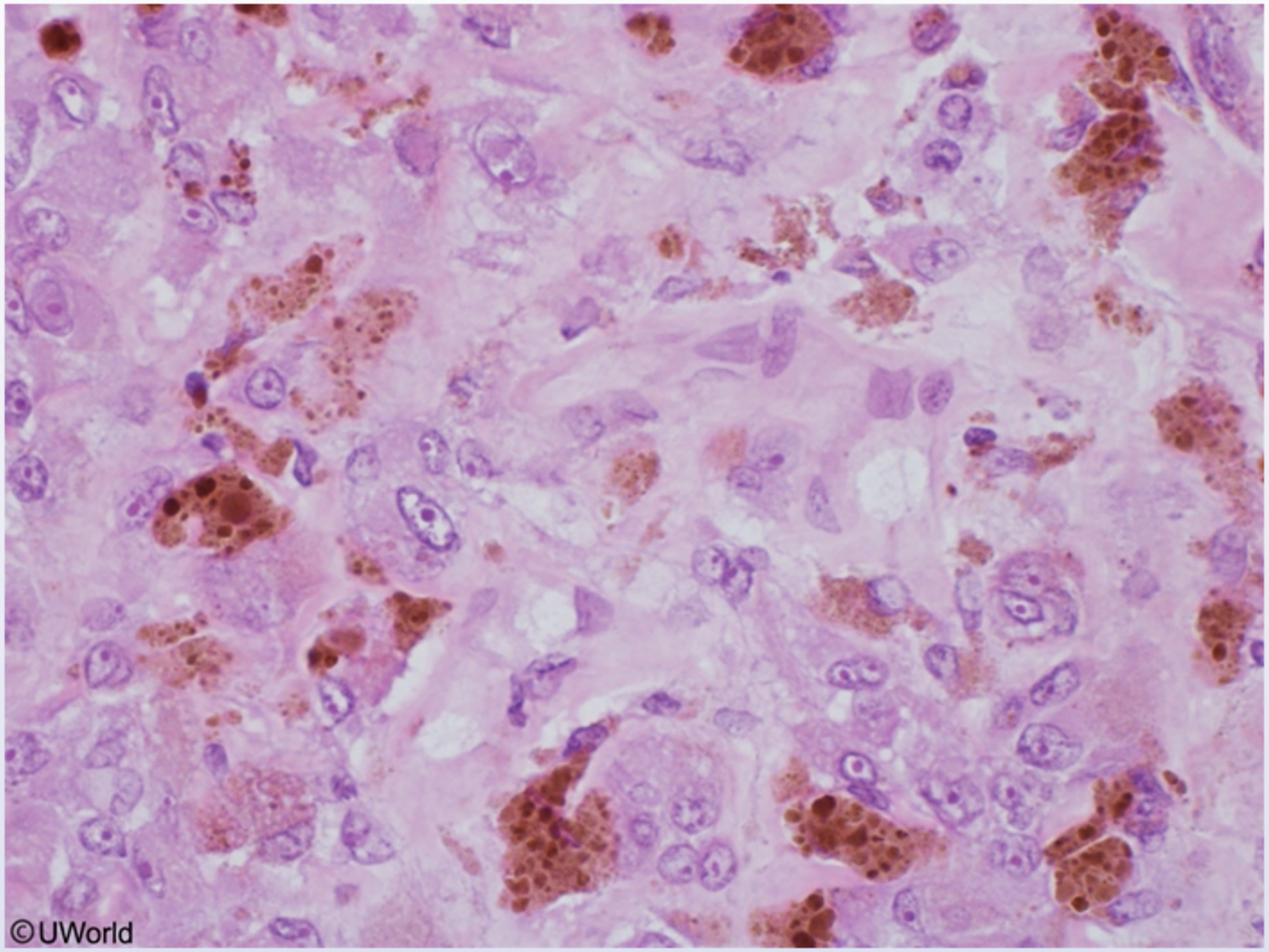

These histopathologic findings are most consistent with which of the following diagnoses?

A. Chronic systolic heart failure

B. Emphysema

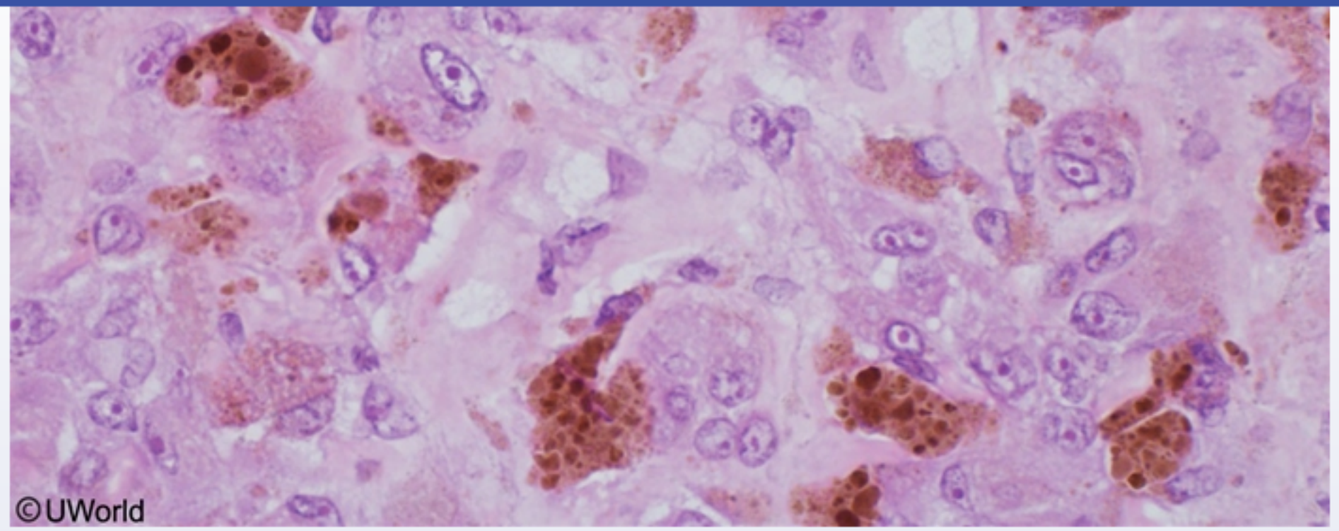

These histopathologic findings are most consistent with which of the following diagnoses?

- A. Chronic systolic heart failure
- B. Emphysema
- C. Hodgkin lymphoma
- D. Metastatic melanoma
- E. Sarcoidosis
- F. Squamous cell lung cancer

Submit

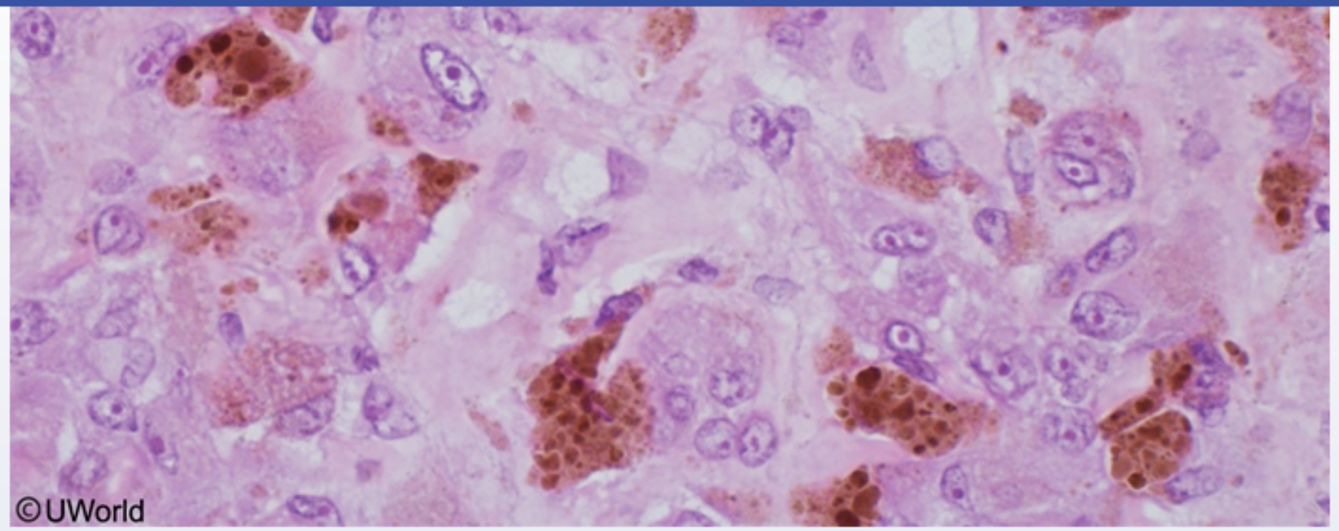

These histopathologic findings are most consistent with which of the following diagnoses?

- A. Chronic systolic heart failure (30%)
- B. Emphysema (1%)
- C. Hodgkin lymphoma (10%)
- ✓ D. Metastatic melanoma (42%)
- E. Sarcoidosis (7%)
- F. Squamous cell lung cancer (6%)

Omitted
Correct answer

42%
Answered correctly

06 secs
Time Spent

03/18/2020
Last Updated

1
2
3
4
5
6
7
8
9
10
11
12
13
14
15
16
17
18
19
20
21
22
23
24
25
26
27
28
29
30

Metastatic melanoma

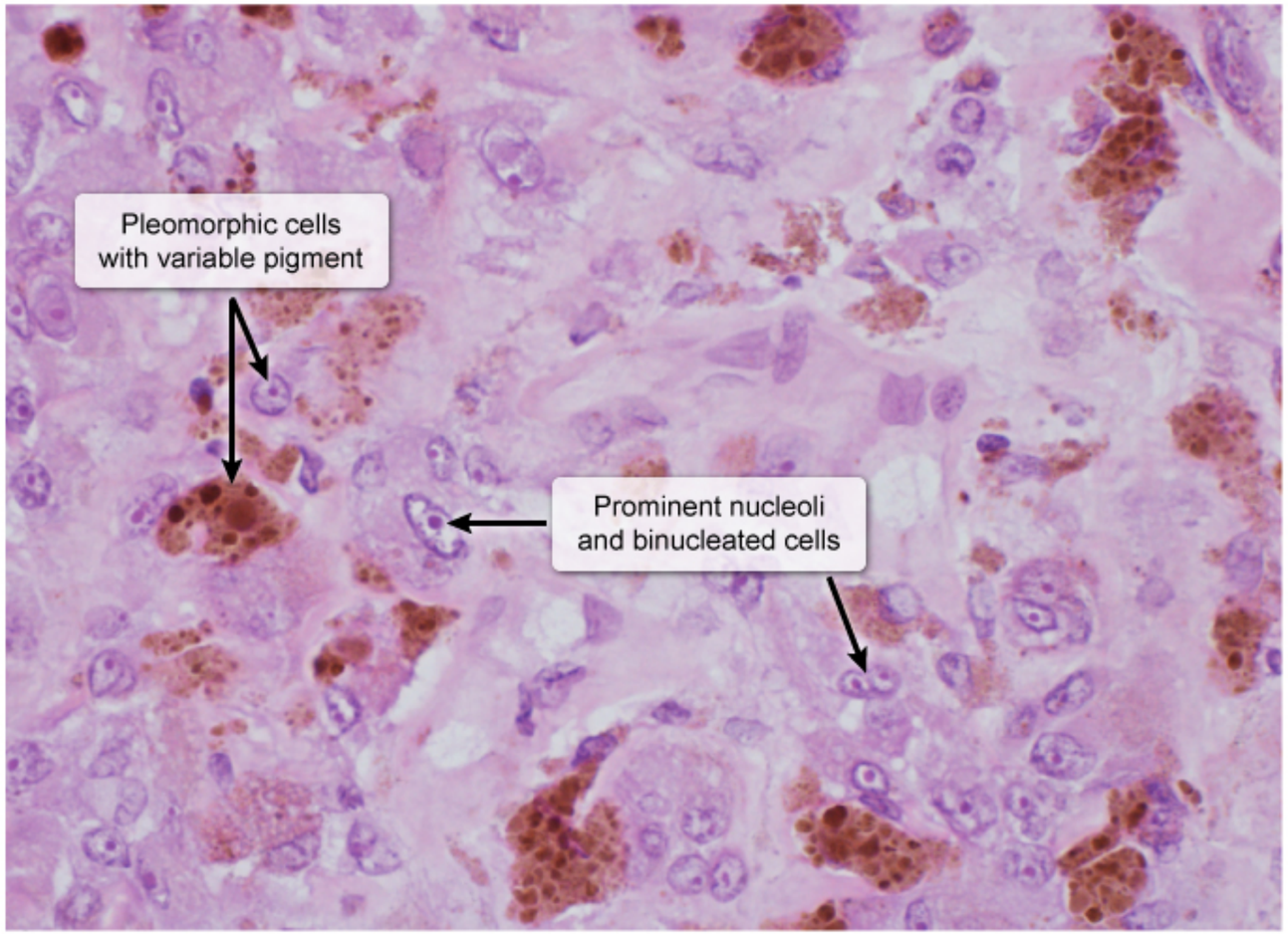

©UWorld

Histopathology from this patient's lung lesion reveals features concerning for **malignancy**, including disordered, pleomorphic cells; large, hyperchromatic nuclei; irregular nuclear shape (eg, binucleated cells); and prominent nucleoli. Although he is at risk for primary lung cancer due

Histopathology from this patient's lung lesion reveals features concerning for **malignancy**, including disordered, pleomorphic cells, large, hyperchromatic nuclei; irregular nuclear shape (eg, binucleated cells); and prominent nucleoli. Although he is at risk for primary lung cancer due to a long smoking history, the presence of **brown pigment** (melanin granules) in the cytoplasm of some of the atypical cells indicates likely **melanoma recurrence**.

Surgical resection of cutaneous melanoma is sometimes curative, but the tumor often spreads through the lymphatics and bloodstream to other organs early in the disease course; these metastasis can remain asymptomatic for months to years. Recurrence is generally diagnosed when a suspicious lesion is identified and biopsy reveals malignant melanocytes (eg, cytoplasmic melanin, cellular atypia) with positive immunostaining for melanin/melanoma markers (eg, **S-100**, **HMB-45**).

(Choice A) Chronic systolic heart failure can sometimes be associated with cough and fatigue due to pulmonary congestion. Although brown, hemosiderin-laden macrophages can be seen, atypical cells (eg, binuclear, enlarged nuclei) and hilar lymphadenopathy would not be present.

(Choice B) This patient is at risk for emphysema due to his long smoking history. Although emphysema often causes dyspnea and cough, biopsy would show airspace enlargement and destruction of alveolar walls.

(Choice C) Hodgkin lymphoma frequently presents with diffuse lymphadenopathy or pulmonary symptoms (eg, cough) related to a mediastinal mass. However, biopsy would show malignant Reed-Sternberg cells amidst an inflammatory infiltrate (not cells with dark pigment).

(Choice E) Sarcoidosis frequently causes pulmonary symptoms and fatigue and often presents with hilar lymphadenopathy and reticular pulmonary infiltrates. However, biopsy would show noncaseating granulomas, not pigmented, atypical cells.

(Choice F) Squamous cell lung cancer frequently presents with cough and fatigue. Although atypical cells would be seen on biopsy, keratin (not brown pigment) would be present.

Educational objective:
Melanoma is a highly aggressive malignancy that often metastasizes early in the disease course. Patients may be asymptomatic for years prior to onset of metastatic manifestations. Diagnosis is generally made when a histopathologic sample shows cellular atypia with cells containing brown pigment (melanin granules); immunostaining for melanin/melanoma markers (eg, S-100, HMB-45) is generally positive.

References

- Decoding melanoma metastasis.

Histopathology from this patient's lung lesion reveals features concerning for **malignancy**, including disordered, pleomorphic cells, large, hyperchromatic nuclei; irregular nuclear shape (eg, binucleated cells); and prominent nucleoli. Although he is at risk for primary lung cancer due

Exhibit Display

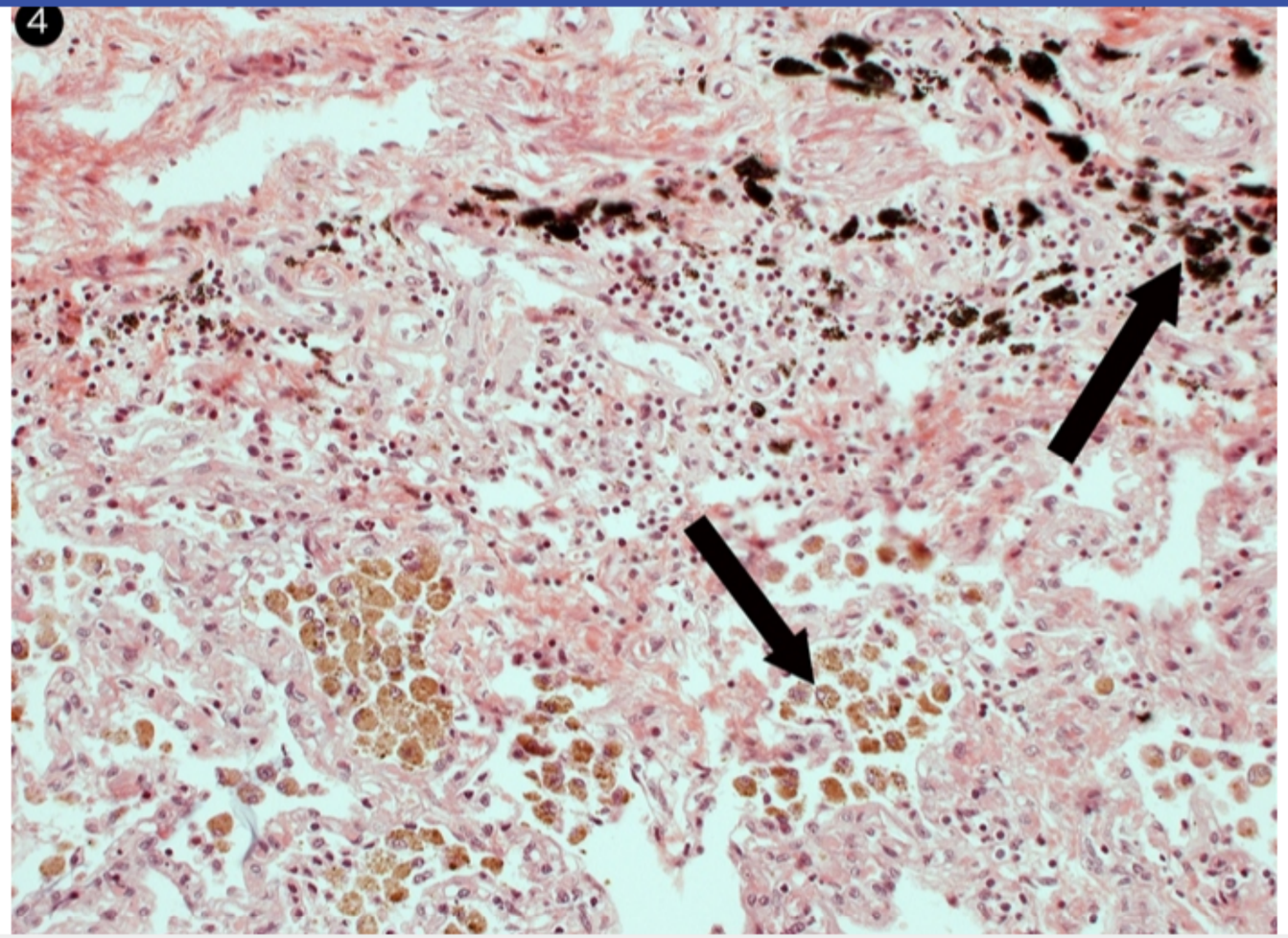

Zoom In | Zoom Out | Reset | Add To New Card | Existing Card

- Decoding melanoma metastasis.

1
2
3
4
5
6
7
8
9
10
11
12
13
14
15
16
17
18
19
20
21
22
23
24
25
26
27
28
29
30

Histopathology from this patient's lung lesion reveals features concerning for **malignancy**, including disordered, pleomorphic cells, large, hyperchromatic nuclei; irregular nuclear shape (eg, binucleated cells); and prominent nucleoli. Although he is at risk for primary lung cancer due to a long smoking history, the presence of **brown pigment** (melanin granules) in th **melanoma recurrence**.

Surgical resection of cutaneous melanoma is sometimes curative, but the tumor of organs early in the disease course; these metastasis can remain asymptomatic for suspicious lesion is identified and biopsy reveals malignant melanocytes (eg, cytop melanin/melanoma markers (eg, **S-100**, **HMB-45**).

(Choice A) Chronic systolic heart failure can sometimes be associated with cough hemosiderin-laden macrophages can be seen, atypical cells (eg, binuclear, enlarge

(Choice B) This patient is at risk for emphysema due to his long smoking history. would show airspace enlargement and destruction of alveolar walls.

(Choice C) Hodgkin lymphoma frequently presents with diffuse lymphadenopathy mass. However, biopsy would show malignant Reed-Sternberg cells amidst an infl

(Choice E) Sarcoidosis frequently causes pulmonary symptoms and fatigue and c pulmonary infiltrates. However, biopsy would show noncaseating granulomas, not

(Choice F) Squamous cell lung cancer frequently presents with cough and fatigue brown pigment) would be present.

Educational objective:
Melanoma is a highly aggressive malignancy that often metastasizes early in the d onset of metastatic manifestations. Diagnosis is generally made when a histopath pigment (melanin granules); immunostaining for melanin/melanoma markers (eg, S

References

- Decoding melanoma metastasis.

Exhibit Display

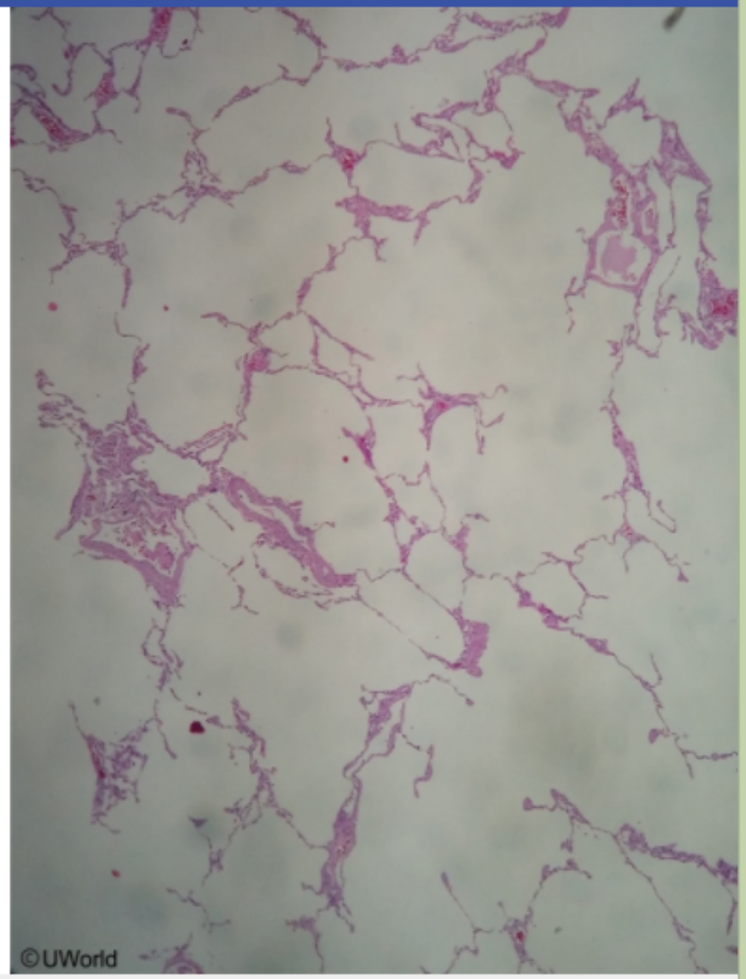

Zoom In
Zoom Out
Reset
Add To New

1
2
3
4
5
6
7
8
9
10
11
12
13
14
15
16
17
18
19
20
21
22
23
24
25
26
27
28
29
30

Histopathology from this patient's lung lesion reveals features concerning for **malignancy**, including disordered, pleomorphic cells, large, hyperchromatic nuclei; irregular nuclear shape (eg, binucleated cells); and prominent nucleoli. Although he is at risk for primary lung cancer due to a long smoking history, the presence of **brown pigment** (melanin granules) in the cytoplasm of some of the atypical cells indicates likely **melanoma recurre**

Surgical resection c
organs early in the
suspicious lesion is
melanin/melanoma

(Choice A) Chroni
hemosiderin-laden

(Choice B) This pa
would show airspac

(Choice C) Hodgki
mass. However, bi

(Choice E) Sarcoi
pulmonary infiltrate

(Choice F) Squam
brown pigment) wo

Educational objec
Melanoma is a high
onset of metastatic
pigment (melanin g

References

- Decoding melar

Exhibit Display

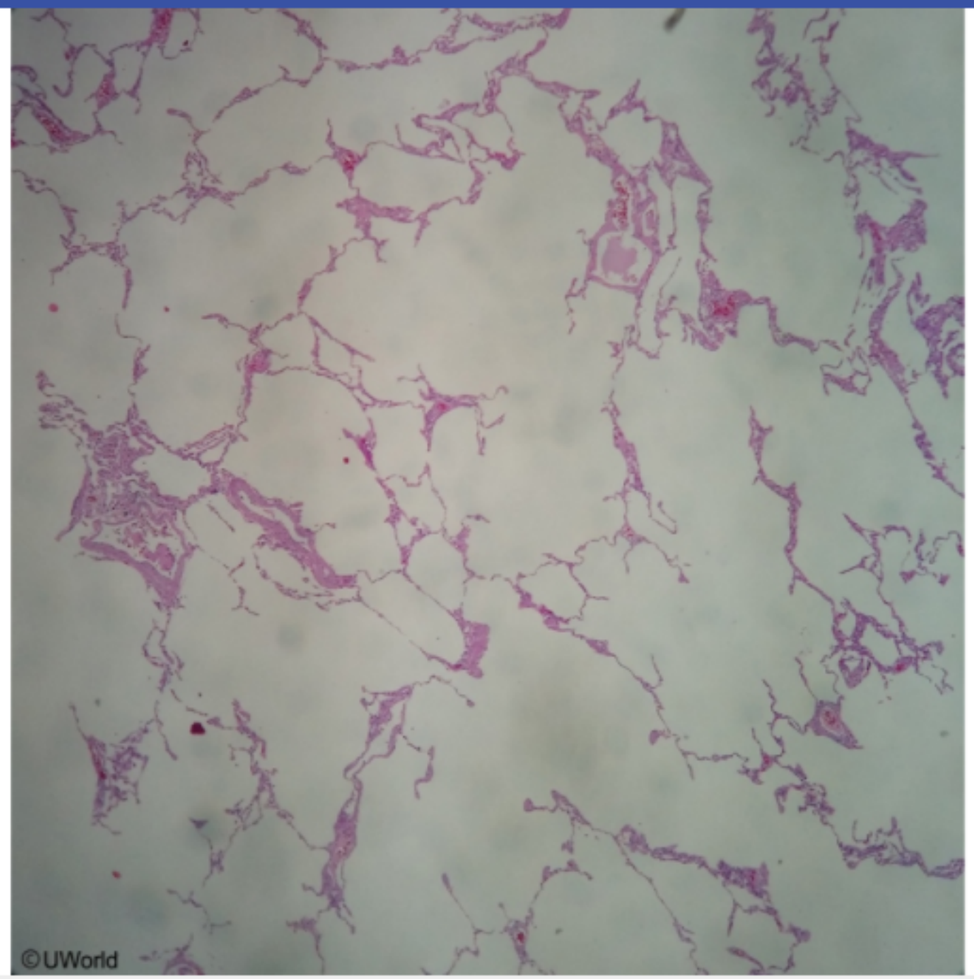

Zoom In | Zoom Out | Reset | Add To New Card | Existing Card

Histopathology from this patient's lung lesion reveals features concerning for **malignancy**, including disordered, pleomorphic cells; large, hyperchromatic nuclei; irregular nuclear shape (eg, binucleated cells); and prominent nucleoli. Although he is at risk for primary lung cancer due

Exhibit Display

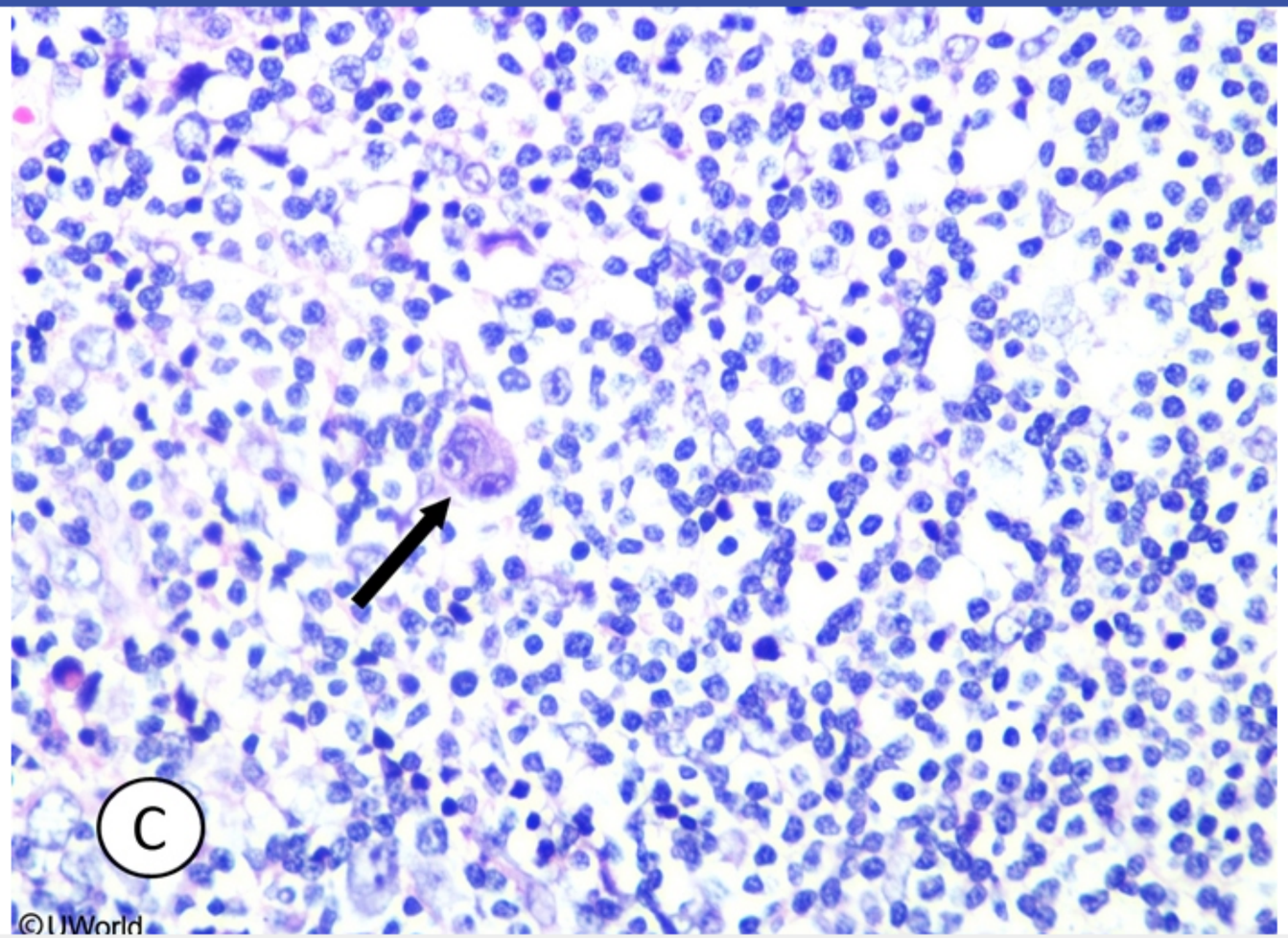

Zoom In | Zoom Out | Reset | Add To New Card | Existing Card

- Decoding melanoma metastasis.

Histopathology from this patient's lung lesion reveals features concerning for **malignancy**, including disordered, pleomorphic cells, large, hyperchromatic nuclei; irregular nuclear shape (eg, binucleated cells); and prominent nucleoli. Although he is at risk for primary lung cancer due

Exhibit Display

Sarcoid lymphadenopathy

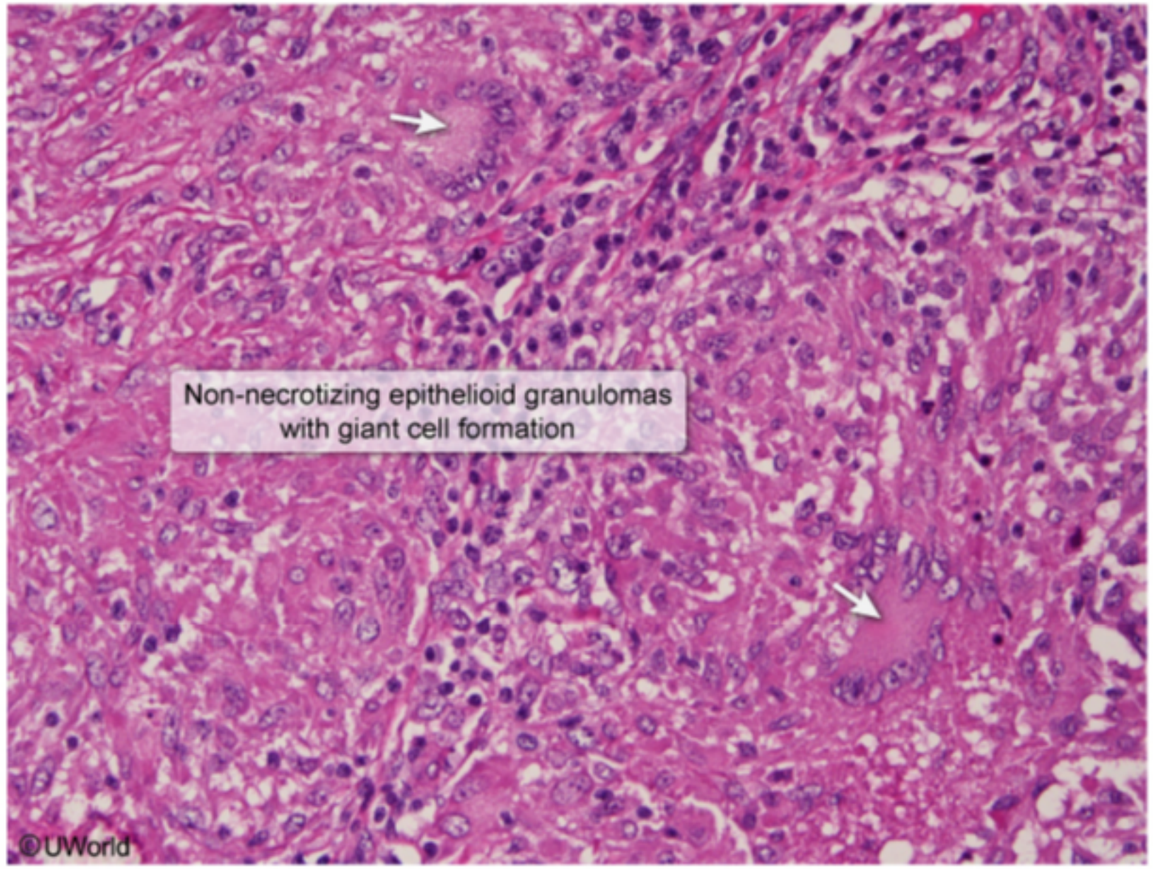

Zoom In | Zoom Out | Reset | Add To New Card | Existing Card

- Decoding melanoma metastasis.

A 44-year-old man who was recently diagnosed with idiopathic membranous nephropathy after developing edema comes to the office due to a sudden onset of left flank pain and gross hematuria. The patient has no other medical problems. He is taking furosemide and ramipril. Blood pressure is 135/85 mm Hg and pulse is 88/min. On examination, there is left flank tenderness. The patient's edema has improved from the previous visit. There is a left-sided varicocele that the patient has not noticed before. Urinalysis shows increased proteinuria and new hematuria. Serum lactate dehydrogenase is elevated. Urinary loss of which of the following substances most likely predisposed this patient to his acute condition?

A. Albumin
B. Alpha-1 antitrypsin
C. Antithrombin III
D. Ceruloplasmin
E. Immunoglobulins
F. Lipoproteins

Submit

1
2
3
4
5
6
7
8
9
10
11
12
13
14
15
16
17
18
19
20
21
22
23
24
25
26
27
28
29
30

A 44-year-old man who was recently diagnosed with idiopathic membranous nephropathy after developing edema comes to the office due to a sudden onset of left flank pain and gross hematuria. The patient has no other medical problems. He is taking furosemide and ramipril. Blood pressure is 135/85 mm Hg and pulse is 88/min. On examination, there is left flank tenderness. The patient's edema has improved from the previous visit. There is a left-sided varicocele that the patient has not noticed before. Urinalysis shows increased proteinuria and new hematuria. Serum lactate dehydrogenase is elevated. Urinary loss of which of the following substances most likely predisposed this patient to his acute condition?

- A. Albumin (32%)
- B. Alpha-1 antitrypsin (1%)
- ✓ C. Antithrombin III (49%)
- D. Ceruloplasmin (2%)
- E. Immunoglobulins (10%)
- F. Lipoproteins (3%)

Omitted
Correct answer
C

49%
Answered correctly

02 secs
Time Spent

03/13/2020
Last Updated

Explanation

This patient with membranous nephropathy, flank pain, hematuria, and left varicocele likely has **renal vein thrombosis** (RVT) as a result of **nephrotic syndrome**. Due to increased glomerular capillary wall permeability in nephrotic syndrome, many important substances are lost in the

This patient with membranous nephropathy, flank pain, hematuria, and left varicocele likely has **renal vein thrombosis** (RVT) as a result of **nephrotic syndrome**. Due to increased glomerular capillary wall permeability in nephrotic syndrome, many important substances are lost in the urine, causing a number of complications. Loss of anticoagulant factors, especially **antithrombin III**, leads to a hypercoagulable state, of which RVT can be a manifestation. Patients with RVT can develop sudden-onset abdominal or **flank pain** and gross **hematuria** with **elevated lactate dehydrogenase** as a result of renal infarction.

Left-sided varicoceles are relatively common in healthy pubertal men as the aorta and superior mesenteric artery can compress the left renal vein ("nutcracker effect"), resulting in increased intravascular pressure in the left gonadal vein with retrograde blood flow and varicocele formation. However, a new-onset left varicocele associated with ipsilateral flank pain and hematuria should raise suspicion for RVT causing impaired left gonadal venous drainage.

(Choice A) Albumin is also lost in massive quantities in urine in nephrotic syndrome, leading to hypoproteinemia, decreased intravascular oncotic pressure, and fluid shifts into the interstitium. Albuminuria explains the patient's edema (improved from his previous visit) but not his acute flank pain, hematuria, and left-sided varicocele, which are more likely due to thrombosis. Protein loss also results in a negative nitrogen balance.

(Choice B) Alpha-1 antitrypsin deficiency is an inherited condition that results in early emphysema and liver cirrhosis.

(Choice D) Serum ceruloplasmin is decreased in Wilson disease (hepatolenticular degeneration), which is clinically characterized by liver disease, motor abnormalities, and psychiatric symptoms. Ceruloplasmin has no role in the pathogenesis of nephrotic syndrome.

(Choice E) The loss of immunoglobulins and low-molecular-weight components of complement (such as factor B) makes patients with nephrotic syndrome vulnerable to infections, especially pneumococcal infections.

(Choice F) Lipiduria is common in nephrotic syndrome as a result of increased lipoprotein synthesis by the liver and increased glomerular capillary wall permeability, leading to lipid loss in the urine in the form of free fat and oval fat bodies (with characteristic Maltese cross appearance under polarized light). However, lipiduria does not contribute to the hypercoagulable state.

Educational objective:
Nephrotic syndrome is a hypercoagulable state. Sudden-onset abdominal or flank pain, hematuria, and left-sided varicoceles suggest renal vein thrombosis, a well-known complication of nephrotic syndrome. Loss of anticoagulant factors, especially antithrombin III, is responsible for the thrombotic and thromboembolic complications of nephrotic syndrome.

1
2
3
4
5
6
7
8
9
10
11
12
13
14
15
16
17
18
19
20
21
22
23
24
25
26
27
28
29
30

Exhibit Display

Varicocele pathophysiology

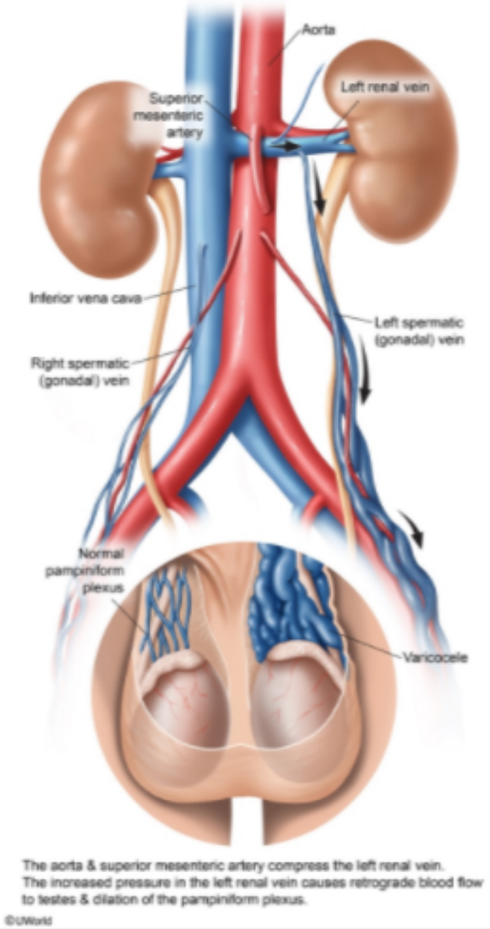

The aorta & superior mesenteric artery compress the left renal vein. The increased pressure in the left renal vein causes retrograde blood flow to testes & dilation of the pampiniform plexus.

©UWorld

Zoom In | Zoom Out | Reset | Add To New Card | Existing Card

thrombotic and thromboembolic complications of nephrotic syndrome

("nutcracker effect"), resulting in increased intravascular pressure in the left gonadal vein with retrograde blood flow and varicocele formation. However, a new-onset left varicocele associated with ipsilateral flank pain and hematuria should raise suspicion for RVT causing impaired left gonadal venous drainage.

(Choice A) Albumin is also lost in massive quantities in urine in nephrotic syndrome, leading to hypoproteinemia, decreased intravascular oncotic pressure, and fluid shifts into the interstitium. Albuminuria explains the patient's edema (improved from his previous visit) but not his acute flank pain, hematuria, and left-sided varicocele, which are more likely due to thrombosis. Protein loss also results in a negative nitrogen balance.

(Choice B) Alpha-1 antitrypsin deficiency is an inherited condition that results in early emphysema and liver cirrhosis.

(Choice D) Serum ceruloplasmin is decreased in Wilson disease (hepatolenticular degeneration), which is clinically characterized by liver disease, motor abnormalities, and psychiatric symptoms. Ceruloplasmin has no role in the pathogenesis of nephrotic syndrome.

(Choice E) The loss of immunoglobulins and low-molecular-weight components of complement (such as factor B) makes patients with nephrotic syndrome vulnerable to infections, especially pneumococcal infections.

(Choice F) Lipiduria is common in nephrotic syndrome as a result of increased lipoprotein synthesis by the liver and increased glomerular capillary wall permeability, leading to lipid loss in the urine in the form of free fat and oval fat bodies (with characteristic Maltese cross appearance under polarized light). However, lipiduria does not contribute to the hypercoagulable state.

Educational objective:
Nephrotic syndrome is a hypercoagulable state. Sudden-onset abdominal or flank pain, hematuria, and left-sided varicoceles suggest renal vein thrombosis, a well-known complication of nephrotic syndrome. Loss of anticoagulant factors, especially antithrombin III, is responsible for the thrombotic and thromboembolic complications of nephrotic syndrome.

References

- Renal colic as the first symptom of acute renal vein thrombosis, resulting in the diagnosis of nephrotic syndrome.
- Unilateral renal vein thrombosis and nephrotic syndrome. Report of a case with protein selectivity and antithrombin III clearance studies.

Pathology Hematology & Oncology Renal vein thrombosis

1
2
3
4
5
6
7
8
9
10
11
12
13
14
15
16
17
18
19
20
21
22
23
24
25
26
27
28
29
30

A 25-year-old woman is brought to the emergency department after a motor vehicle collision. She has a pneumothorax, multiple rib fractures, and a right femur and tibial fracture. A chest tube is placed. The patient receives resuscitation and undergoes repair of the femur and tibial fractures. The following day, she develops respiratory distress, decreased urine output, and persistent bleeding from the chest tube drains and around the intravenous lines. Which of the following sets of laboratory findings is most likely to be seen in this patient?

	Fibrinogen	Protein C	Factor VII
A.	↓	↓	↓
B.	↓	↓	↑
C.	↓	↑	↑
D.	↓	↑	↓
E.	↑	↑	↑

Submit

1 2 3 4 5 6 7 8 9 10 11 12 13 14 15 16 17 18 19 20 21 22 23 24 25 26 27 28 29 30

A 25-year-old woman is brought to the emergency department after a motor vehicle collision. She has a pneumothorax, multiple rib fractures, and a right femur and tibial fracture. A chest tube is placed. The patient receives resuscitation and undergoes repair of the femur and tibial fractures. The following day, she develops respiratory distress, decreased urine output, and persistent bleeding from the chest tube drains and around the intravenous lines. Which of the following sets of laboratory findings is most likely to be seen in this patient?

	Fibrinogen	Protein C	Factor VII
✓ A. (60%)	↓	↓	↓
B. (6%)	↓	↓	↑
C. (4%)	↓	↑	↑
D. (24%)	↓	↑	↓
E. (3%)	↑	↑	↑

Omitted
Correct answer
A

60%
Answered correctly

01 sec
Time Spent

06/21/2020
Last Updated

Explanation

1
2
3
4
5
6
7
8
9
10
11
12
13
14
15
16
17
18
19
20
21
22
23
24
25
26
27
28
29
30

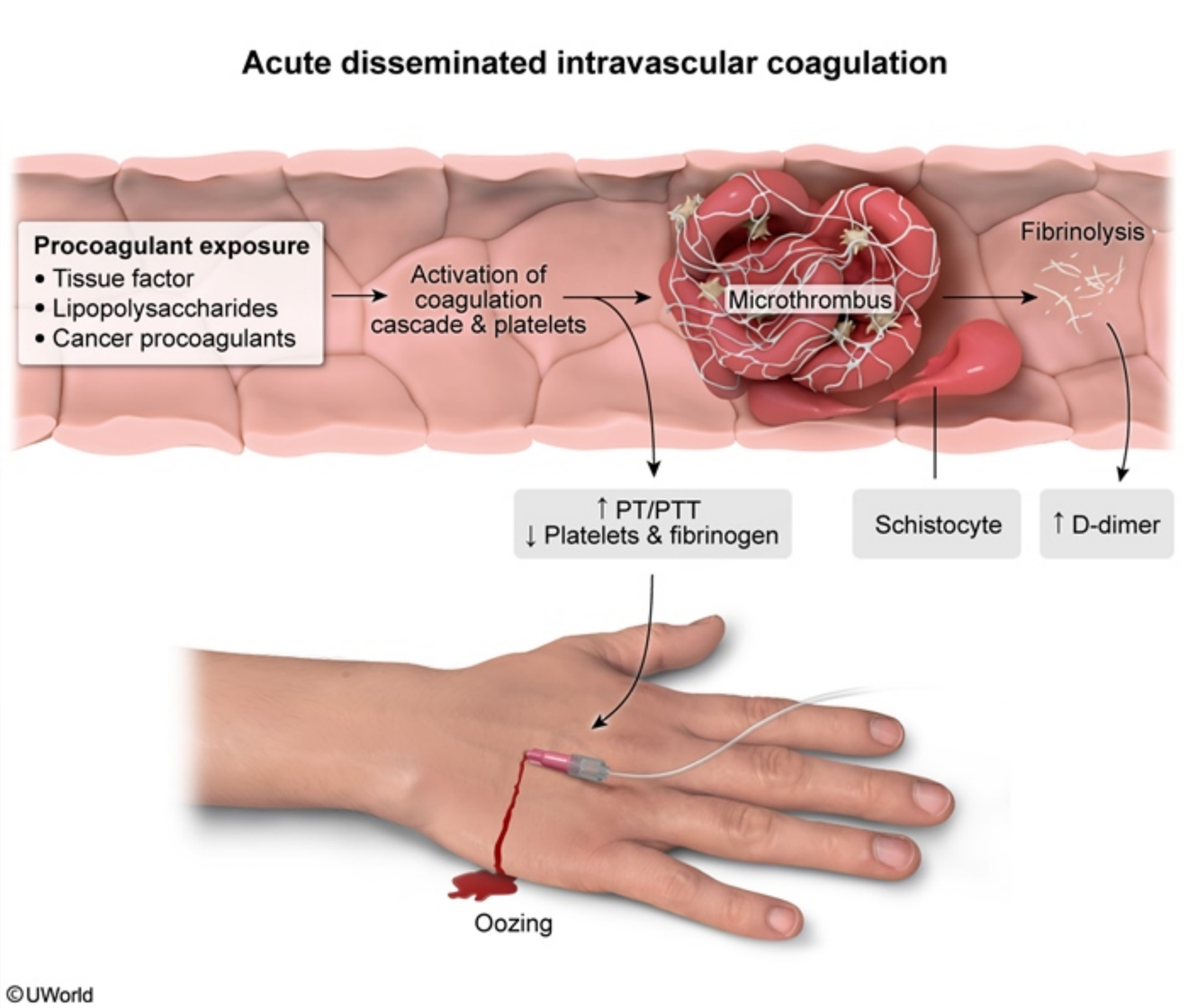

This patient with multiple injuries following a severe motor vehicle accident developed respiratory distress, reduced renal output, and oozing from

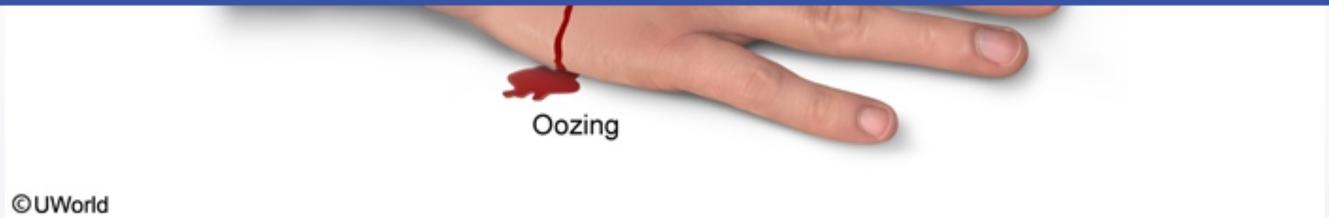

This patient with multiple injuries following a severe motor vehicle accident developed respiratory distress, reduced renal output, and oozing from the catheter and venipuncture sites. This presentation raises strong suspicion for **disseminated intravascular coagulation** (DIC), a consumptive coagulopathy associated with **trauma**, sepsis, malignancy, and obstetrical complications.

In DIC due to trauma, the coagulation cascade is triggered by damage to the vascular endothelium (exposes tissue factor) and tissues (releases procoagulant proteins and phospholipids). This leads to the generation of fibrin- and platelet-rich **microvascular thrombi**, which consumes platelets, coagulation factors (eg, **low factor VII**), and fibrinogen. Fibrinolysis and anticoagulant proteins then dissolve the clots, which **depletes protein C**, protein S, and antithrombin.

Most patients with acute DIC develop **bleeding complications** such as **oozing from catheters/venipuncture sites**, ecchymosis, and petechiae. End organ damage to the kidneys (eg, renal insufficiency) and lungs (eg, pulmonary hemorrhage) is common. Many patients also have microangiopathic hemolytic anemia (eg, schistocytes) due to shearing of red blood cells by intravascular thrombi.

Educational objective:
Acute disseminated intravascular coagulation is a consumptive coagulopathy linked to severe trauma. Widespread formation of microvascular thrombi leads to consumption of platelets, coagulation factors, and fibrinogen. Subsequent activation of anticoagulant proteins leads to low protein C/S; fibrinolysis elevates D-dimer. Most patients have bleeding complications (eg, oozing from venipuncture/catheter sites) and end organ damage to the lungs or kidneys.

Pathology	Hematology & Oncology	DIC
Subject	System	Topic

Copyright © UWorld. All rights reserved.

1
2
3
4
5
6
7
8
9
10
11
12
13
14
15
16
17
18
19
20
21
22
23
24
25
26
27
28
29
30

A 64-year-old man comes to the office due to 3 months of constant, dull, low back pain that is worse with movement. The patient has also had intermittent episodes of difficulty urinating over the last year. He has no other medical conditions and takes no medications. The patient smoked a pack of cigarettes daily for 15 years but quit 10 years ago. Vital signs are within normal limits. On physical examination, the lungs are clear and heart sounds are normal. The abdomen is soft and nontender with no hepatosplenomegaly. Digital rectal examination shows a diffusely enlarged prostate with no nodules. Laboratory testing reveals a serum creatinine level of 1.9 mg/dL. Urine dipstick testing is negative, but 24-hour urinary protein excretion is elevated. Urine microscopy shows waxy, laminated casts. Imaging of the spine demonstrates diffuse osteopenia and multiple irregular, radiolucent lesions in the thoracic and lumbar vertebrae. Biopsy from one of the bone lesions is most likely to reveal which of the following histopathological findings?

A. Branching papillae lined by cuboidal cells with overlapping nuclei

B. Infiltrating glandular cells with substantial adjacent osteoblasts

C. Large, malignant cells containing keratin and intercellular bridges

D. Clusters of mature plasma cells and plasmablasts

E. Sheets of round or polygonal cells with abundant clear cytoplasm

Submit

A 64-year-old man comes to the office due to 3 months of constant, dull, low back pain that is worse with movement. The patient has also had intermittent episodes of difficulty urinating over the last year. He has no other medical conditions and takes no medications. The patient smoked a pack of cigarettes daily for 15 years but quit 10 years ago. Vital signs are within normal limits. On physical examination, the lungs are clear and heart sounds are normal. The abdomen is soft and nontender with no hepatosplenomegaly. Digital rectal examination shows a diffusely enlarged prostate with no nodules. Laboratory testing reveals a serum creatinine level of 1.9 mg/dL. Urine dipstick testing is negative, but 24-hour urinary protein excretion is elevated. Urine microscopy shows waxy, laminated casts. Imaging of the spine demonstrates diffuse osteopenia and multiple irregular, radiolucent lesions in the thoracic and lumbar vertebrae. Biopsy from one of the bone lesions is most likely to reveal which of the following histopathological findings?

A. Branching papillae lined by cuboidal cells with overlapping nuclei (3%)

B. Infiltrating glandular cells with substantial adjacent osteoblasts (21%)

C. Large, malignant cells containing keratin and intercellular bridges (7%)

✓ D. Clusters of mature plasma cells and plasmablasts (55%)

E. Sheets of round or polygonal cells with abundant clear cytoplasm (12%)

Omitted
Correct answer
D

55%
Answered correctly

04 secs
Time Spent

06/01/2020
Last Updated

Explanation

Multiple myeloma

Multiple myeloma	
Pathophysiology	• Plasma cell neoplasm produces **monoclonal** paraprotein (immunoglobulin)
Manifestations	• Bone pain, fractures • Constitutional symptoms (weight loss, fatigue) • Recurrent infections
Laboratory	• Normocytic anemia • Renal insufficiency • Hypercalcemia (constipation, muscle weakness) • Monoclonal paraproteinemia **(M-spike)**
Radiology	• **Osteolytic lesions**/osteopenia (osteoclast activation)

This older patient with back pain has several irregularly-shaped vertebral lesions, raising strong suspicion for metastatic disease. Differentiation of the underlying tumor is often assisted by whether the lesion is sclerotic (osteoblastic) or radiolucent (osteolytic). **Multiple myeloma**, a clonal plasma cell malignancy, is one of the most common causes of **radiolucent bone lesions** in adults; the tumor multiplies in the bone marrow and generates osteolytic cytokines, causing bone pain, bone destruction, pathologic fractures, and hypercalcemia.

Myeloma cells also produce excessive **monoclonal immunoglobulin** (paraprotein) that can clog the renal tubules and subsequently cause **light-chain cast nephropathy**. This is typically characterized by **mild renal insufficiency**, normal urine dipstick for protein (this test detects albumin only), elevated 24-hour urine protein (this test detects light-chain proteins), and waxy, laminated casts. Excessive light chains can also form fibrils and deposit in tissues, leading to amyloid light-chain amyloidosis. Monoclonal immunoglobulins are identified by urine or serum protein electrophoresis (M-spike).

The diagnosis of myeloma is confirmed by bone marrow aspirate or biopsy, which will demonstrate >10% plasma cells. Plasma cells are identified based upon "clock-face" chromatin, abundant basophilic cytoplasm, and prominent perinuclear clear areas (Golgi apparatus).

(Choice A) Papillary thyroid cancer is characterized by branching papillae lined by cuboidal cells with overlying nuclei (often with calcified psammoma bodies). Most cases progress slowly and present with a thyroid mass that may invade adjacent structures; bone lesions are relatively

This older patient with back pain has several irregularly-shaped vertebral lesions, raising strong suspicion for metastatic disease. Differentiation of the underlying tumor is often assisted by whether the lesion is sclerotic (osteoblastic) or radiolucent (osteolytic). **Multiple myeloma**, a clonal plasma cell malignancy, is one of the most common causes of **radiolucent bone lesions** in adults; the tumor multiplies in the bone marrow and generates osteolytic cytokines, causing bone pain, bone destruction, pathologic fractures, and hypercalcemia.

Myeloma cells also produce excessive **monoclonal immunoglobulin** (paraprotein) that can clog the renal tubules and subsequently cause **light-chain cast nephropathy**. This is typically characterized by **mild renal insufficiency**, normal urine dipstick for protein (this test detects albumin only), elevated 24-hour urine protein (this test detects light-chain proteins), and waxy, laminated casts. Excessive light chains can also form fibrils and deposit in tissues, leading to amyloid light-chain amyloidosis. Monoclonal immunoglobulins are identified by urine or serum protein electrophoresis (M-spike).

The diagnosis of myeloma is confirmed by bone marrow aspirate or biopsy, which will demonstrate >10% plasma cells. Plasma cells are identified based upon "clock-face" chromatin, abundant basophilic cytoplasm, and prominent perinuclear clear areas (Golgi apparatus).

(Choice A) Papillary thyroid cancer is characterized by branching papillae lined by cuboidal cells with overlying nuclei (often with calcified psammoma bodies). Most cases progress slowly and present with a thyroid mass that may invade adjacent structures; bone lesions are relatively uncommon.

(Choice B) Prostate adenocarcinoma is a glandular tumor that often spreads to the bones; however, it generates sclerotic (osteoblastic) bone lesions, not radiolucent bone lesions. Prostate cancer does not generally impinge on the urethra (no urinary symptoms) and is usually associated with a nodule on prostate examination. This patient's intermittent difficulty urinating and diffusely enlarged prostate with no nodules likely indicate benign prostatic hyperplasia.

(Choices C and E) Squamous cell lung cancer is associated with large, malignant cells containing keratin with intercellular bridges. Renal cell carcinoma is associated with sheets of round or polygonal cells with abundant clear cytoplasm. Although both tumors commonly form osteolytic lesions in the spine, neither regularly cause renal insufficiency, elevated urine protein, and waxy urinary casts.

Educational objective:
Multiple myeloma is a plasma cell malignancy that replicates in the bone marrow and causes osteolytic bone lesions, bone destruction, hypercalcemia, and pathologic fractures. Histopathology will show replacement of the normal bone marrow with plasma cells and blasts.

Exhibit Display

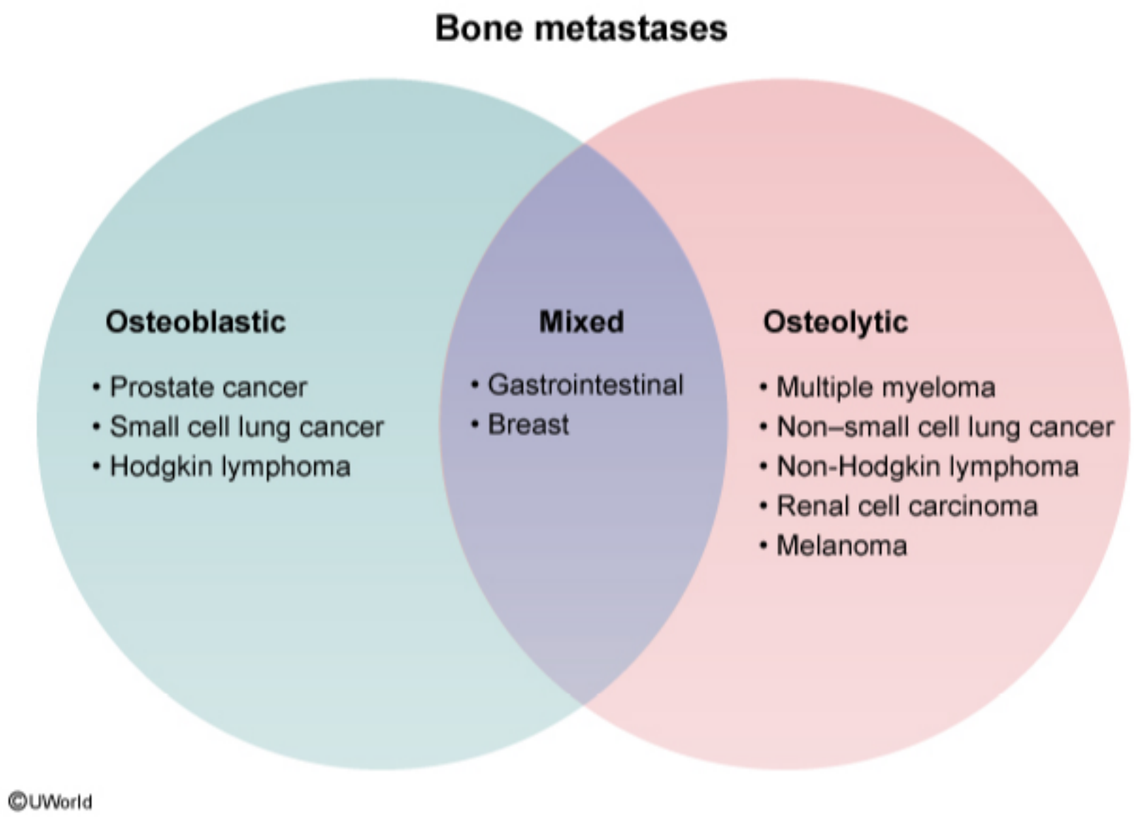

Zoom In | Zoom Out | Reset | Add To New Card | Existing Card

hypercalcemia, and pathologic fractures. Histopathology will show replacement of the normal bone marrow with plasma cells and blasts.

1
2
3
4
5
6
7
8
9
10
11
12
13
14
15
16
17
18
19
20
21
22
23
24
25
26
27
28
29
30

Exhibit Display

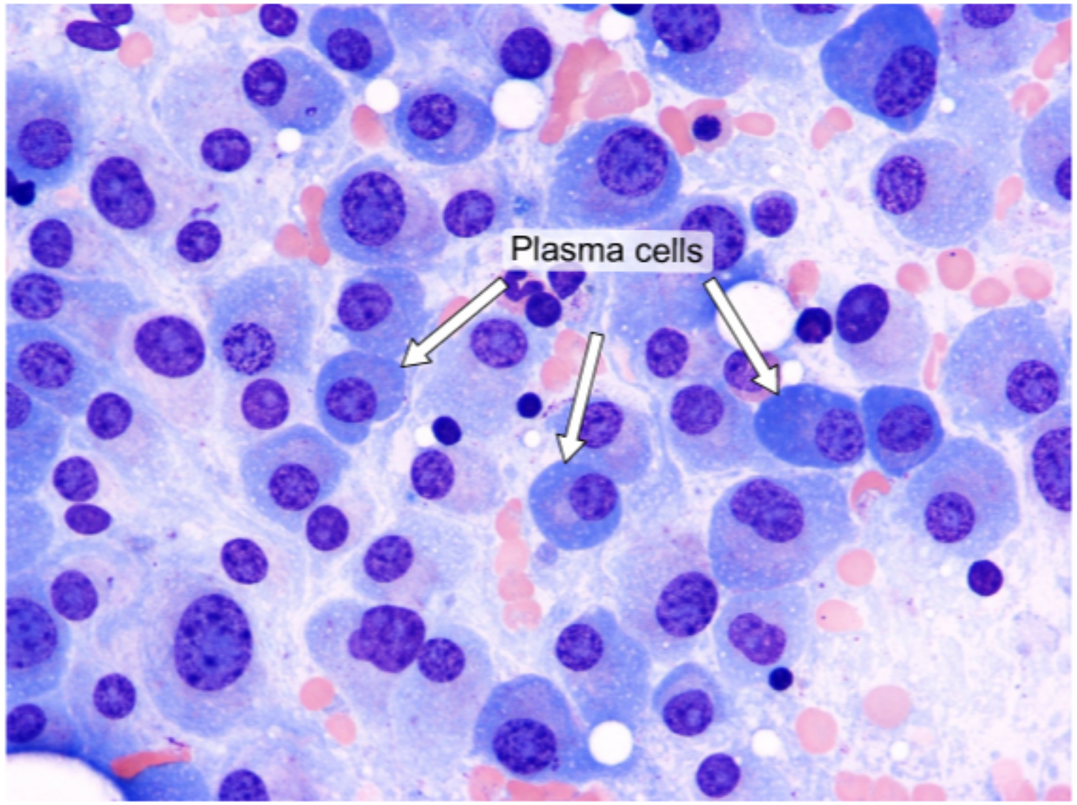

Zoom In
Zoom Out
Reset
Add To New Card | Existing Card

hypercalcemia, and pathologic fractures. Histopathology will show replacement of the normal bone marrow with plasma cells and blasts.

1
2
3
4
5
6
7
8
9
10
11
12
13
14
15
16
17
18
19
20
21
22
23
24
25
26
27
28
29
30

Exhibit Display

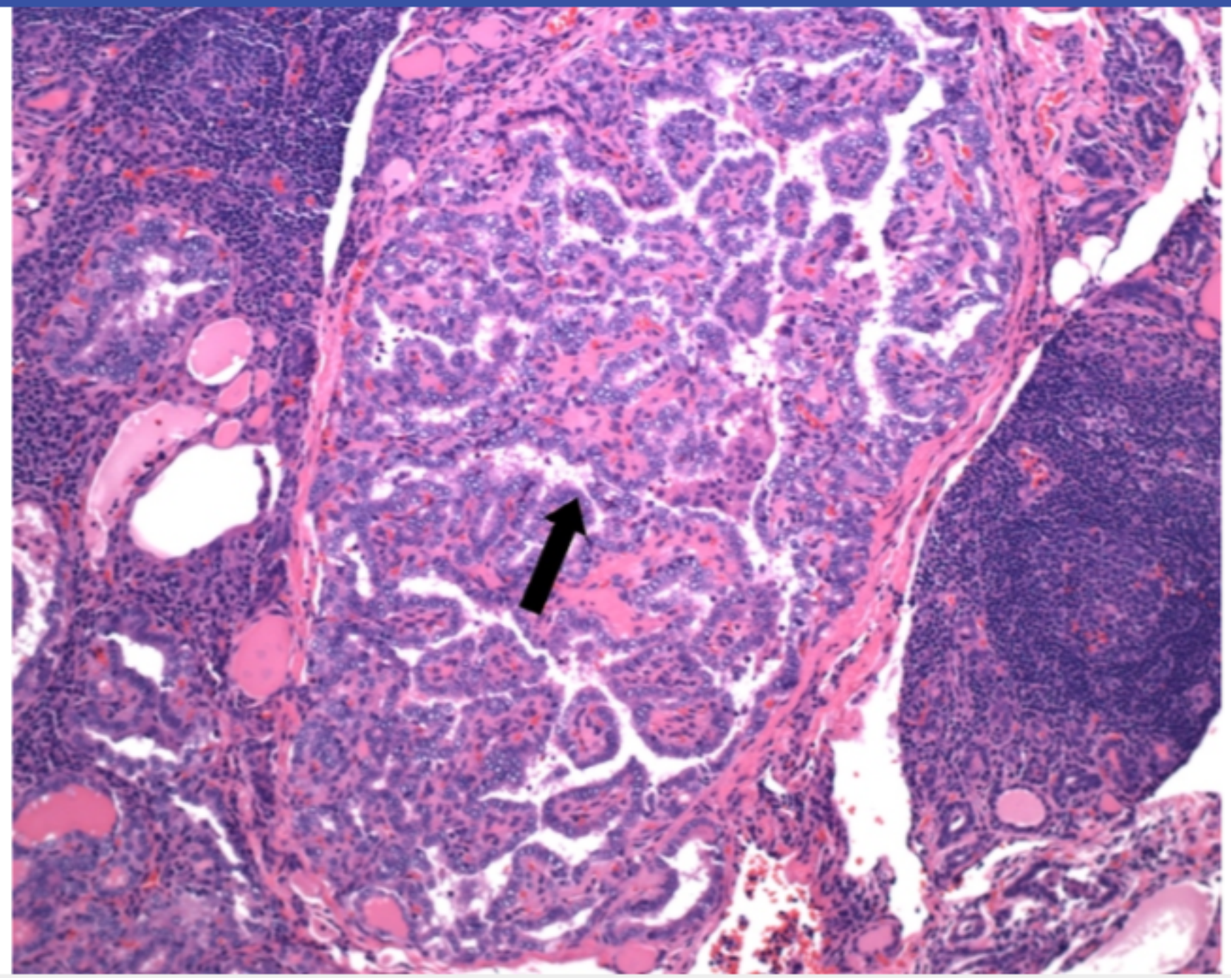

Zoom In | Zoom Out | Reset | Add To New Card | Existing Card

hypercalcemia, and pathologic fractures. Histopathology will show replacement of the normal bone marrow with plasma cells and blasts.

1
2
3
4
5
6
7
8
9
10
11
12
13
14
15
16
17
18
19
20
21
22
23
24
25
26
27
28
29
30

Exhibit Display

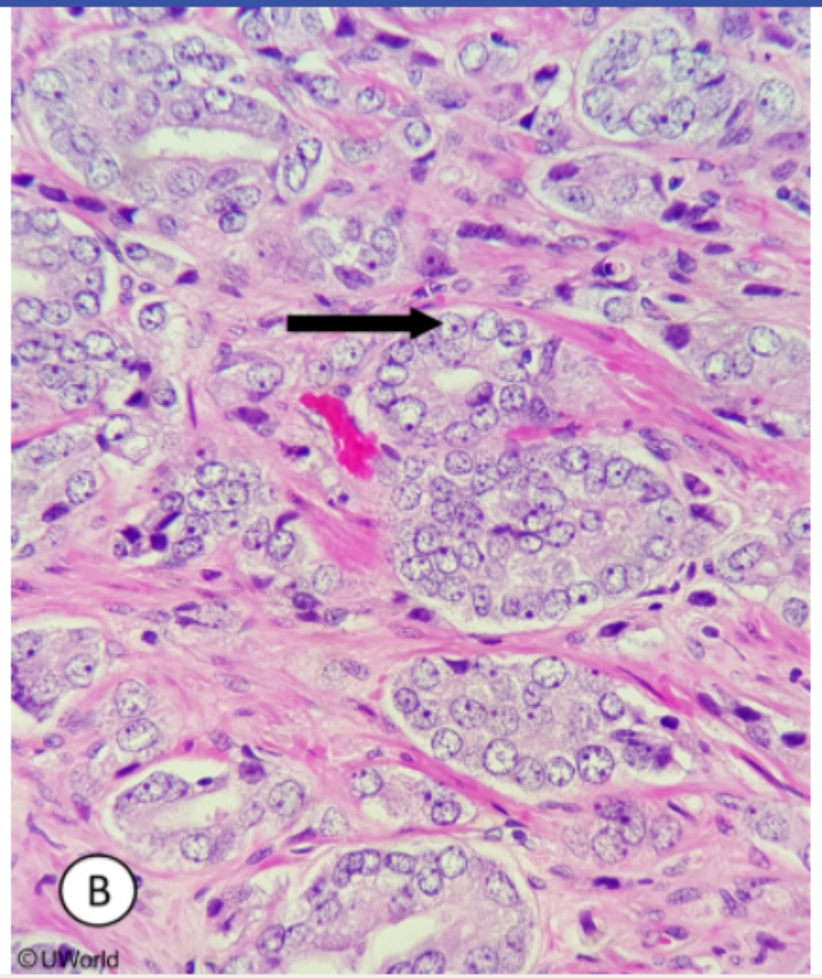

Zoom In | Zoom Out | Reset | Add To New Card | Existing Card

hypercalcemia, and pathologic fractures. Histopathology will show replacement of the normal bone marrow with plasma cells and blasts.

1
2
3
4
5
6
7
8
9
10
11
12
13
14
15
16
17
18
19
20
21
22
23
24
25
26
27
28
29
30

Exhibit Display

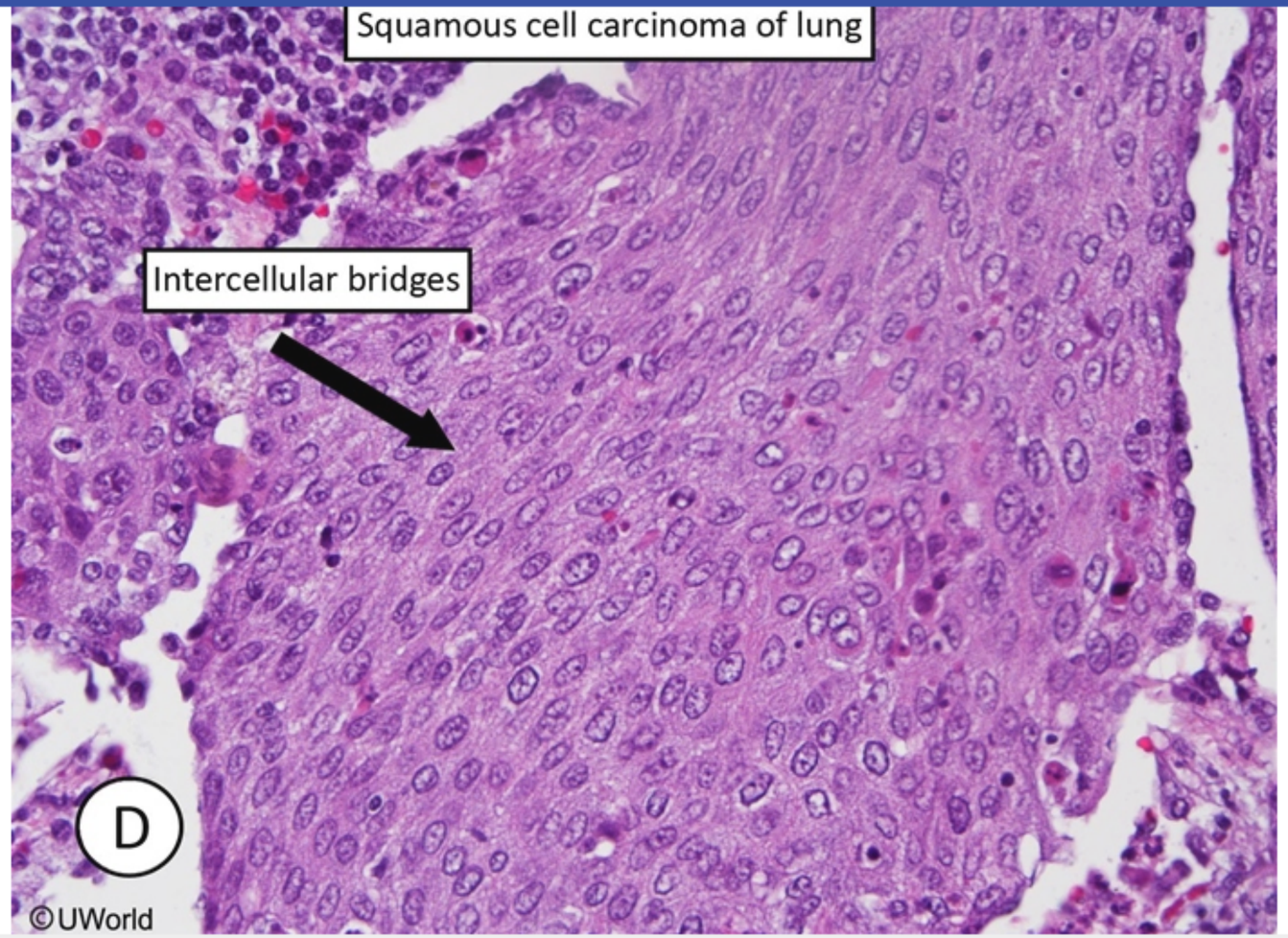

Zoom In | Zoom Out | Reset | Add To New Card | Existing Card

hypercalcemia, and pathologic fractures. Histopathology will show replacement of the normal bone marrow with plasma cells and blasts.

1
2
3
4
5
6
7
8
9
10
11
12
13
14
15
16
17
18
19
20
21
22
23
24
25
26
27
28
29
30

Exhibit Display

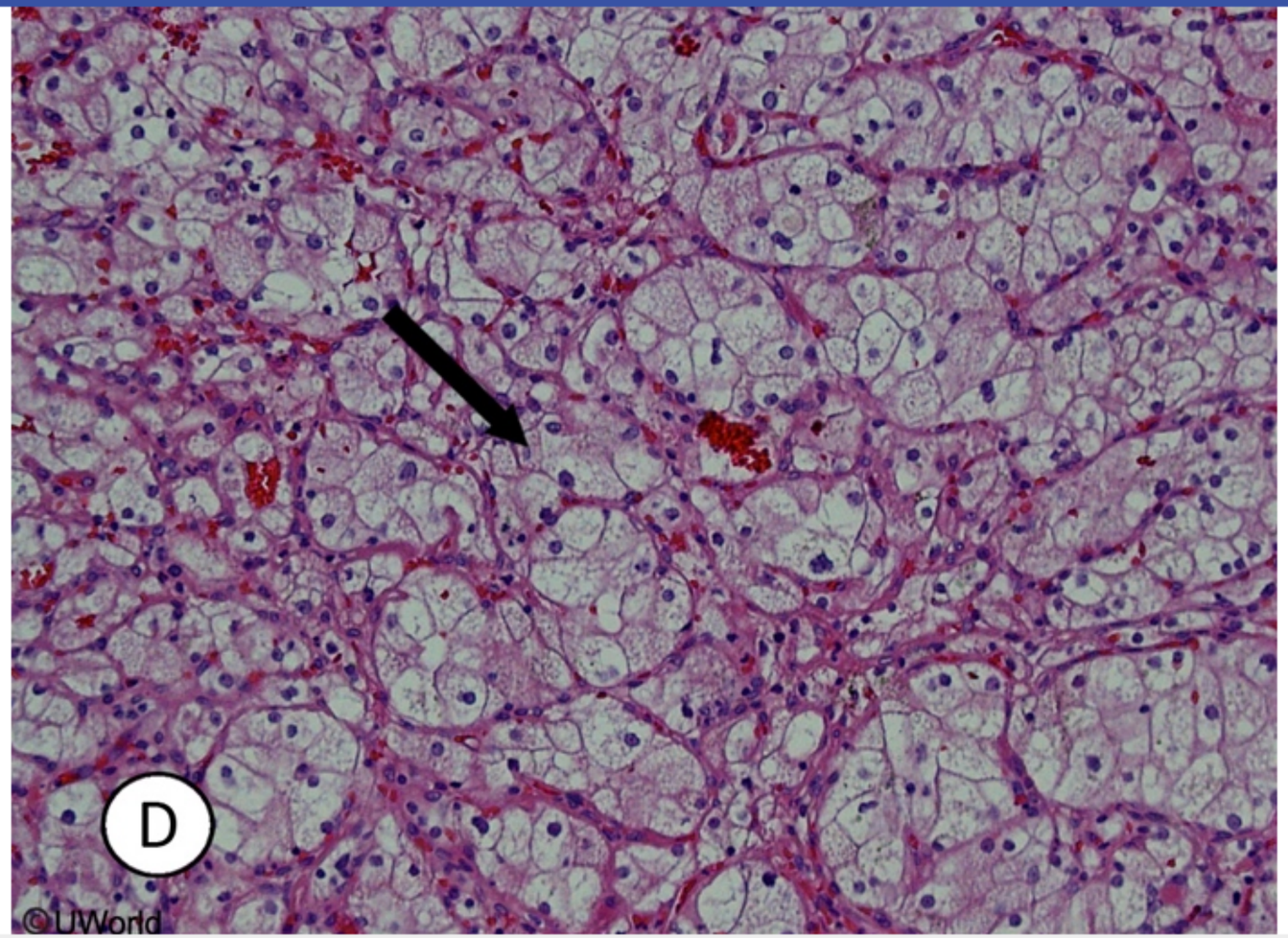

Zoom In | Zoom Out | Reset | Add To New Card | Existing Card

hypercalcemia, and pathologic fractures. Histopathology will show replacement of the normal bone marrow with plasma cells and blasts.

and deposit in tissues, leading to amyloid light-chain amyloidosis. Monoclonal immunoglobulins are identified by urine or serum protein electrophoresis (M-spike).

The diagnosis of myeloma is confirmed by bone marrow aspirate or biopsy, which will demonstrate >10% plasma cells. Plasma cells are identified based upon "clock-face" chromatin, abundant basophilic cytoplasm, and prominent perinuclear clear areas (Golgi apparatus).

(Choice A) Papillary thyroid cancer is characterized by branching papillae lined by cuboidal cells with overlying nuclei (often with calcified psammoma bodies). Most cases progress slowly and present with a thyroid mass that may invade adjacent structures; bone lesions are relatively uncommon.

(Choice B) Prostate adenocarcinoma is a glandular tumor that often spreads to the bones; however, it generates sclerotic (osteoblastic) bone lesions, not radiolucent bone lesions. Prostate cancer does not generally impinge on the urethra (no urinary symptoms) and is usually associated with a nodule on prostate examination. This patient's intermittent difficulty urinating and diffusely enlarged prostate with no nodules likely indicate benign prostatic hyperplasia.

(Choices C and E) Squamous cell lung cancer is associated with large, malignant cells containing keratin with intercellular bridges. Renal cell carcinoma is associated with sheets of round or polygonal cells with abundant clear cytoplasm. Although both tumors commonly form osteolytic lesions in the spine, neither regularly cause renal insufficiency, elevated urine protein, and waxy urinary casts.

Educational objective:
Multiple myeloma is a plasma cell malignancy that replicates in the bone marrow and causes osteolytic bone lesions, bone destruction, hypercalcemia, and pathologic fractures. Histopathology will show replacement of the normal bone marrow with plasma cells and blasts.

References

- Bone disease in multiple myeloma: pathophysiology and management.

Pathology	Hematology & Oncology	Multiple myeloma
Subject	System	Topic

Copyright © UWorld. All rights reserved.

Hemoglobin	13 g/dL
Platelets	350,000/mm^3
Leukocytes	54,000/mm^3
Neutrophils	65%
Band form	10%
Myelocyte	3%
Metamyelocyte	1%
Lymphocytes	15%

The leukocyte alkaline phosphatase test score is elevated. Which of the following is the most likely additional finding on this patient's blood smear?

A. Basophilic oval inclusions in mature neutrophils
B. Basophilic stippling of red blood cells
C. Immature cells with azurophilic rods
D. Neutrophils with hypersegmented nuclei
E. Small lymphoid cells with cleaved nuclei

Submit

A 24-year-old previously healthy woman comes to the hospital with a 3-day history of fever, dyspnea, and productive cough of yellow sputum. Her temperature is 38.8 C (102 F), blood pressure is 110/66 mm Hg, and pulse is 110/min. She has bronchial breath sounds and crackles in the right lower lung field. Laboratory studies are as follows:

Hemoglobin	13 g/dL
Platelets	350,000/mm^3
Leukocytes	54,000/mm^3
Neutrophils	65%
Band form	10%
Myelocyte	3%
Metamyelocyte	1%
Lymphocytes	15%

The leukocyte alkaline phosphatase test score is elevated. Which of the following is the most likely additional finding on this patient's blood smear?

A. Basophilic oval inclusions in mature neutrophils
B. Basophilic stippling of red blood cells
C. Immature cells with azurophilic rods
D. Neutrophils with hypersegmented nuclei
E. Small lymphoid cells with cleaved nuclei

Hemoglobin	13 g/dL
Platelets	350,000/mm^3
Leukocytes	54,000/mm^3
Neutrophils	65%
Band form	10%
Myelocyte	3%
Metamyelocyte	1%
Lymphocytes	15%

The leukocyte alkaline phosphatase test score is elevated. Which of the following is the most likely additional finding on this patient's blood smear?

A. Basophilic oval inclusions in mature neutrophils
B. Basophilic stippling of red blood cells
C. Immature cells with azurophilic rods
D. Neutrophils with hypersegmented nuclei
E. Small lymphoid cells with cleaved nuclei

Submit

1
2
3
4
5
6
7
8
9
10
11
12
13
14
15
16
17
18
19
20
21
22
23
24
25
26
27
28
29
30

Hemoglobin	13 g/dL
Platelets	350,000/mm^3
Leukocytes	54,000/mm^3
Neutrophils	65%
Band form	10%
Myelocyte	3%
Metamyelocyte	1%
Lymphocytes	15%

The leukocyte alkaline phosphatase test score is elevated. Which of the following is the most likely additional finding on this patient's blood smear?

- ✓ A. Basophilic oval inclusions in mature neutrophils (35%)
- B. Basophilic stippling of red blood cells (4%)
- C. Immature cells with azurophilic rods (28%)
- D. Neutrophils with hypersegmented nuclei (22%)
- E. Small lymphoid cells with cleaved nuclei (9%)

Omitted
Correct answer

35%
Answered correctly

05 secs
Time Spent

06/07/2020
Last Updated

1
2
3
4
5
6
7
8
9
10
11
12
13
14
15
16
17
18
19
20
21
22
23
24
25
26
27
28
29
30

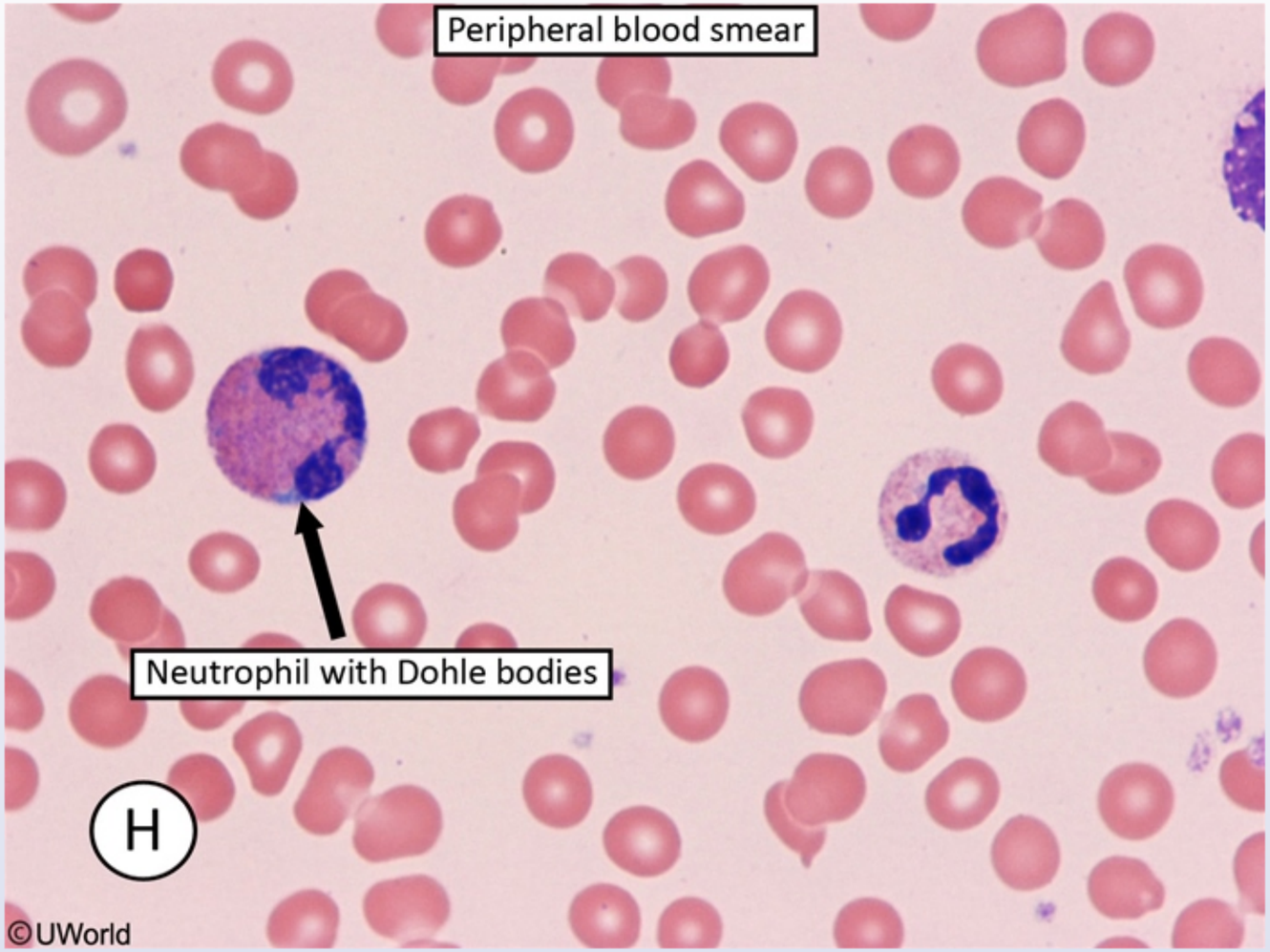

This patient most likely has pneumonia with sepsis and a **leukemoid reaction**, defined as a benign leukocytosis (>50,000/mm^3) that occurs in response to an underlying condition such as severe infection/hemorrhage, solid tumors, or acute hemolysis. The bone marrow can be normal or hypercellular and responds with increased bands and early mature neutrophil precursors (eg, myelocytes), in contrast to the increased immature cells (eg, promyelocytes, myeloblasts) seen in acute leukemia.

©UWorld

This patient most likely has pneumonia with sepsis and a **leukemoid reaction**, defined as a benign leukocytosis (>50,000/mm^3) that occurs in response to an underlying condition such as severe infection/hemorrhage, solid tumors, or acute hemolysis. The bone marrow can be normal or hypercellular and responds with increased bands and early mature neutrophil precursors (eg, myelocytes), in contrast to the increased immature cells (eg, promyelocytes, myeloblasts) seen in acute leukemia.

Serum **leukocyte alkaline phosphatase** can be normal or increased in leukemoid reaction, but it is usually low in chronic myelogenous leukemia. The peripheral smear can show **Döhle bodies**, which are light blue (**basophilic**) peripheral granules in neutrophils. The blue color is likely due to ribosomes bound with rough endoplasmic reticulum. Döhle bodies are commonly seen in toxic systemic illness but can also occur with burns or myelodysplasia. Other findings of systemic inflammation or infection include increased bands (left shift), toxic granulation, and cytoplasmic vacuoles.

(Choice B) Basophilic stippling refers to various sizes of blue granules representing ribosomal precipitates in the cytoplasm of red blood cells. It is most often seen in the thalassemias, alcohol abuse, and lead/heavy metal poisoning. This patient's acute presentation is more consistent with leukemoid reaction.

(Choice C) Auer rods are azurophilic rod-like granules in the cytoplasm of immature cells (blasts) and are essentially pathognomonic of acute myeloid leukemia. However, this patient's complete blood count shows mainly mature neutrophil precursors.

(Choice D) Neutrophils typically have nuclei with 3-4 lobes, and hypersegmented neutrophils with >5 lobes suggest a megaloblastic process (eg, vitamin B_{12} or folate deficiency). This patient's normal hemoglobin makes this unlikely.

(Choice E) Small lymphoid cells with increased nuclei to cytoplasmic ratio and cleaved nuclei are seen in certain types of lymphoma, particularly follicular lymphoma. This patient's acute presentation is more consistent with leukemoid reaction.

Educational objective:
Leukemoid reaction is a benign leukocytosis (>50,000/mm^3) that occurs in response to an underlying condition such as severe infection/hemorrhage, malignancy (eg, leukemia), or acute hemolysis. Leukocyte alkaline phosphatase levels are normal or increased. Peripheral smear can show increased bands, early mature neutrophil precursors (eg, myelocytes), and granules (eg, Döhle bodies) in the neutrophils.

References

©UWorld

Exhibit Display

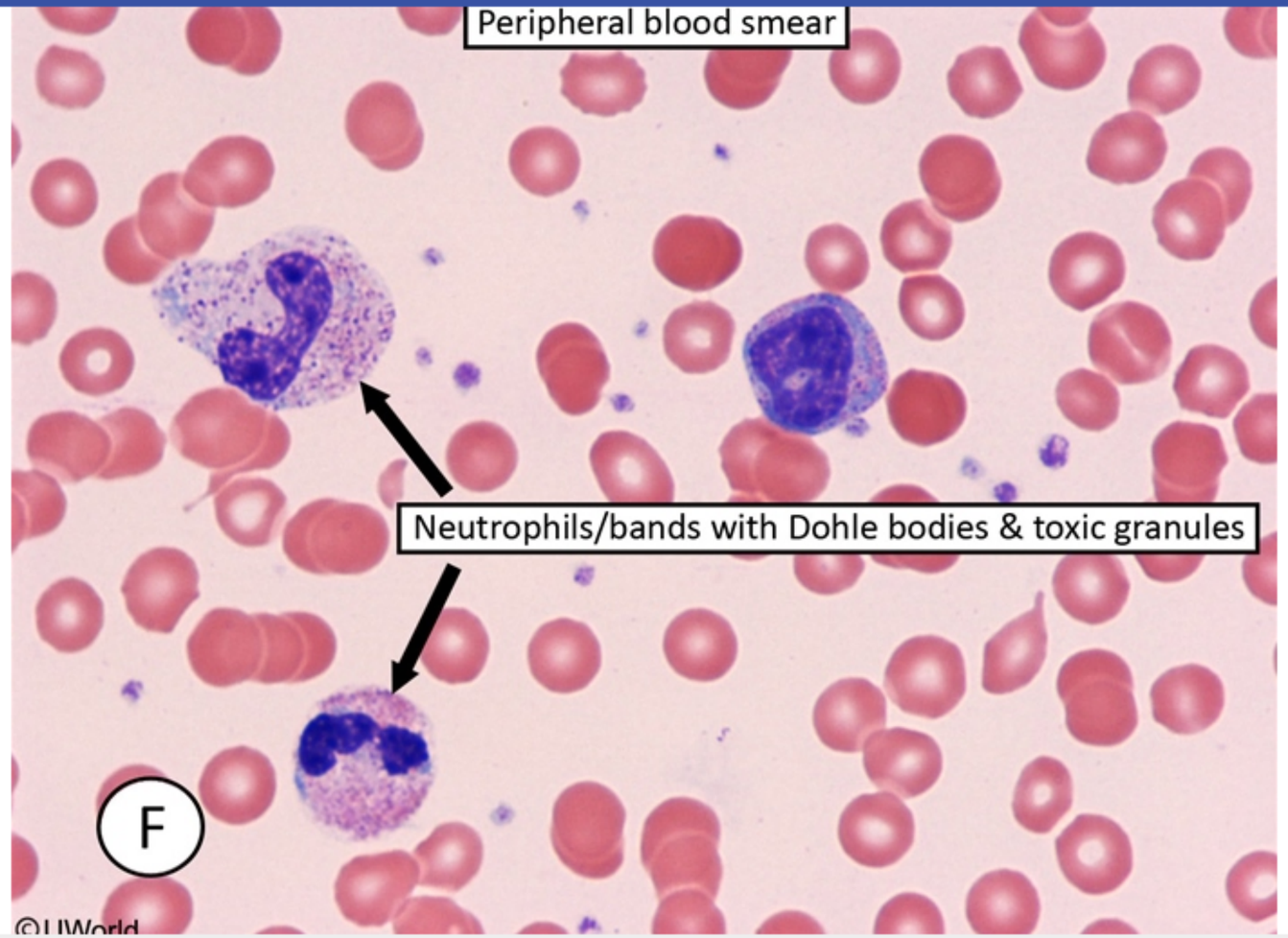

Zoom In | Zoom Out | Reset | Add To New Card | Existing Card

References

©UWorld

Exhibit Display

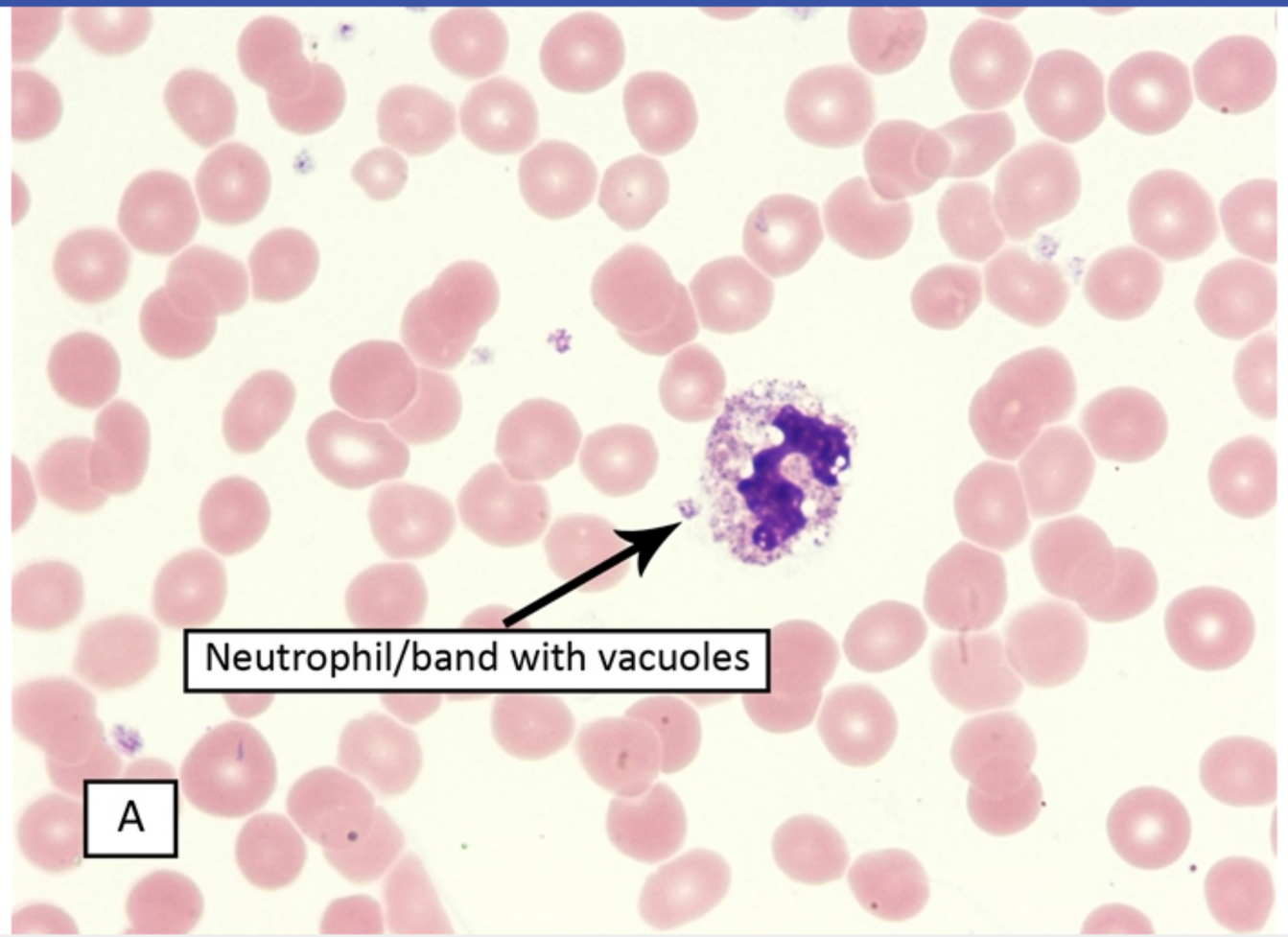

Zoom In | Zoom Out | Reset | Add To New Card | Existing Card

References

©UWorld

Exhibit Display

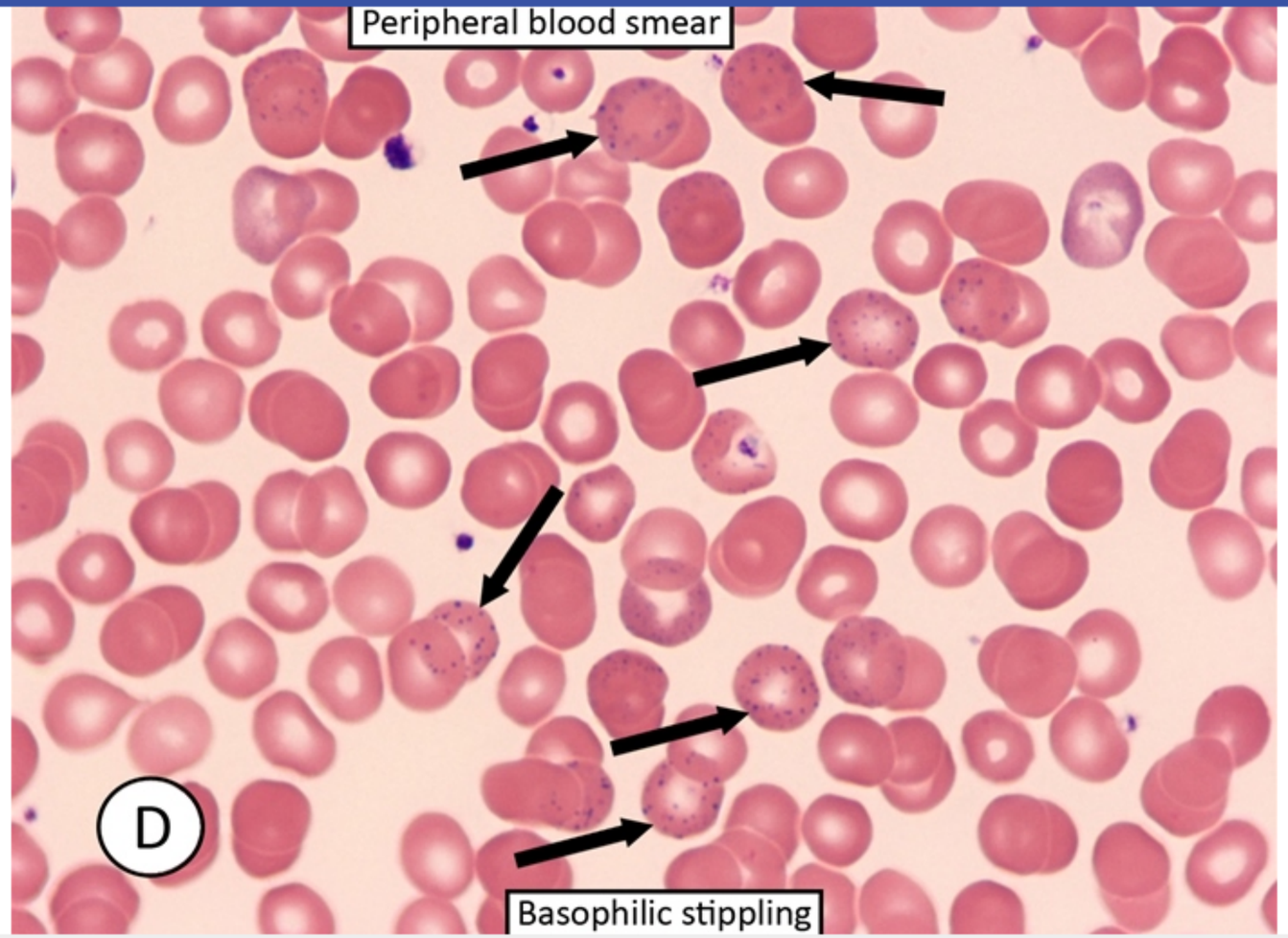

Zoom In | Zoom Out | Reset | Add To New Card | Existing Card

References

©UWorld

Exhibit Display

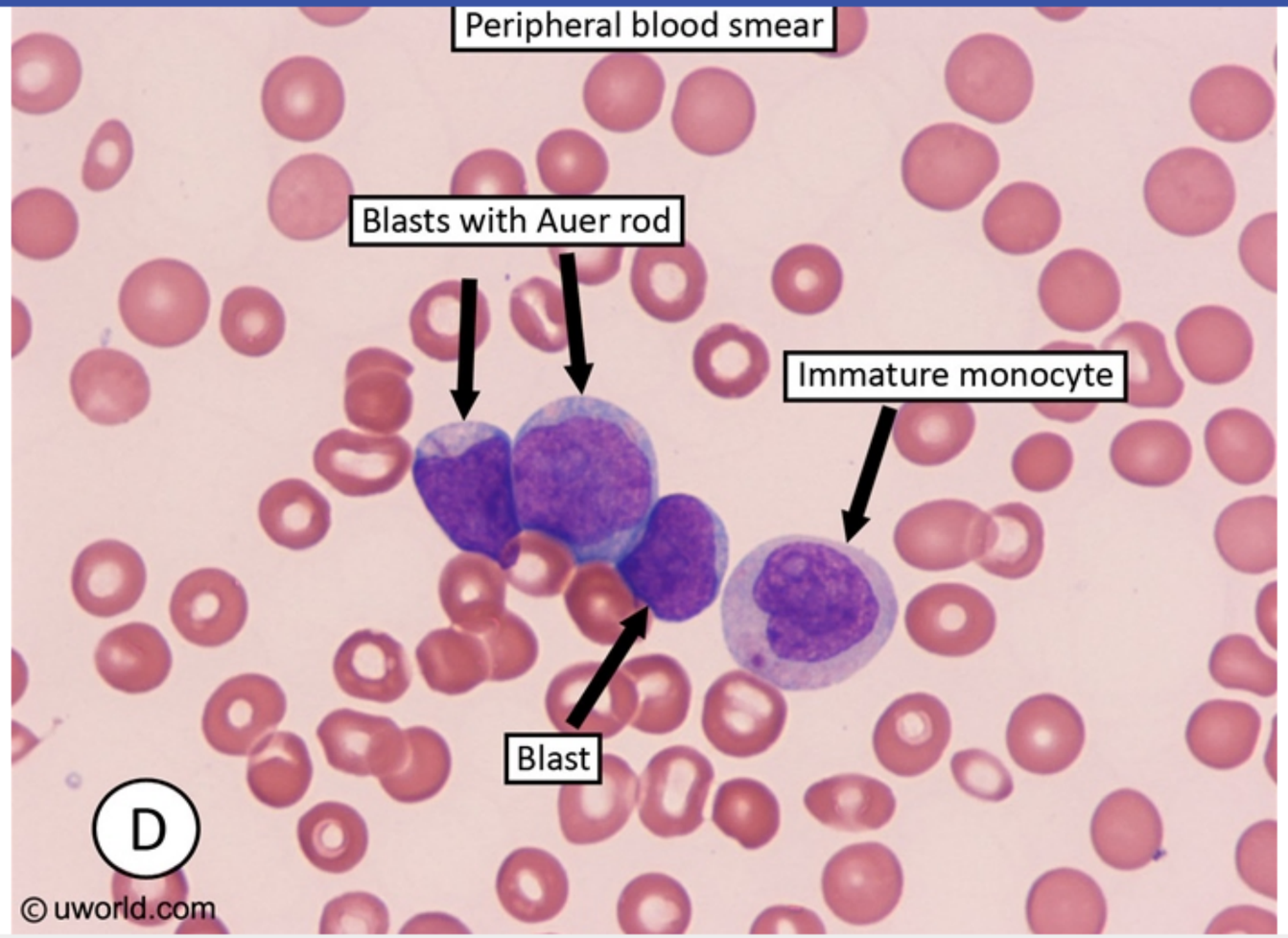

Zoom In | Zoom Out | Reset | Add To New Card | Existing Card

References

©UWorld

Exhibit Display

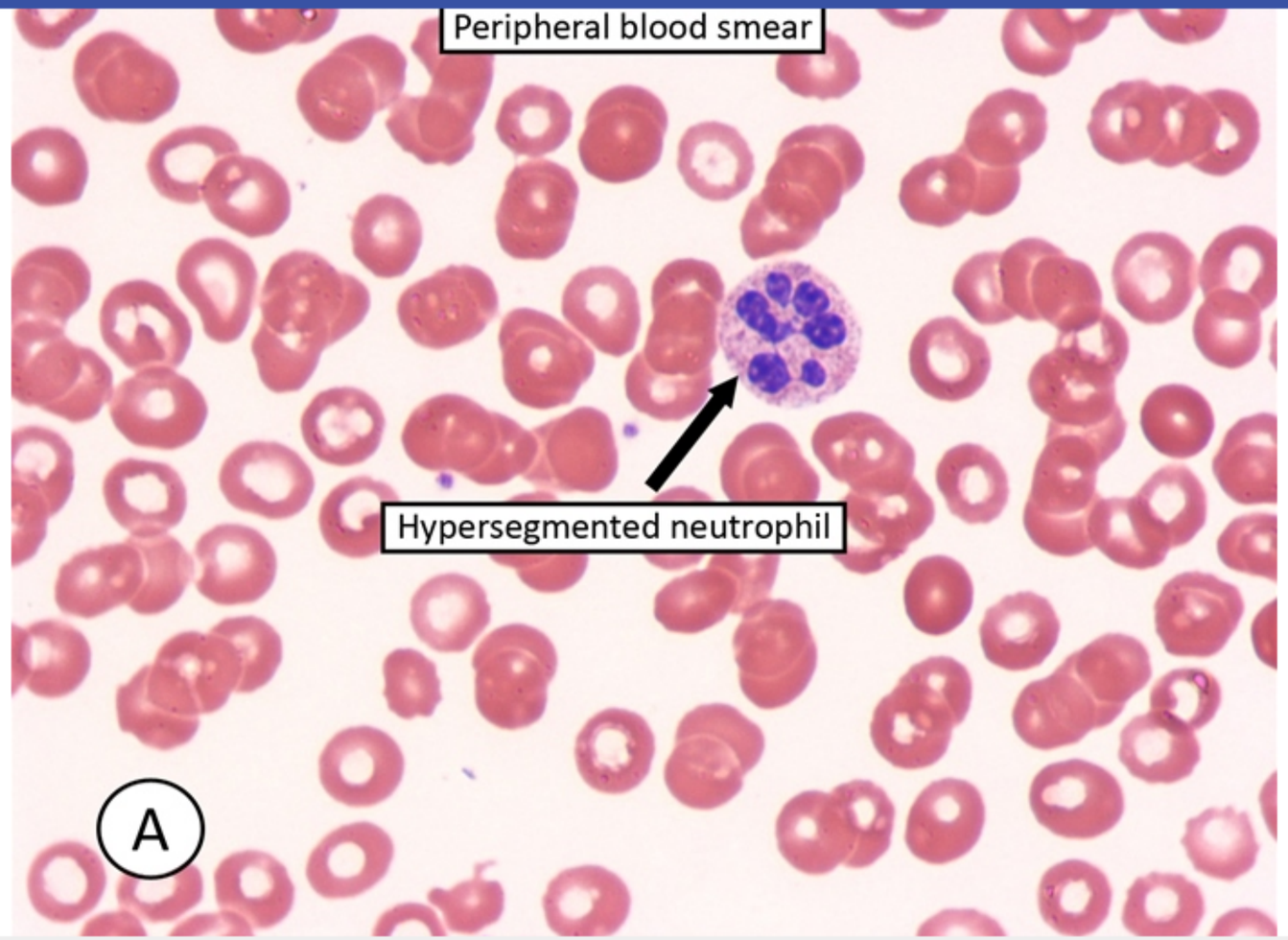

Zoom In | Zoom Out | Reset | Add To New Card | Existing Card

References

©UWorld

Exhibit Display

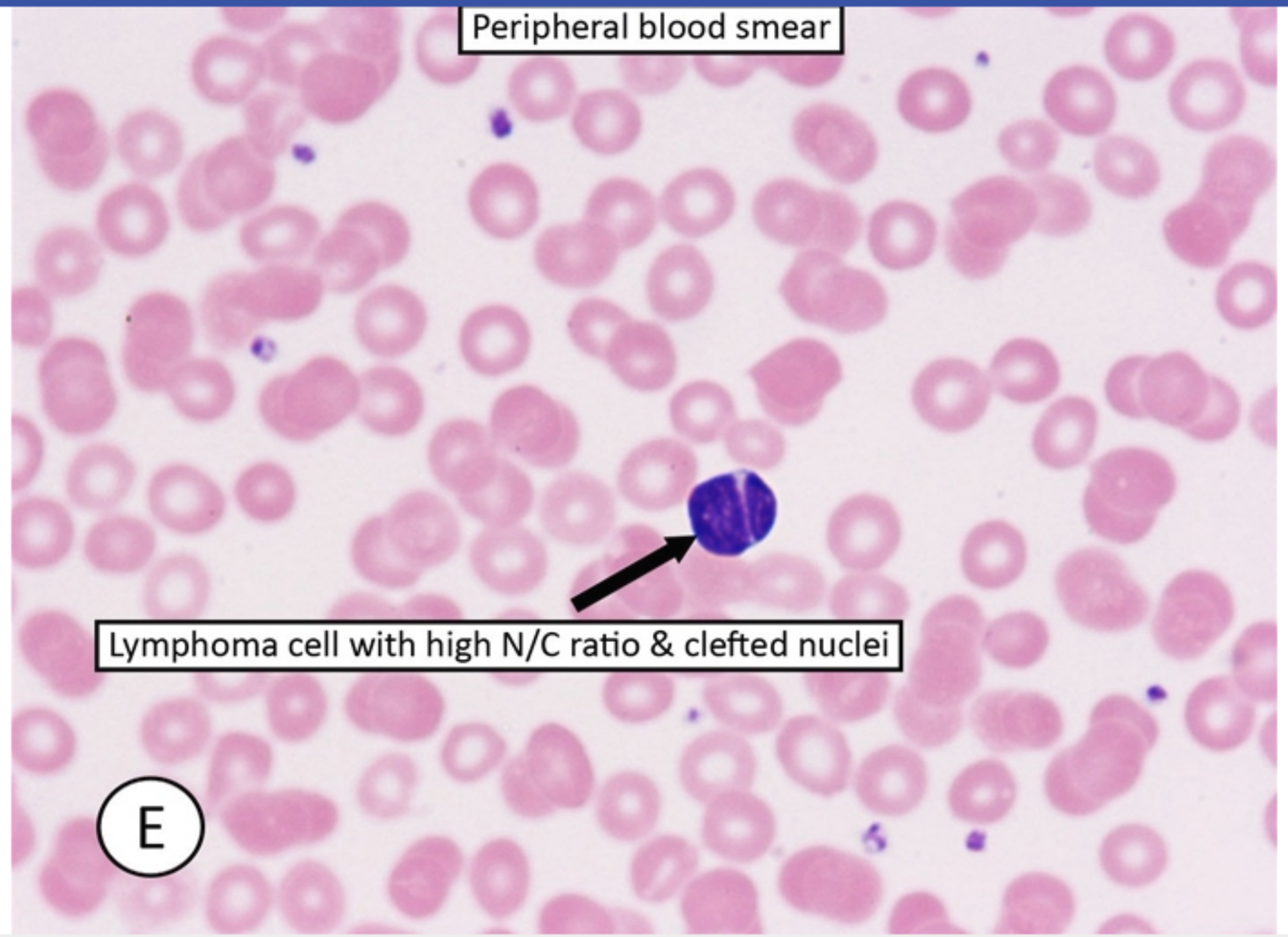

Zoom In | Zoom Out | Reset | Add To New Card | Existing Card

References

leukemia. The peripheral smear can show **Döhle bodies**, which are light blue (**basophilic**) peripheral granules in neutrophils. The blue color is likely due to ribosomes bound with rough endoplasmic reticulum. Döhle bodies are commonly seen in toxic systemic illness but can also occur with burns or myelodysplasia. Other findings of systemic inflammation or infection include increased bands (left shift), toxic granulation, and cytoplasmic vacuoles.

(Choice B) Basophilic stippling refers to various sizes of blue granules representing ribosomal precipitates in the cytoplasm of red blood cells. It is most often seen in the thalassemias, alcohol abuse, and lead/heavy metal poisoning. This patient's acute presentation is more consistent with leukemoid reaction.

(Choice C) Auer rods are azurophilic rod-like granules in the cytoplasm of immature cells (blasts) and are essentially pathognomonic of acute myeloid leukemia. However, this patient's complete blood count shows mainly mature neutrophil precursors.

(Choice D) Neutrophils typically have nuclei with 3-4 lobes, and hypersegmented neutrophils with >5 lobes suggest a megaloblastic process (eg, vitamin B_{12} or folate deficiency). This patient's normal hemoglobin makes this unlikely.

(Choice E) Small lymphoid cells with increased nuclei to cytoplasmic ratio and cleaved nuclei are seen in certain types of lymphoma, particularly follicular lymphoma. This patient's acute presentation is more consistent with leukemoid reaction.

Educational objective:
Leukemoid reaction is a benign leukocytosis (>50,000/mm^3) that occurs in response to an underlying condition such as severe infection/hemorrhage, malignancy (eg, leukemia), or acute hemolysis. Leukocyte alkaline phosphatase levels are normal or increased. Peripheral smear can show increased bands, early mature neutrophil precursors (eg, myelocytes), and granules (eg, Döhle bodies) in the neutrophils.

References

- An update on the etiology and diagnostic evaluation of a leukemoid reaction.

Pathology	Hematology & Oncology	Leukocytosis
Subject	System	Topic

Copyright © UWorld. All rights reserved.

A 45-year-old man comes to the emergency department due to epigastric abdominal pain and fatigue. He has had similar episodes of pain in the past. Temperature is 37.1 C (98.8 F), blood pressure is 128/69 mm Hg, pulse is 92/min, and respirations are 16/min. Physical examination shows mild epigastric tenderness and hepatomegaly. There is no jaundice or lymphadenopathy. Laboratory results are as follows:

Complete blood count

Hemoglobin	9.0 g/dL
Mean corpuscular volume (MCV)	115 μm^3
Platelets	130,000/mm^3
Leukocytes	5,500/mm^3

CT scan of the abdomen shows pancreatic calcifications. Right upper quadrant ultrasound reveals no evidence of gallstones. Which of the following processes is most likely responsible for this patient's anemia?

A. Diminished thymidine synthesis
B. Impaired globin chain synthesis
C. Impaired pyruvate decarboxylation
D. Low rate of intracellular transamination reactions
E. Reduced iron availability for hemoglobin synthesis

Submit

A 45-year-old man comes to the emergency department due to epigastric abdominal pain and fatigue. He has had similar episodes of pain in the past. Temperature is 37.1 C (98.8 F), blood pressure is 128/69 mm Hg, pulse is 92/min, and respirations are 16/min. Physical examination shows mild epigastric tenderness and hepatomegaly. There is no jaundice or lymphadenopathy. Laboratory results are as follows:

Complete blood count

Hemoglobin	9.0 g/dL
Mean corpuscular volume (MCV)	115 μm^3
Platelets	130,000/mm^3
Leukocytes	5,500/mm^3

CT scan of the abdomen shows pancreatic calcifications. Right upper quadrant ultrasound reveals no evidence of gallstones. Which of the following processes is most likely responsible for this patient's anemia?

- ✓ A. Diminished thymidine synthesis (62%)
- B. Impaired globin chain synthesis (7%)
- C. Impaired pyruvate decarboxylation (9%)
- D. Low rate of intracellular transamination reactions (12%)
- E. Reduced iron availability for hemoglobin synthesis (8%)

Omitted
Correct answer
A

62%
Answered correctly

02 secs
Time Spent

05/09/2020
Last Updated

1 2 3 4 5 6 7 8 9 10 11 12 13 14 15 16 17 18 19 20 21 22 23 24 25 26 27 28 29 30

Explanation

This patient's recurrent abdominal pain and pancreatic calcifications suggest **chronic pancreatitis**, the most common cause of which is ethanol abuse. His **hepatomegaly** is likely due to alcohol-associated hepatic steatosis. The patient also has **macrocytic anemia** (low hemoglobin and elevated mean corpuscular volume [MCV] >100 μm^3), which in alcoholics often develops due to folic acid deficiency (within months) or vitamin B_{12} deficiency (within years).

Both deficiencies lead to **megaloblastosis**, the underlying biochemical feature of which is a defect in DNA synthesis. Folic acid is a single carbon donor required for synthesis of purine and pyrimidine (eg, thymidine) bases incorporated in DNA. RNA and protein synthesis may continue relatively unaltered, leading to a state of unbalanced cytoplasmic growth with impaired cell division. Pancreatic insufficiency is also associated with vitamin B_{12} deficiency as pancreatic enzymes normally cleave R factor from B_{12}, allowing B_{12} to bind to intrinsic factor and be absorbed.

(Choice B) The thalassemias are disorders presenting with reduced or absent globin chain production. Almost all thalassemia cases result in hypochromia and microcytosis (low MCV).

(Choice C) Oxidative decarboxylation of pyruvate by pyruvate dehydrogenase requires thiamine pyrophosphate (TPP), a derivative of thiamine (vitamin B_1). Alcoholics may be prone to thiamine deficiency and could therefore suffer from impaired pyruvate decarboxylation, but this does not cause macrocytic anemia.

(Choice D) Vitamin B_6 (pyridoxine) catalyzes the transaminase reactions by acting as a carrier of the amino group. B_6 deficiency can cause an anemia that is hypochromic, microcytic (low MCV), and sideroblastic.

(Choice E) Iron deficiency anemia is typically hypochromic and microcytic (low MCV <80 μm^3).

Educational objective:
The underlying biochemical feature of megaloblastosis is a defect in DNA synthesis. In chronic alcoholics, megaloblastic macrocytic anemia can result from a nutritional deficiency of vitamin B_{12} or of folate, which impairs synthesis of purine and pyrimidine bases.

Pathology	Hematology & Oncology	Anemia
Subject	System	Topic

Copyright © UWorld. All rights reserved.

This patient's recurrent abdominal pain and pancreatic calcifications suggest **chronic pancreatitis**, the most common cause of which is ethanol abuse. His **hepatomegaly** is likely due to alcohol-associated hepatic steatosis. The patient also has **macrocytic anemia** (low hemoglobin and elevated mean corpuscular volume [MCV] >100 μm^3), which in alcoholics often develops due to folic acid deficiency (within months) or vitamin B_{12} deficiency (within years).

Both deficiencies lead to **megaloblastosis**, the underlying biochemical feature of which is a defect in DNA synthesis. Folic acid is a single carbon donor required for synthesis of purine and pyrimidine (eg, thymidine) bases incorporated in DNA. RNA and protein synthesis may continue relatively unaltered, leading to a state of unbalanced cytoplasmic growth with impaired cell division. Pancreatic insufficiency is also associated with vitamin B_{12} deficiency as pancreatic enzymes normally cleave R factor from B_{12}, allowing B_{12} to bind to intrinsic factor and be absorbed.

(Choice B) The thalassemias are disorders presenting with reduced or absent globin chain production. Almost all thalassemia cases result in hypochromia and microcytosis (low MCV).

(Choice C) Oxidative decarboxylation of pyruvate by pyruvate dehydrogenase requires thiamine pyrophosphate (TPP), a derivative of thiamine (vitamin B_1). Alcoholics may be prone to thiamine deficiency and could therefore suffer from impaired pyruvate decarboxylation, but this does not cause macrocytic anemia.

(Choice D) Vitamin B_6 (pyridoxine) catalyzes the transaminase reactions by acting as a carrier of the amino group. B_6 deficiency can cause an anemia that is hypochromic, microcytic (low MCV), and sideroblastic.

(Choice E) Iron deficiency anemia is typically hypochromic and microcytic (low MCV <80 μm^3).

Educational objective:
The underlying biochemical feature of megaloblastosis is a defect in DNA synthesis. In chronic alcoholics, megaloblastic macrocytic anemia can result from a nutritional deficiency of vitamin B_{12} or of folate, which impairs synthesis of purine and pyrimidine bases.

Pathology	Hematology & Oncology	Anemia
Subject	System	Topic

Copyright © UWorld. All rights reserved.

A 42-year-old man is hospitalized with fever and persistent sore throat. On physical examination, his temperature is 38.3 C (101 F), blood pressure is 120/80 mm Hg, pulse is 94/min, and respirations are 16/min. There are several bruises on his trunk, and blood is oozing from his intravenous catheter venipuncture sites. His blood fibrinogen level is 110 mg/dL (normal 150-400 mg/dL). Bone marrow biopsy shows a predominance of immature myeloid cells with azurophilic needle-shaped cytoplasmic granules. Chromosomal analysis of these immature cells is most likely to show which of the following abnormalities?

- A. t(8;14)
- B. t(9;22)
- C. t(14;18)
- D. t(15;17)
- E. inv(16)

Submit

A 42-year-old man is hospitalized with fever and persistent sore throat. On physical examination, his temperature is 38.3 C (101 F), blood pressure is 120/80 mm Hg, pulse is 94/min, and respirations are 16/min. There are several bruises on his trunk, and blood is oozing from his intravenous catheter venipuncture sites. His blood fibrinogen level is 110 mg/dL (normal 150-400 mg/dL). Bone marrow biopsy shows a predominance of immature myeloid cells with azurophilic needle-shaped cytoplasmic granules. Chromosomal analysis of these immature cells is most likely to show which of the following abnormalities?

- A. t(8;14) (3%)
- B. t(9;22) (14%)
- C. t(14;18) (6%)
- ✓ D. t(15;17) (75%)
- E. inv(16) (0%)

Omitted
Correct answer
D

75%
Answered correctly

02 secs
Time Spent

06/20/2020
Last Updated

Explanation

This patient, who has fever (suggesting infection and possibly low leukocyte count) and bruising/oozing from venipuncture sites (suggesting low platelet count) associated with low fibrinogen levels and immature myeloid cells, likely has disseminated intravascular coagulation (DIC) in the setting of **acute promyelocytic leukemia (APL)**. APL, a subtype of acute myelogenous leukemia (AML), is characterized by the presence in the bone marrow of promyelocytes (**immature** myeloid cells) that typically contain needle-shaped cytoplasmic inclusions known as **Auer rods** (fused lysosomal granules). A classic presentation is bleeding in the setting of **DIC**, a consumptive coagulopathy characterized by **decreased**

This patient, who has fever (suggesting infection and possibly low leukocyte count) and bruising/oozing from venipuncture sites (suggesting low platelet count) associated with low fibrinogen levels and immature myeloid cells, likely has disseminated intravascular coagulation (DIC) in the setting of **acute promyelocytic leukemia (APL)**. APL, a subtype of acute myelogenous leukemia (AML), is characterized by the presence in the bone marrow of promyelocytes (**immature** myeloid cells) that typically contain needle-shaped cytoplasmic inclusions known as **Auer rods** (fused lysosomal granules). A classic presentation is bleeding in the setting of **DIC**, a consumptive coagulopathy characterized by **decreased fibrinogen levels**, increased fibrin degradation products, prolonged prothrombin time and partial thromboplastin time, and thrombocytopenia that is generally not low enough to result in spontaneous bleeding by itself.

APL is most commonly associated with a t(15;17) chromosomal translocation that causes fusion of the retinoic acid receptor-α (RARA) gene to the promyelocyte leukemia (PML) gene. APL is referred to as AML **M3** in the French-American-British (FAB) classification of leukemia and is responsive to all-trans retinoic acid therapy.

(Choice A) t(8;14) occurs in ~80% of cases of Burkitt lymphoma and results in movement of the *myc* protooncogene from chromosome 8 to a region near the immunoglobulin promoter site on chromosome 14.

(Choice B) t(9;22) forms the Philadelphia chromosome associated with chronic myelogenous leukemia (CML). The BCR-ABL fusion protein results from this cytogenetic defect. Auer rods are not typically present in CML, in which mature myeloid forms are generally seen. Most patients with CML present in the chronic, stable phase (eg, nonspecific symptoms, abdominal fullness, leukocytosis).

(Choice C) t(14;18) is associated with non-Hodgkin follicular small cleaved cell lymphoma. This abnormality places the BCL-2 protooncogene from chromosome 18 near the immunoglobulin heavy chain promoter region on chromosome 14.

(Choice E) A chromosome 16 inversion is observed in the M4Eo (eosinophilic) subtype of AML.

Educational objective:
Acute promyelocytic leukemia (APL, M3 acute myeloid leukemia) can present with persistent infection and coagulopathy causing hemorrhagic signs and symptoms. Bone marrow biopsy classically reveals promyelocytes with intracytoplasmic Auer rods. APL is associated with a t(15;17) chromosomal translocation that causes fusion of the retinoic acid receptor-α gene and promyelocyte leukemia gene.

Pathology	Hematology & Oncology	Acute promyelocytic leukemia
Subject	System	Topic

This patient, who has fever (suggesting infection and possibly low leukocyte count) and bruising/oozing from venipuncture sites (suggesting low

Exhibit Display

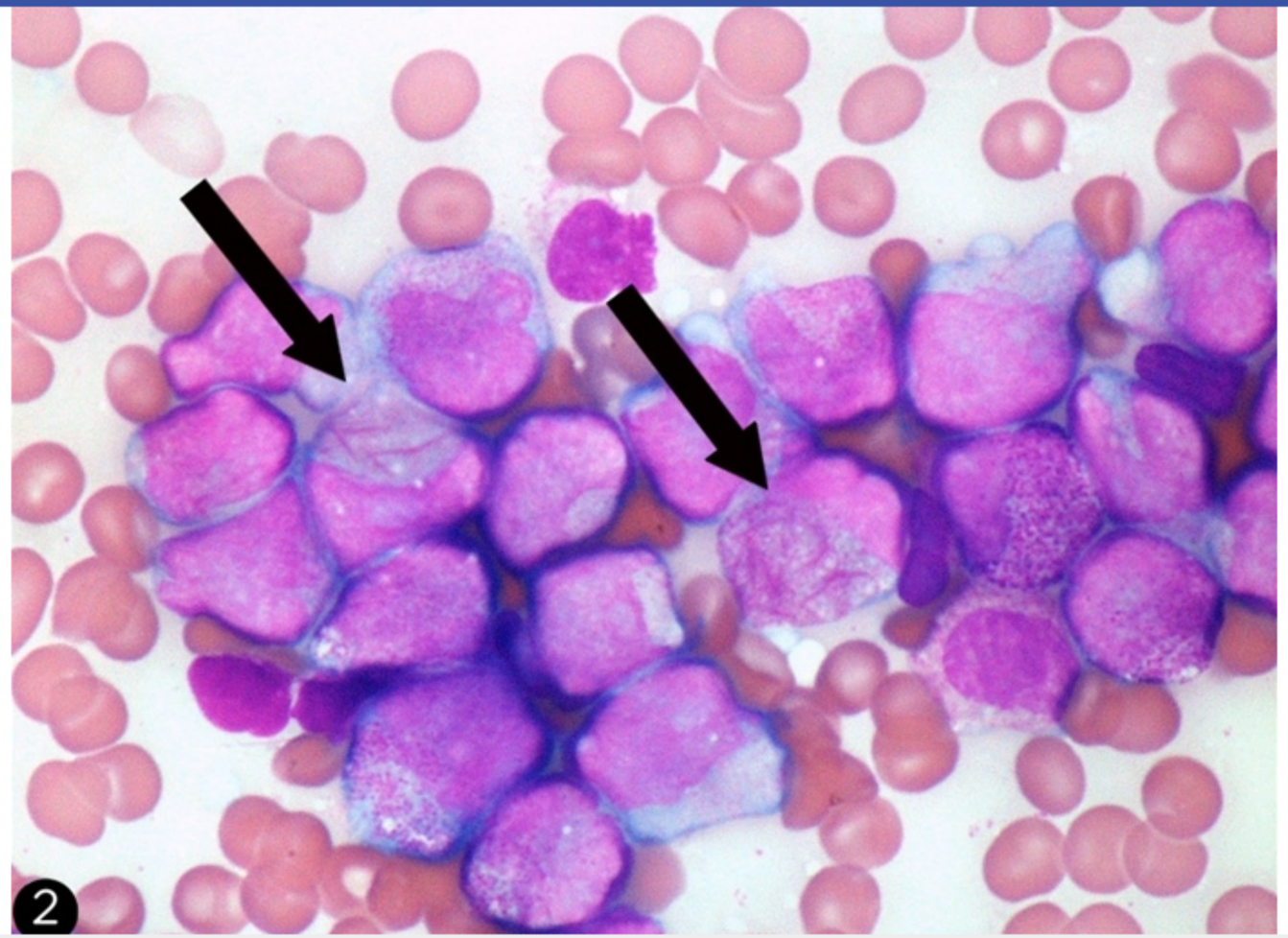

Zoom In | Zoom Out | Reset | Add To New Card | Existing Card

This patient, who has fever (suggesting infection and possibly low leukocyte count) and bruising/oozing from venipuncture sites (suggesting low

Exhibit Display

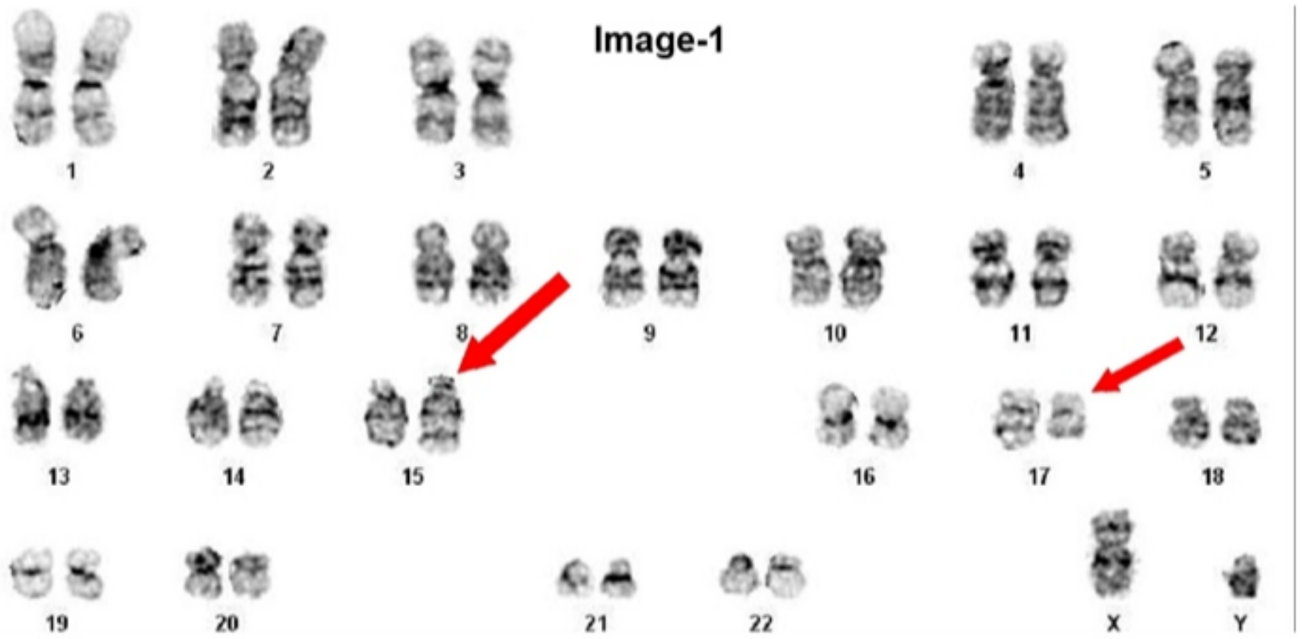

Zoom In | Zoom Out | Reset | Add To New Card | Existing Card

A 68-year-old man comes to the office due to an enlarging mole on his right forearm. The patient is a retired farmer and received a significant amount of sun exposure over the course of his life. On examination, he has a black-brown macular lesion on the dorsum of his right forearm measuring approximately 1 cm in diameter with an irregular border. Excisional biopsy is performed and histopathology reveals malignant melanoma. Immunohistochemical analysis indicates that the malignant cells have decreased integrin expression. These cells are most likely to exhibit poor adhesion to which of the following components of the extracellular matrix?

- A. Actin
- B. Fibronectin
- C. Hyaluronic acid
- D. Keratan sulfate
- E. Keratin

Submit

1
2
3
4
5
6
7
8
9
10
11
12
13
14
15
16
17
18
19
20
21
22
23
24
25
26
27
28
29
30

A 68-year-old man comes to the office due to an enlarging mole on his right forearm. The patient is a retired farmer and received a significant amount of sun exposure over the course of his life. On examination, he has a black-brown macular lesion on the dorsum of his right forearm measuring approximately 1 cm in diameter with an irregular border. Excisional biopsy is performed and histopathology reveals malignant melanoma. Immunohistochemical analysis indicates that the malignant cells have decreased integrin expression. These cells are most likely to exhibit poor adhesion to which of the following components of the extracellular matrix?

- A. Actin (12%)
- ✓ B. Fibronectin (48%)
- C. Hyaluronic acid (13%)
- D. Keratan sulfate (9%)
- E. Keratin (15%)

Omitted
Correct answer
B

48%
Answered correctly

02 secs
Time Spent

02/12/2020
Last Updated

Explanation

Integrin and fibronectin

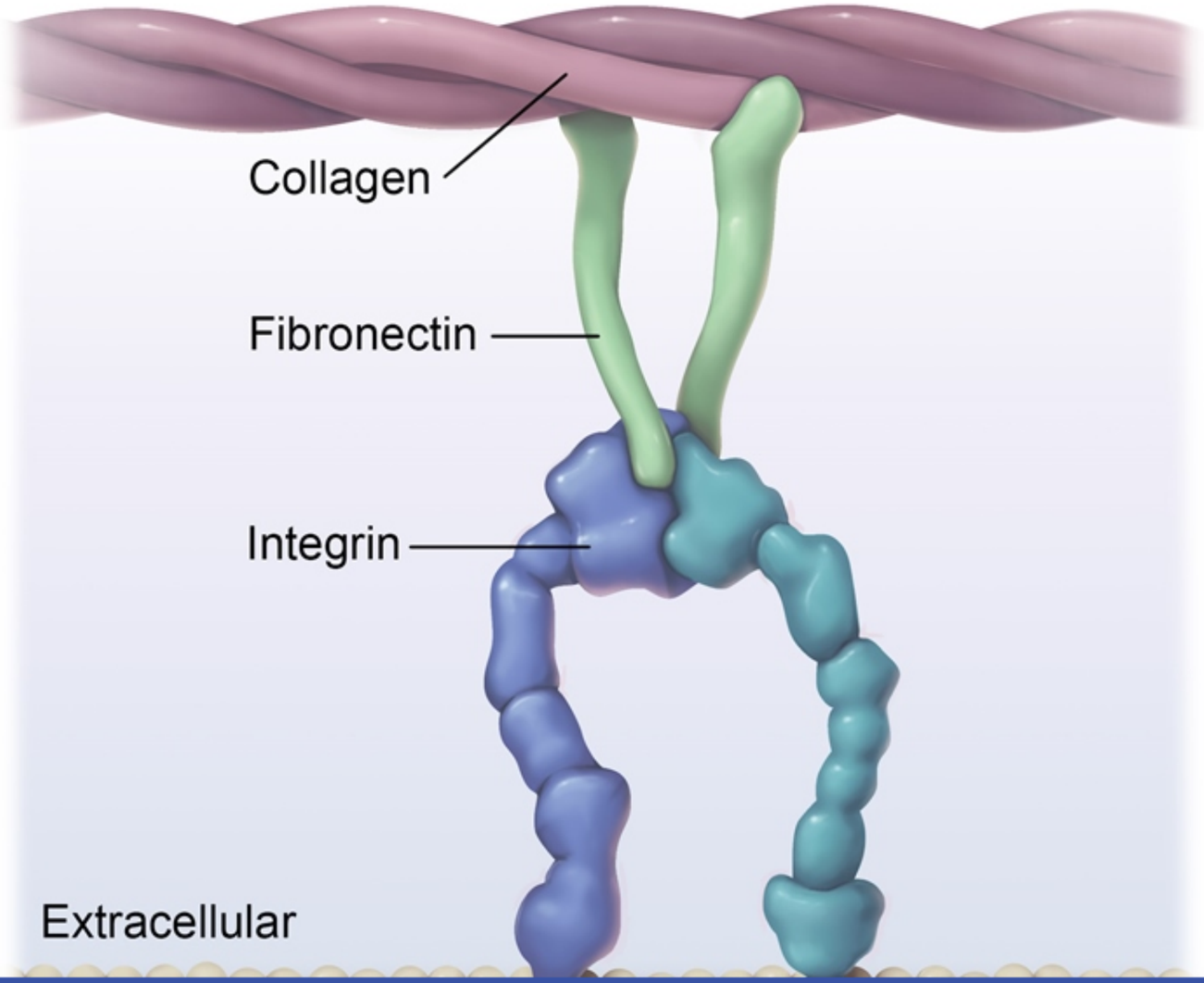

1
2
3
4
5
6
7
8
9
10
11
12
13
14
15
16
17
18
19
20
21
22
23
24
25
26
27
28
29
30

Actin

©UWorld

Cellular adhesion is the means by which one cell binds to another cell, surface, or matrix. The **integrins** are a family of transmembrane protein receptors that interact with the extracellular matrix by binding to specific proteins, including collagen, fibronectin, and laminin. Other adhesion molecule classes include the cadherins, selectins, and Ig superfamily members.

Fibronectins are large glycoproteins produced by fibroblasts and some epithelial cells. Fibronectin binds to integrins, matrix collagen, and glycosaminoglycans, serving as a mediator of cell adhesion and migration. Differential expression of integrin subtypes affects adhesion properties of individual cells, and correlates with **malignant behavior** in a number of tumors, including melanoma.

(Choices A and E) The intracellular domains of the integrins interact with a number of structural proteins, including microfilaments (actin) within the cytoplasm and intermediate filaments (keratin). However, the extracellular domains do not interact with these structures.

(Choices C and D) Hyaluronic acid is a glycosaminoglycan that contributes to water retention in the extracellular matrix, and determines the stiffness of the matrix. Keratan sulfate is a glycosaminoglycan in the extracellular matrix that may play a role in maintaining type I collagen fibril organization in a number of tissues (eg, cornea). However, neither of these is a ligand for integrins.

Educational objective:
Adhesion of cells to the extracellular matrix involves integrin-mediated binding to fibronectin, collagen, and laminin. Differential expression of integrin subtypes affects adhesion properties of individual cells, and has been found to correlate with malignant behavior in a number of tumors.

References

- Integrins: versatile receptors controlling melanocyte adhesion, migration, and proliferation.

Pathology	Hematology & Oncology	Cell adhesion molecules
Subject	System	Topic

Copyright © UWorld. All rights reserved.

1
2
3
4
5
6
7
8
9
10
11
12
13
14
15
16
17
18
19
20
21
22
23
24
25
26
27
28
29
30

A 7-year-old boy comes to the office for follow-up. A week ago, the patient began having episodes of bloody diarrhea, and these have since resolved. Currently, laboratory studies show acute renal failure. A complete blood count shows anemia and thrombocytopenia. Coagulation studies are within normal limits. His peripheral blood smear is shown in the image below.

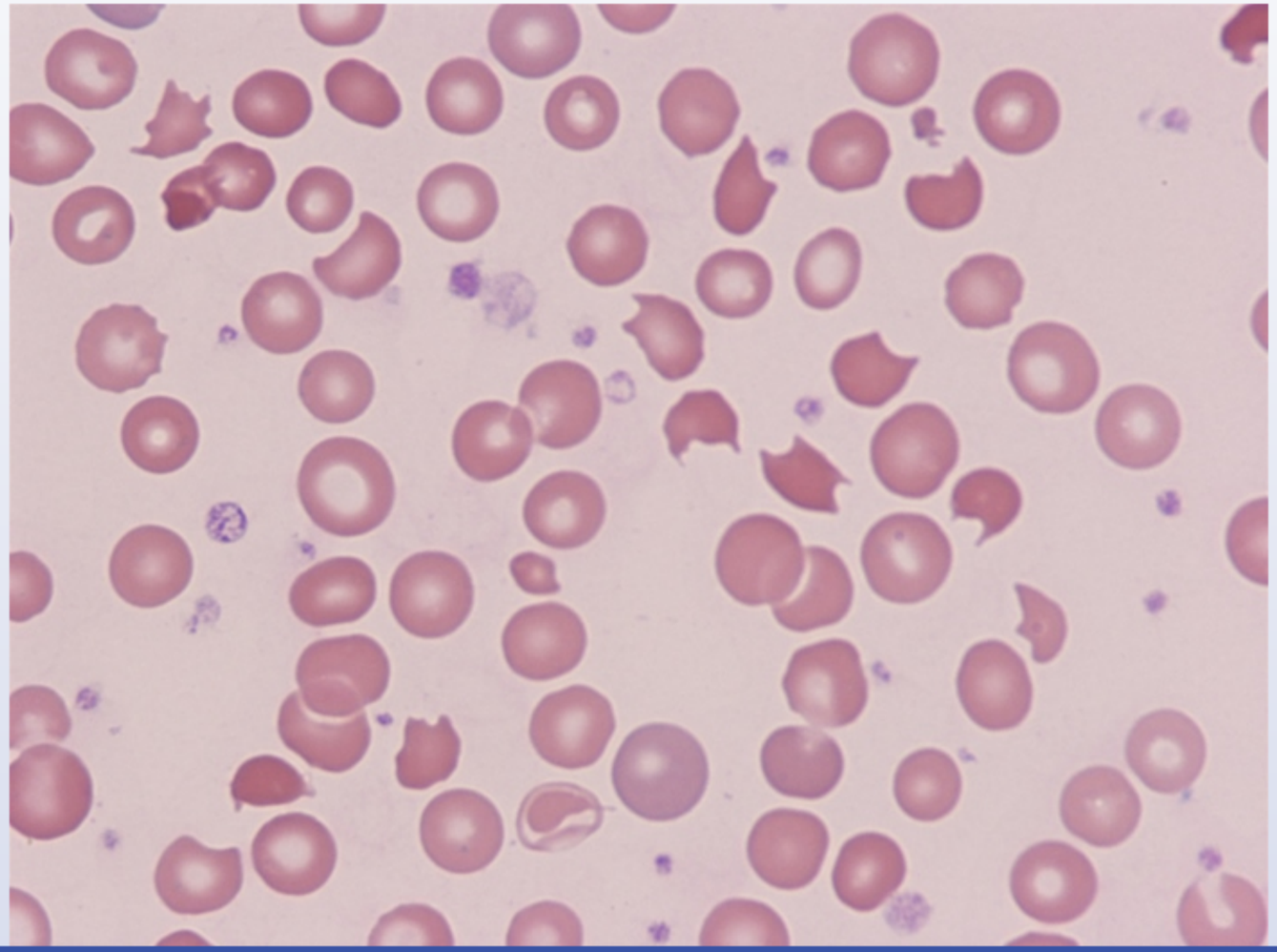

1
2
3
4
5
6
7
8
9
10
11
12
13
14
15
16
17
18
19
20
21
22
23
24
25
26
27
28
29
30

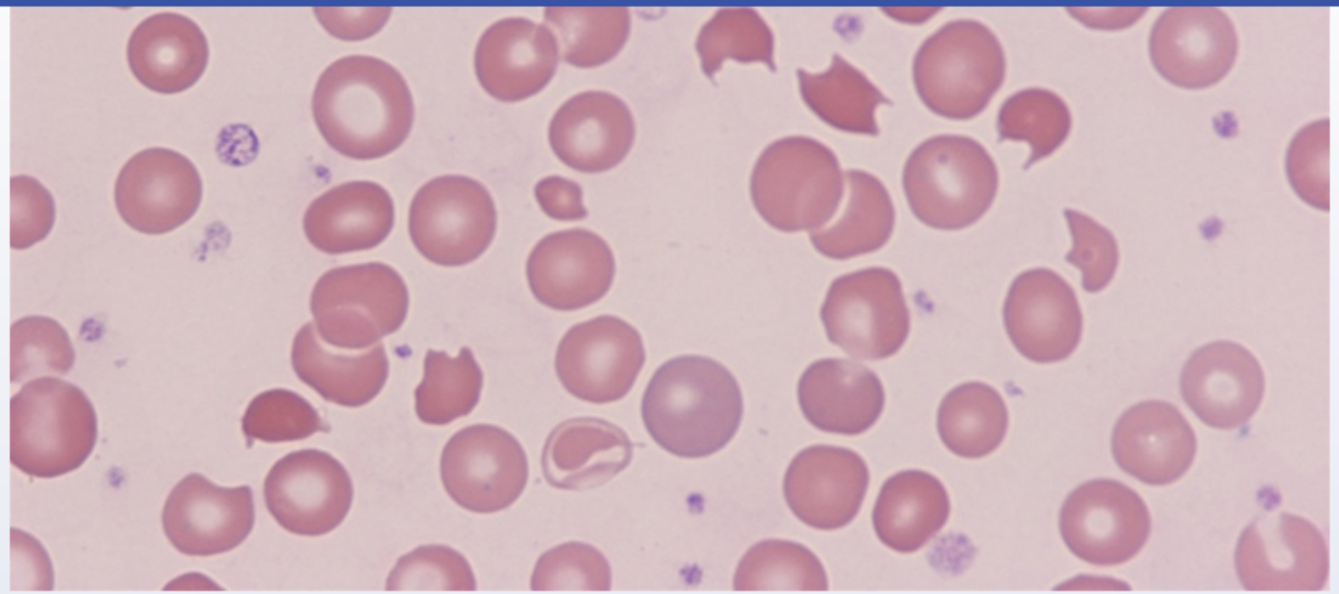

Which of the following is the most likely cause of this patient's anemia?

A. Autoimmune hemolytic anemia from a diarrheal organism

B. Erythropoietin deficiency from renal failure

C. Hemolytic anemia due to oxidative stress

D. Leukoerythroblastosis due to marrow fibrosis

E. Microangiopathic hemolytic anemia

Submit

1
2
3
4
5
6
7
8
9
10
11
12
13
14
15
16
17
18
19
20
21
22
23
24
25
26
27
28
29
30

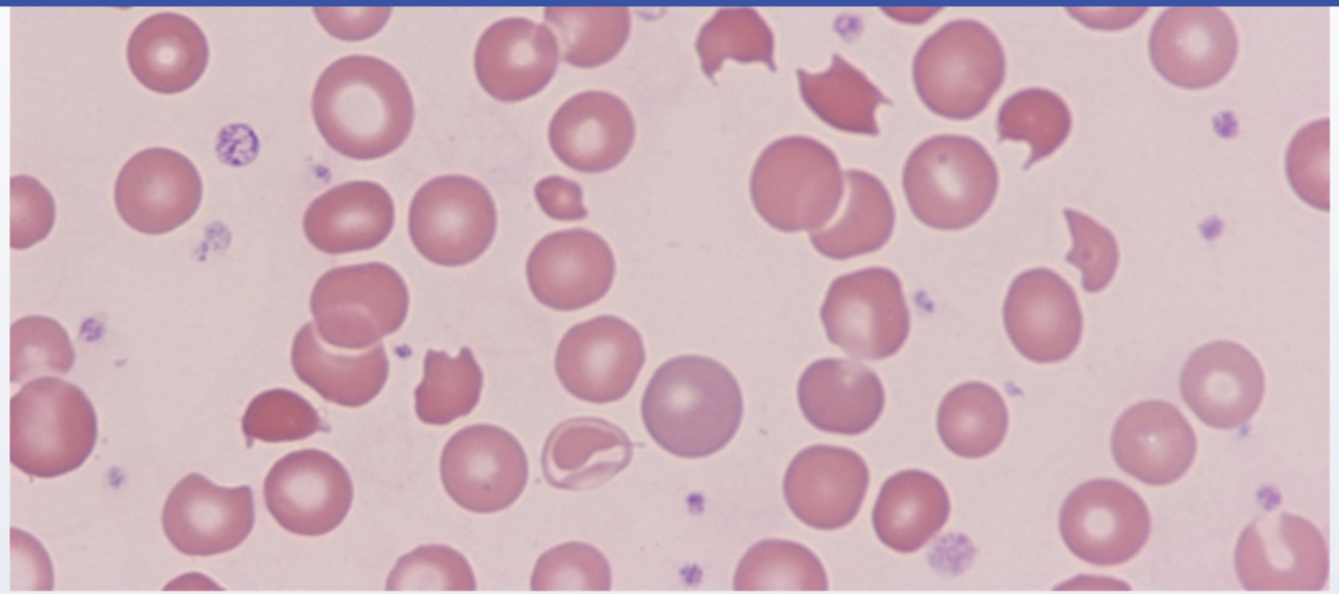

Which of the following is the most likely cause of this patient's anemia?

A. Autoimmune hemolytic anemia from a diarrheal organism (23%)

B. Erythropoietin deficiency from renal failure (1%)

C. Hemolytic anemia due to oxidative stress (12%)

D. Leukoerythroblastosis due to marrow fibrosis (0%)

✓ E. Microangiopathic hemolytic anemia (61%)

Omitted
Correct answer

61%
Answered correctly

03 secs
Time Spent

07/07/2020
Last Updated

1
2
3
4
5
6
7
8
9
10
11
12
13
14
15
16
17
18
19
20
21
22
23
24
25
26
27
28
29
30

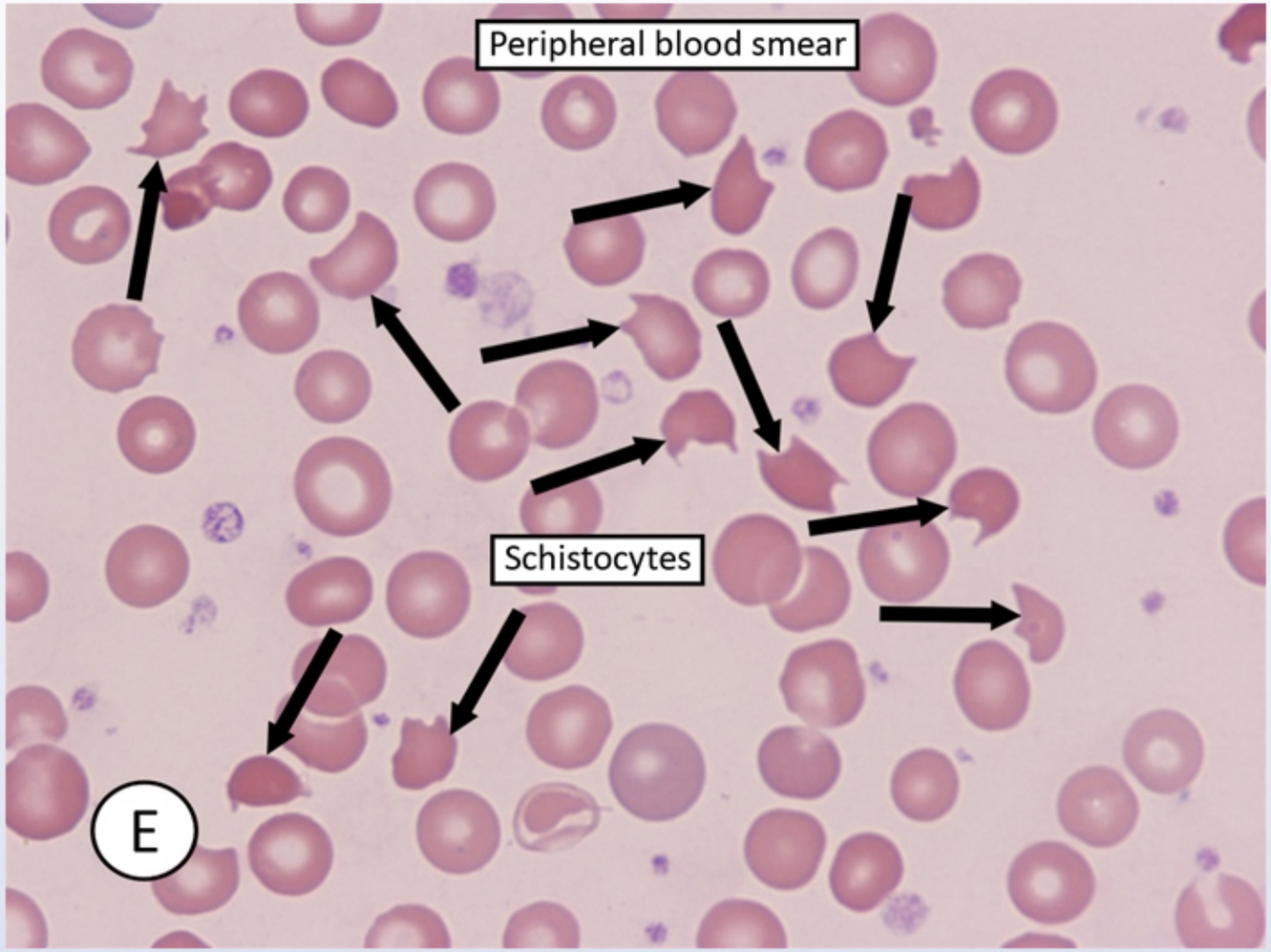

The clinical presentation and the peripheral blood smear shown are typical of hemolytic uremic syndrome (HUS). Most cases of childhood HUS are preceded by bloody diarrhea, often caused by Shiga-like toxin released from enterohemorrhagic *Escherichia coli* (particularly strain O157:H7). Undercooked ground beef is a common cause of HUS.

1
2
3
4
5
6
7
8
9
10
11
12
13
14
15
16
17
18
19
20
21
22
23
24
25
26
27
28
29
30

The clinical presentation and the peripheral blood smear shown are typical of hemolytic uremic syndrome (HUS). Most cases of childhood HUS are preceded by bloody diarrhea, often caused by Shiga-like toxin released from enterohemorrhagic *Escherichia coli* (particularly strain O157:H7). Undercooked ground beef is a common cause of HUS.

The smear contains classic **schistocytes** (fragmented red cells) and few platelets. Schistocytes are diagnostic of a traumatic mechanism and indicate either **microangiopathic hemolytic anemia** (eg, HUS, thrombotic thrombocytopenic purpura [TTP], disseminated intravascular coagulation [DIC], malignant hypertension, metastatic carcinoma) or mechanical damage (eg, prosthetic valve, severely calcified valves). HUS and TTP lie on a spectrum. Unlike in DIC, the coagulation system is not activated in HUS-TTP; therefore, coagulation studies (prothrombin time and partial thromboplastin time) are normal, as seen with this patient.

(Choice A) Autoimmune hemolytic anemia (AIHA) is due to an altered immune response and the production of antibodies against erythrocytes. AIHA can occur following infections with *Mycoplasma pneumoniae* and Epstein-Barr virus but not usually following a diarrheal illness. In addition, thrombocytopenia and renal failure are not associated with AIHA.

(Choice B) Erythropoietin deficiency from renal failure results in normocytic, normochromic anemia; neither schistocytes nor decreased platelets are present. Erythropoietin deficiency is usually seen in chronic renal failure; this patient has acute renal failure.

(Choice C) Glucose-6-phosphate dehydrogenase (G6PD) deficiency anemia causes hemolytic anemia due to oxidative stress. It is not associated with thrombocytopenia or renal failure. The peripheral smear usually shows "bite cells."

(Choice D) Leukoerythroblastic peripheral smears demonstrate nucleated red cells and immature white cells. This is usually seen when the marrow is replaced with fibrosis (or metastatic cancer). The red cells can be squeezed while passing through these fibrous strands and appear on the peripheral smear as characteristic teardrop cells.

Educational objective:
Schistocytes suggest microangiopathic hemolytic anemia (eg, hemolytic-uremic syndrome [HUS], thrombotic thrombocytopenic purpura [TTP], disseminated intravascular coagulation [DIC]) or mechanical damage [eg, prosthetic valve]). In childhood, HUS is often preceded by bloody diarrhea. Coagulation studies (prothrombin time and partial thromboplastin time) are normal in HUS-TTP but abnormal in DIC.

References

coagulation [DIC], malignant hypertension, metastatic carcinoma) or mechanical damage (eg, prosthetic valve, severely calcified valves). HUS and TTP lie on a spectrum. Unlike in DIC, the coagulation system is not activated in HUS-TTP; therefore, coagulation studies (prothrombin time and partial thromboplastin time) are normal, as seen with this patient.

(Choice A) Autoimmune hemolytic anemia (AIHA) is due to an altered immune response and the production of antibodies against erythrocytes. AIHA can occur following infections with *Mycoplasma pneumoniae* and Epstein-Barr virus but not usually following a diarrheal illness. In addition, thrombocytopenia and renal failure are not associated with AIHA.

(Choice B) Erythropoietin deficiency from renal failure results in normocytic, normochromic anemia; neither schistocytes nor decreased platelets are present. Erythropoietin deficiency is usually seen in chronic renal failure; this patient has acute renal failure.

(Choice C) Glucose-6-phosphate dehydrogenase (G6PD) deficiency anemia causes hemolytic anemia due to oxidative stress. It is not associated with thrombocytopenia or renal failure. The peripheral smear usually shows "bite cells."

(Choice D) Leukoerythroblastic peripheral smears demonstrate nucleated red cells and immature white cells. This is usually seen when the marrow is replaced with fibrosis (or metastatic cancer). The red cells can be squeezed while passing through these fibrous strands and appear on the peripheral smear as characteristic teardrop cells.

Educational objective:
Schistocytes suggest microangiopathic hemolytic anemia (eg, hemolytic-uremic syndrome [HUS], thrombotic thrombocytopenic purpura [TTP], disseminated intravascular coagulation [DIC]) or mechanical damage [eg, prosthetic valve]). In childhood, HUS is often preceded by bloody diarrhea. Coagulation studies (prothrombin time and partial thromboplastin time) are normal in HUS-TTP but abnormal in DIC.

References

- Thrombotic microangiopathies: thrombotic thrombocytopenic purpura/hemolytic uremic syndrome.

Pathology	Hematology & Oncology	Hemolytic uremic syndrome
Subject	System	Topic

Copyright © UWorld. All rights reserved.

coagulation [DIC], malignant hypertension, metastatic carcinoma) or mechanical damage (eg, prosthetic valve, severely calcified valves). HUS

Exhibit Display

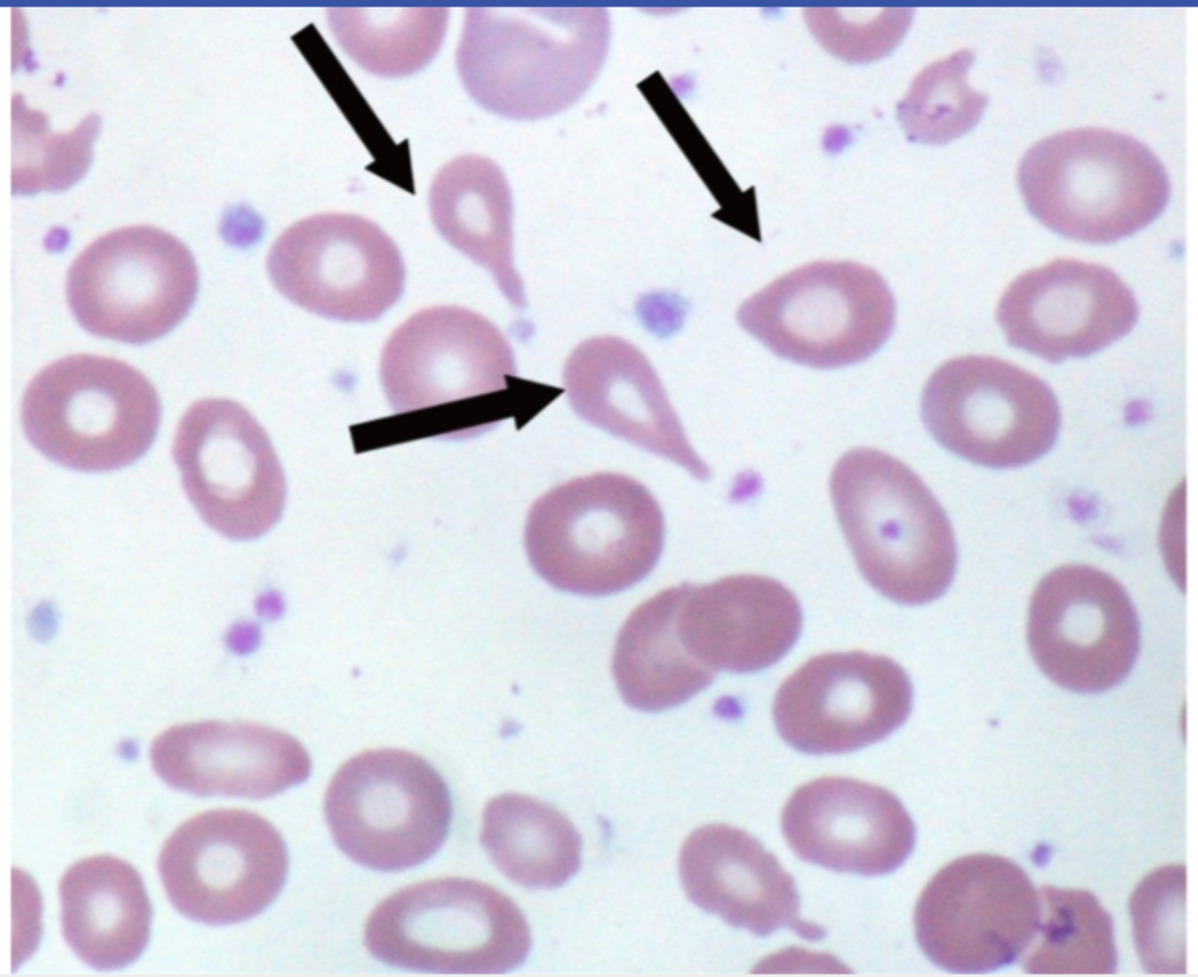

Zoom In | Zoom Out | Reset | Add To New Card | Existing Card

1
2
3
4
5
6
7
8
9
10
11
12
13
14
15
16
17
18
19
20
21
22
23
24
25
26
27
28
29
30

A 70-year-old female presents to your office complaining of easy fatigability, exertional dyspnea and weight loss. She also complains of frequent falls. Physical examination reveals symmetrically decreased vibratory sensation to the lower extremities. Her hemoglobin is 7.8 g/dL and a peripheral blood smear shows hypersegmented neutrophils. Which of the following is the best treatment for this patient?

A. Iron preparations
B. Vitamin B12
C. Pyridoxine
D. Vitamin C
E. Folic acid
F. Erythropoietin
G. Filgrastim
H. Interleukin-2
I. Antithymocyte globulin

Submit

1
2
3
4
5
6
7
8
9
10
11
12
13
14
15
16
17
18
19
20
21
22
23
24
25
26
27
28
29
30

A 70-year-old female presents to your office complaining of easy fatigability, exertional dyspnea and weight loss. She also complains of frequent falls. Physical examination reveals symmetrically decreased vibratory sensation to the lower extremities. Her hemoglobin is 7.8 g/dL and a peripheral blood smear shows hypersegmented neutrophils. Which of the following is the best treatment for this patient?

- A. Iron preparations (1%)
- ✓ B. Vitamin B12 (90%)
- C. Pyridoxine (1%)
- D. Vitamin C (0%)
- E. Folic acid (3%)
- F. Erythropoietin (1%)
- G. Filgrastim (0%)
- H. Interleukin-2 (0%)
- I. Antithymocyte globulin (0%)

Omitted
Correct answer
B

90%
Answered correctly

02 secs
Time Spent

02/03/2020
Last Updated

Explanation

1
2
3
4
5
6
7
8
9
10
11
12
13
14
15
16
17
18
19
20
21
22
23
24
25
26
27
28
29
30

Deficiencies of folic acid and vitamin B12 are the most important causes of megaloblastic anemia. Both of these vitamins are required for DNA synthesis in erythropoiesis. When there is a deficiency of either of these vitamins, cell division is delayed, though the cytoplasm develops normally. Thus, the cells enlarge (megaloblasts) but do not divide. The bone marrow is hypercellular in megaloblastic anemia, but the megaloblastic erythroid precursor cells are rapidly destroyed in the bone marrow and few differentiated large RBCs are released into the circulation. In severe megaloblastic anemia, 90% of erythroid precursors are destroyed without ever entering the circulation.

Vitamin B12 and folic acid deficiencies cause similar hematological pictures. However, neurological dysfunction is only seen in patients with vitamin B12 deficiency. This is because B12 deficiency also causes axonal demyelination and degeneration. In late disease, the neurological dysfunction may be irreversible. The main sites of neurological involvement include the peripheral nerves, spinal cord (posterior and lateral columns), and the cerebrum. Decreased vibratory and position sense are early signs of vitamin B12 deficiency. Patients experience ataxia and recurrent falls because of compromised proprioception. Importantly, neurologic abnormalities can occur in vitamin B12 deficiency in the absence of frank anemia. Treating megaloblastic anemia due to vitamin B12 deficiency with folate alone could worsen the neurological dysfunction.

An RBC mean corpuscular volume (MCV) of more than 100 fL is suggestive of megaloblastic anemia. However, RBC macrocytosis can also occur in liver disease, hypothyroidism, and alcoholic liver disease. MCVs greater than 110 fL are typically seen only with vitamin B12 and folic acid anemias. On peripheral blood smear, there is macrocytosis (large RBCs), hypersegmented neutrophils, and large bizarrely shaped platelets. The presence of even a single neutrophil with more than 6 lobes should raise the suspicion of megaloblastic anemia.

The medications listed in the other answer choices are not used for the treatment of megaloblastic anemia.

Educational Objective:
Vitamin B12 and folic acid deficiencies cause similar hematological pictures. However, neurological dysfunction is only seen in patients with vitamin B12 deficiency. If megaloblastic anemia due to vitamin B12 deficiency is mistakenly treated with folate alone, the neurologic dysfunction can worsen.

Pathology	Hematology & Oncology	Anemia
Subject	System	Topic

Copyright © UWorld. All rights reserved.

A 22-year-old woman comes to the office due to worsening dyspnea and heart pounding with exercise for the last week. She has no chronic medical conditions but reports aches and pains over the past several weeks. The patient takes ibuprofen as needed but no other medications. Temperature is 37.2 C (99 F), blood pressure is 138/86 mm Hg, and pulse is 90/min. BMI is 18 kg/m^2. Physical examination shows an erythematous rash in sun-exposed regions. The lungs are clear to auscultation. A midsystolic click and systolic murmur are heard best at the apex without radiation. There is mild tenderness of joints. Laboratory results are as follows:

Hemoglobin	7.8 g/dL
Reticulocytes	6%
Platelets	205,000/mm^3
Leukocytes	11,200/mm^3
Creatinine	1.4 mg/dL

Which of the following is the most likely cause of this patient's hematologic findings?

- A. Bone marrow suppression
- B. Extravascular hemolysis
- C. Intrinsic factor antibodies
- D. Thrombotic microangiopathy
- E. Traumatic intravascular hemolysis

Submit

A 22-year-old woman comes to the office due to worsening dyspnea and heart pounding with exercise for the last week. She has no chronic medical conditions but reports aches and pains over the past several weeks. The patient takes ibuprofen as needed but no other medications. Temperature is 37.2 C (99 F), blood pressure is 138/86 mm Hg, and pulse is 90/min. BMI is 18 kg/m^2. Physical examination shows an erythematous rash in sun-exposed regions. The lungs are clear to auscultation. A midsystolic click and systolic murmur are heard best at the apex without radiation. There is mild tenderness of joints. Laboratory results are as follows:

Hemoglobin	7.8 g/dL
Reticulocytes	6%
Platelets	205,000/mm^3
Leukocytes	11,200/mm^3
Creatinine	1.4 mg/dL

Which of the following is the most likely cause of this patient's hematologic findings?

- A. Bone marrow suppression (3%)
- ✓ B. Extravascular hemolysis (45%)
- C. Intrinsic factor antibodies (7%)
- D. Thrombotic microangiopathy (17%)
- E. Traumatic intravascular hemolysis (26%)

Omitted
Correct answer

45%
Answered correctly

02 secs
Time Spent

05/14/2020
Last Updated

1
2
3
4
5
6
7
8
9
10
11
12
13
14
15
16
17
18
19
20
21
22
23
24
25
26
27
28
29
30

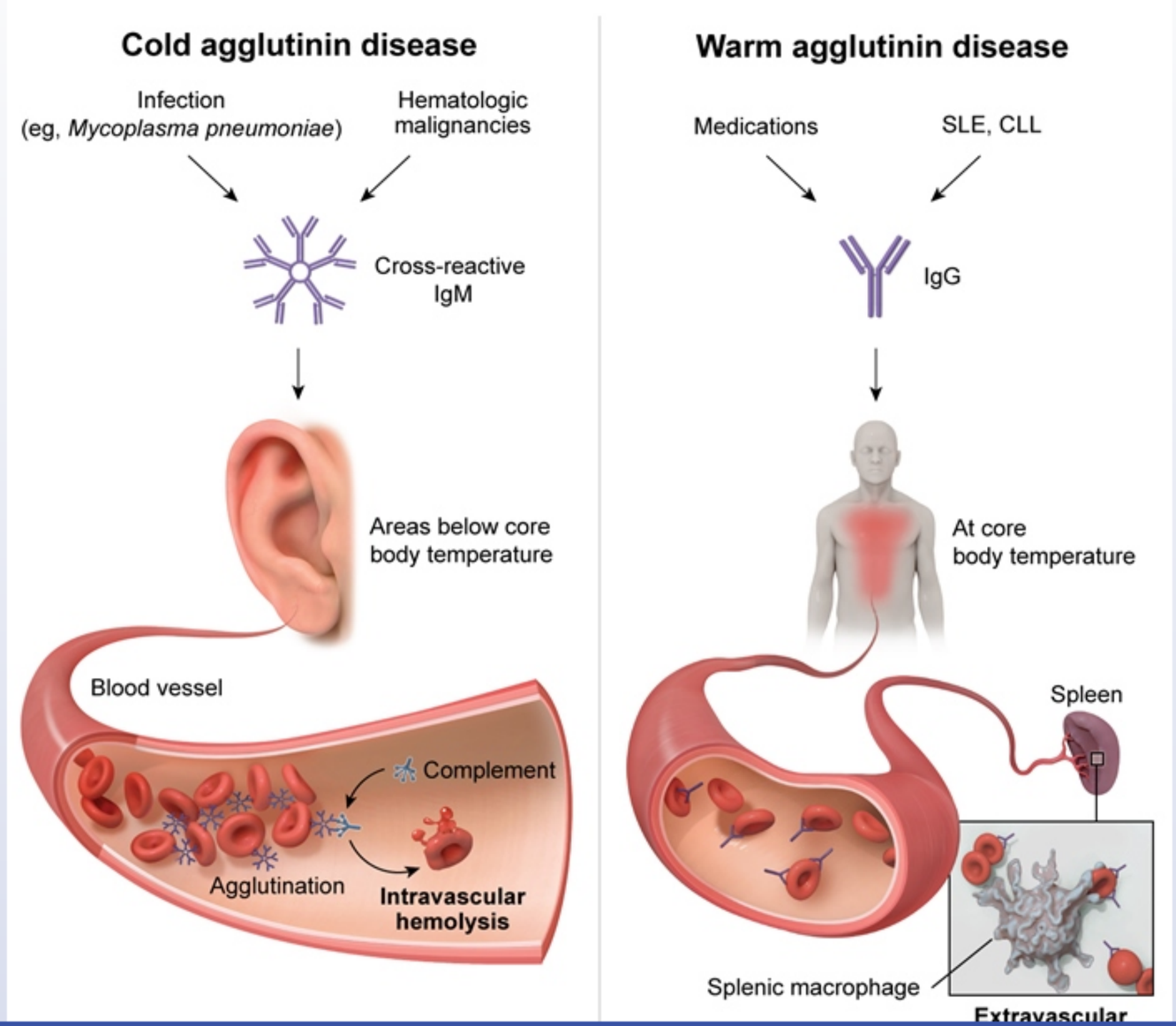

©UWorld

This patient with dyspnea and heart pounding with exercise has **symptomatic anemia**. Her other findings, including the presence of joint pain, a photosensitive rash, and mild renal insufficiency, raise suspicion for **systemic lupus erythematosus** (SLE), an autoimmune disease primarily seen in **young women**. SLE frequently causes anemia due to a combination of factors, including chronic inflammation (anemia of chronic disease), gastrointestinal serositis (iron deficiency from bleeding), and/or **autoimmune hemolytic anemia** (AIHA).

Approximately 10% of patients with SLE develop AIHA due to immune dysregulation, which results in the formation of **IgG autoantibodies** against the erythrocyte membrane. Erythrocytes coated with IgG are subsequently identified by the Fc-receptor on **splenic macrophages** and partially or wholly phagocytized, leading to **extravascular hemolysis**. Laboratory assessment typically reveals **elevated reticulocyte count** (ie, reticulocytosis) because interstitial fibroblasts in the kidney sense tissue hypoxia and increase the release of erythropoietin; this drives the bone marrow to increase erythrocytosis, leading to the presence of immature red cells in the peripheral blood (normoblasts, reticulocytes).

(Choices A and C) The presence of significant reticulocytosis (eg, >4-5%) rules out causes of anemia associated with an impaired bone marrow response, including bone marrow suppression from cancer or infection (eg, parvovirus), anemia of chronic disease (cytokine-mediated retention of iron), and vitamin deficiency (eg, vitamin B_{12} deficiency from intrinsic factor antibodies, iron deficiency).

(Choice D) A normal platelet count effectively rules out anemia due to a microangiopathic process associated with intravascular platelet consumption (eg, thrombotic microangiopathy).

(Choice E) Although traumatic intravascular hemolysis can occur with a mechanical heart valve or severe aortic stenosis, it is uncommon in otherwise healthy young individuals. Furthermore, this patient's heart murmur is most consistent with mitral valve prolapse, which is common in patients with SLE but rarely causes traumatic hemolysis.

Educational objective:
Anemia with an elevated reticulocyte count (ie, reticulocytosis) indicates that the bone marrow is responding appropriately to the anemia by generating new erythrocytes. Reticulocytosis is commonly seen in patients with hemolysis or acute bleeding. Many other causes of anemia are associated with low reticulocyte count, including bone marrow suppression (eg, parvovirus), iron deficiency anemia, vitamin B_{12}/folate deficiency, and anemia of chronic disease.

Pathology Hematology & Oncology Hemolytic anemia

seen in **young women**. SLE frequently causes anemia due to a combination of factors, including chronic inflammation (anemia of chronic disease), gastrointestinal serositis (iron deficiency from bleeding), and/or **autoimmune hemolytic anemia** (AIHA).

Approximately 10% of patients with SLE develop AIHA due to immune dysregulation, which results in the formation of **IgG autoantibodies** against the erythrocyte membrane. Erythrocytes coated with IgG are subsequently identified by the Fc-receptor on **splenic macrophages** and partially or wholly phagocytized, leading to **extravascular hemolysis**. Laboratory assessment typically reveals **elevated reticulocyte count** (ie, reticulocytosis) because interstitial fibroblasts in the kidney sense tissue hypoxia and increase the release of erythropoietin; this drives the bone marrow to increase erythrocytosis, leading to the presence of immature red cells in the peripheral blood (normoblasts, reticulocytes).

(Choices A and C) The presence of significant reticulocytosis (eg, >4-5%) rules out causes of anemia associated with an impaired bone marrow response, including bone marrow suppression from cancer or infection (eg, parvovirus), anemia of chronic disease (cytokine-mediated retention of iron), and vitamin deficiency (eg, vitamin B_{12} deficiency from intrinsic factor antibodies, iron deficiency).

(Choice D) A normal platelet count effectively rules out anemia due to a microangiopathic process associated with intravascular platelet consumption (eg, thrombotic microangiopathy).

(Choice E) Although traumatic intravascular hemolysis can occur with a mechanical heart valve or severe aortic stenosis, it is uncommon in otherwise healthy young individuals. Furthermore, this patient's heart murmur is most consistent with mitral valve prolapse, which is common in patients with SLE but rarely causes traumatic hemolysis.

Educational objective:
Anemia with an elevated reticulocyte count (ie, reticulocytosis) indicates that the bone marrow is responding appropriately to the anemia by generating new erythrocytes. Reticulocytosis is commonly seen in patients with hemolysis or acute bleeding. Many other causes of anemia are associated with low reticulocyte count, including bone marrow suppression (eg, parvovirus), iron deficiency anemia, vitamin B_{12}/folate deficiency, and anemia of chronic disease.

Pathology	Hematology & Oncology	Hemolytic anemia
Subject	System	Topic

Copyright © UWorld. All rights reserved.

1
2
3
4
5
6
7
8
9
10
11
12
13
14
15
16
17
18
19
20
21
22
23
24
25
26
27
28
29
30

A 26-year-old woman is being treated for glomerulonephritis, photosensitive skin rash, and arthralgias. Rapid plasma reagin (RPR) test is repeatedly positive in this patient despite negative *Treponema pallidum* enzyme immunoassay (TP-EIA) testing. Coagulation study results are as follows:

Bleeding time	Normal
Activated partial thromboplastin time	Prolonged
Prothrombin time	Normal
Platelets	240,000/μL

This patient is at greatest risk for which of the following complications?

A. Esophageal dysmotility
B. Menorrhagia
C. Painful hemarthroses
D. Recurrent miscarriages
E. Sclerodactyly
F. Tabes dorsalis

Submit

1
2
3
4
5
6
7
8
9
10
11
12
13
14
15
16
17
18
19
20
21
22
23
24
25
26
27
28
29
30

A 26-year-old woman is being treated for glomerulonephritis, photosensitive skin rash, and arthralgias. Rapid plasma reagin (RPR) test is repeatedly positive in this patient despite negative *Treponema pallidum* enzyme immunoassay (TP-EIA) testing. Coagulation study results are as follows:

Bleeding time	Normal
Activated partial thromboplastin time	Prolonged
Prothrombin time	Normal
Platelets	240,000/μL

This patient is at greatest risk for which of the following complications?

A. Esophageal dysmotility (3%)
B. Menorrhagia (8%)
C. Painful hemarthroses (18%)
✓ D. Recurrent miscarriages (58%)
E. Sclerodactyly (4%)
F. Tabes dorsalis (6%)

Omitted
Correct answer
D

58%
Answered correctly

02 secs
Time Spent

06/20/2020
Last Updated

Antiphospholipid antibody syndrome	
Clinical features	**Venous or arterial thromboembolic disease** • Deep venous thrombosis • Pulmonary embolism • Ischemic stroke/transient ischemic attack **Adverse pregnancy outcomes** • Unexplained embryonic or fetal loss • Premature birth due to placental insufficiency or preeclampsia

Laboratory findings	• **Lupus anticoagulant** effect: Paradoxical **aPTT prolongation** not reversed on plasma mixing studies
	
	• Presence of specific antiphospholipid antibodies
	  ○ **Anticardiolipin** antibody
	  ○ **Anti-beta2-glycoprotein-I** antibody

©UWorld

Glomerulonephritis, a photosensitive skin rash, and arthralgia in a young woman are suggestive of systemic lupus erythematosus (SLE). This patient's prolonged activated partial thromboplastin time (aPTT) and false-positive rapid plasma reagin (RPR) test further suggest the presence of circulating **antiphospholipid antibodies**. Although antiphospholipid antibodies cause **aPTT prolongation** in vitro, they act in vivo to produce a **hypercoagulable state** due to activation of phospholipid-dependent coagulation pathways. These antibodies can also cause **false-positive results** on nontreponemal serologic syphilis tests (eg, RPR and VDRL) by reacting with cardiolipin (the dominant antigen used in these tests).

Antiphospholipid antibody syndrome (APS) is a disorder characterized by the presence of antiphospholipid antibodies in the setting of venous or arterial thromboembolism and/or recurrent pregnancy loss. APS may be a primary disorder or occur secondary to other autoimmune diseases such as SLE. Although antiphospholipid antibodies are present in 10%-30% of patients with SLE, not all exhibit the clinical syndrome.

©UWorld

Glomerulonephritis, a photosensitive skin rash, and arthralgia in a young woman are suggestive of systemic lupus erythematosus (SLE). This patient's prolonged activated partial thromboplastin time (aPTT) and false-positive rapid plasma reagin (RPR) test further suggest the presence of circulating **antiphospholipid antibodies**. Although antiphospholipid antibodies cause **aPTT prolongation** in vitro, they act in vivo to produce a **hypercoagulable state** due to activation of phospholipid-dependent coagulation pathways. These antibodies can also cause **false-positive results** on nontreponemal serologic syphilis tests (eg, RPR and VDRL) by reacting with cardiolipin (the dominant antigen used in these tests).

Antiphospholipid antibody syndrome (APS) is a disorder characterized by the presence of antiphospholipid antibodies in the setting of venous or arterial thromboembolism and/or recurrent pregnancy loss. APS may be a primary disorder or occur secondary to other autoimmune diseases such as SLE. Although antiphospholipid antibodies are present in 10%-30% of patients with SLE, not all exhibit the clinical syndrome.

(Choices A and E) SLE is less likely than other connective tissue diseases such as scleroderma or mixed connective tissue disease to involve the esophagus. Sclerodactyly is also more typical of the CREST syndrome/scleroderma.

(Choices B and C) Painful hemarthroses and/or menorrhagia would be indicative of a hypocoagulable state. Although antiphospholipid antibodies can prolong the aPTT (and sometimes prothrombin time), patients with APS experience thromboembolic events, not increased bleeding.

(Choice F) Tabes dorsalis is a manifestation of tertiary syphilis that results in sensory ataxia. The inability to confirm syphilis screening tests with more specific treponemal tests such as *Treponema pallidum* enzyme immunoassay (TP-EIA) or fluorescent treponema antibody absorption test (FTA-ABS) argues against a diagnosis of syphilis.

Educational objective:
Glomerulonephritis, a photosensitive skin rash, and arthralgias in a young woman are suggestive of systemic lupus erythematosus (SLE). Up to 30% of patients with SLE have antiphospholipid antibodies, which can cause paradoxical aPTT prolongation and a false-positive RPR/VDRL. Patients with antiphospholipid antibodies are at risk for venous and arterial thromboembolism and unexplained, recurrent pregnancy loss.

Pathology	Hematology & Oncology	Antiphospholipid syndrome
Subject	System	Topic

©UWorld

Glomerulonephritis, a ph
patient's prolonged activ
circulating **antiphosphol**
hypercoagulable state
results on nontreponem

Antiphospholipid antib
or arterial thromboembol
such as SLE. Although a

(Choices A and E) SLE
the esophagus. Sclerod

(Choices B and C) Pair
antibodies can prolong th
bleeding.

(Choice F) Tabes dorsa
more specific treponema
(FTA-ABS) argues again

Educational objective:
Glomerulonephritis, a ph
30% of patients with SLE
Patients with antiphosph

Pathology — Subject
Hematology & Oncology — System
Antiphospholipid syndrome — Topic

Exhibit Display

Manifestations of systemic lupus erythematosus	
Clinical symptoms	• Constitutional: fever, fatigue & weight loss • Symmetric, migratory arthritis • Skin: butterfly rash & photosensitivity • Serositis: pleurisy, pericarditis & peritonitis • Thromboembolic events (due to vasculitis & antiphospholipid antibodies) • Neurologic: cognitive dysfunction & seizures

Laboratory findings	• Hemolytic anemia, thrombocytopenia & leukopenia
	• Hypocomplementemia (C3 & C4)
	• Antibodies:
	  ◦ ANA (sensitive)
	  ◦ Anti-dsDNA & anti-Sm (specific)
	• Renal involvement: proteinuria & elevated creatinine

ANA = antinuclear antibodies; **dsDNA** = double-stranded DNA.

Add To New Card | Existing Card

1
2
3
4
5
6
7
8
9
10
11
12
13
14
15
16
17
18
19
20
21
22
23
24
25
26
27
28
29
30

A 9-year-old girl is brought to the emergency department due to prolonged epistaxis. The girl says that she picked her nose immediately before the bleeding started. Her parents decided to bring her to the emergency department after the epistaxis persisted for 20 minutes despite constant compression of the nasal alae. The patient has had frequent nosebleeds that often last >10 minutes. Her family history is significant for a grandfather who had an unspecified bleeding disorder. Given the history of prolonged, recurrent nosebleeds, laboratory tests are ordered, and results are as follows:

Hematocrit	43%
Bleeding time	prolonged
Partial thromboplastin time (PTT)	prolonged
Prothrombin time (PT)	normal
Thrombin time (TT)	normal
D-dimer	normal

Which of the following is the most likely diagnosis?

A. Disseminated intravascular coagulopathy
B. Dysfibrinogenemia
C. Factor XIII deficiency
D. Hemophilia A
E. Hemophilia B
F. Vitamin K deficiency
G. von Willebrand disease

1
2
3
4
5
6
7
8
9
10
11
12
13
14
15
16
17
18
19
20
21
22
23
24
25
26
27
28
29
30

results are as follows:

Hematocrit	43%
Bleeding time	prolonged
Partial thromboplastin time (PTT)	prolonged
Prothrombin time (PT)	normal
Thrombin time (TT)	normal
D-dimer	normal

Which of the following is the most likely diagnosis?

- A. Disseminated intravascular coagulopathy
- B. Dysfibrinogenemia
- C. Factor XIII deficiency
- D. Hemophilia A
- E. Hemophilia B
- F. Vitamin K deficiency
- G. von Willebrand disease

Submit

1
2
3
4
5
6
7
8
9
10
11
12
13
14
15
16
17
18
19
20
21
22
23
24
25
26
27
28
29
30

results are as follows:

Hematocrit	43%
Bleeding time	prolonged
Partial thromboplastin time (PTT)	prolonged
Prothrombin time (PT)	normal
Thrombin time (TT)	normal
D-dimer	normal

Which of the following is the most likely diagnosis?

A. Disseminated intravascular coagulopathy (0%)
B. Dysfibrinogenemia (0%)
C. Factor XIII deficiency (4%)
D. Hemophilia A (9%)
E. Hemophilia B (3%)
F. Vitamin K deficiency (1%)
✓ G. von Willebrand disease (80%)

Omitted
Correct answer

80%
Answered correctly

05 secs
Time Spent

07/01/2020
Last Updated

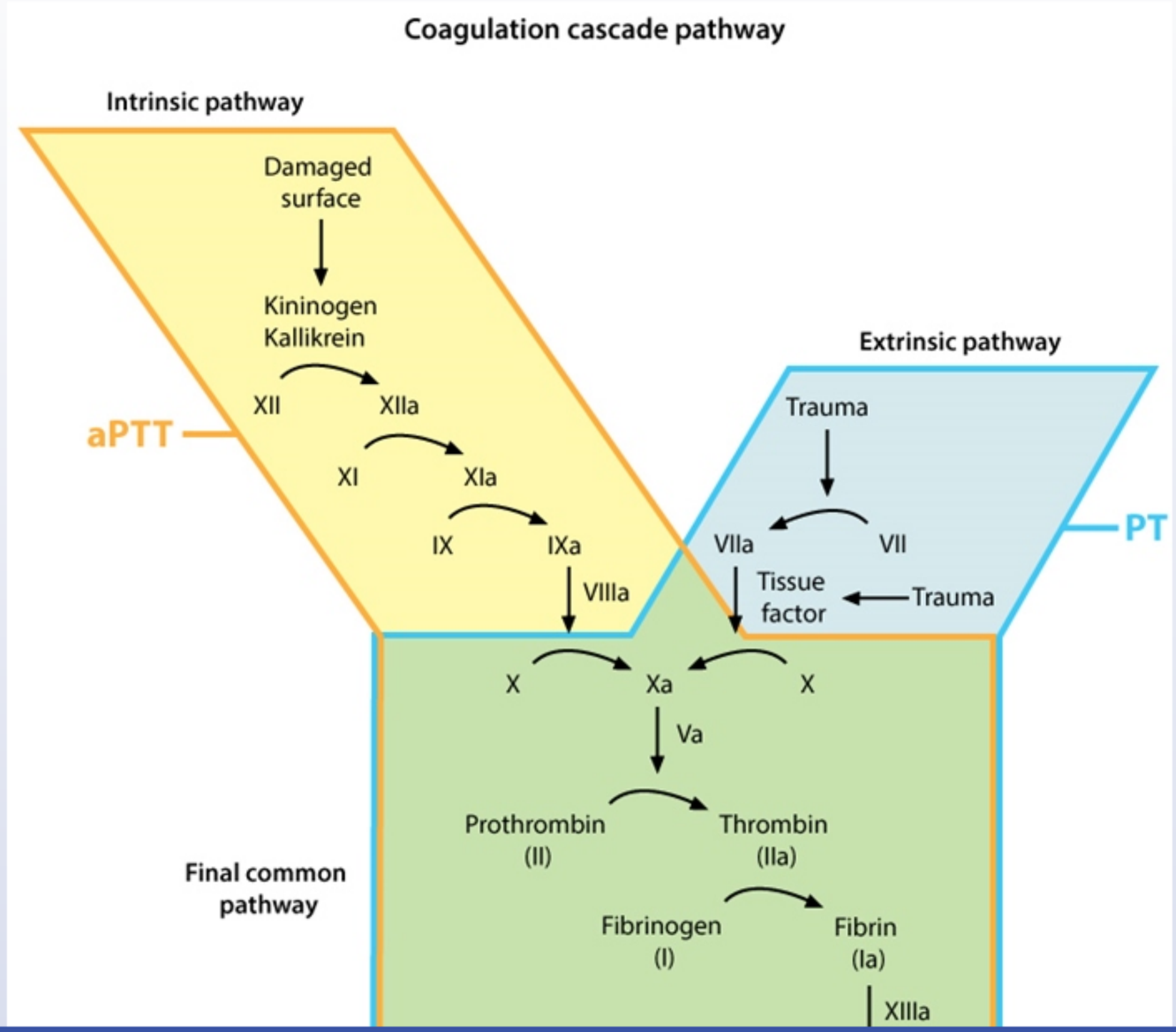
Coagulation cascade pathway
Intrinsic pathway
Damaged surface
Kininogen
Kallikrein
XII
XIIa
XI
XIa
IX
IXa
VIIIa
aPTT
Extrinsic pathway
Trauma
VIIa
VII
Tissue factor
Trauma
PT
X
Xa
X
Va
Prothrombin (II)
Thrombin (IIa)
Fibrinogen (I)
Fibrin (Ia)
XIIIa
Final common pathway

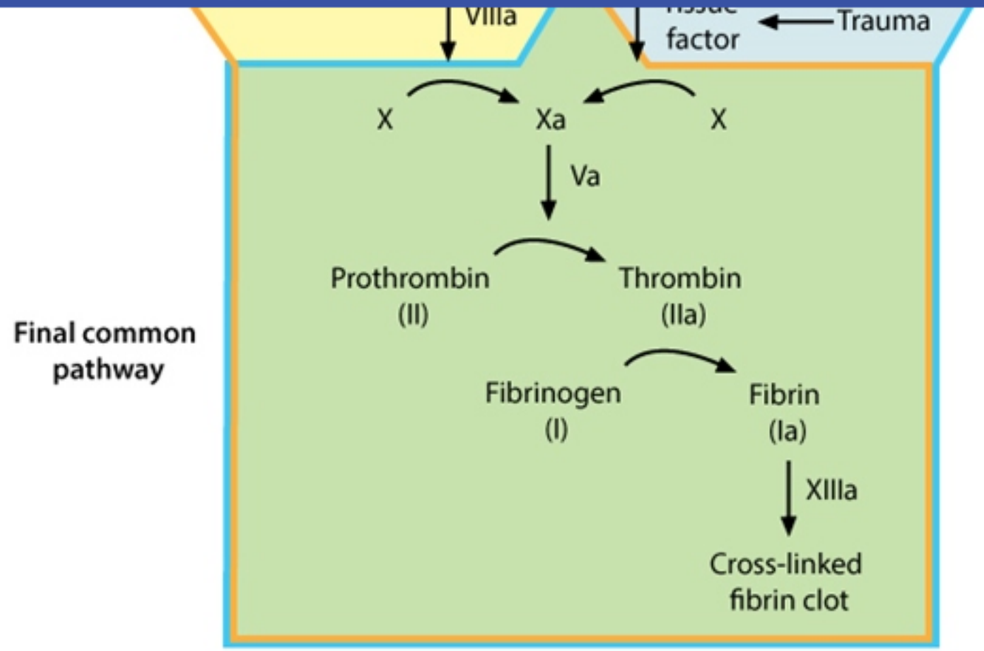

©UWorld

aPTT = activated partial thromboplastin time; **PT** = prothrombin time.

This patient has a normal prothrombin time (PT) and thrombin time (TT) and a **prolonged partial thromboplastin time (PTT)**, indicating a defect in the intrinsic pathway (coagulation factors VIII, IX, XI, or XII). **Bleeding time** is a test of **platelet function** and is prolonged by qualitative and quantitative platelet defects. The term "bleeding time" refers to this particular test and not the duration of bleeding, which can be prolonged from other coagulopathies.

von Willebrand disease (vWD) will cause both a prolonged PTT and bleeding time. von Willebrand factor (vWF) is produced by endothelial cells and megakaryocytes and functions as a **carrier protein for factor VIII** and as a **mediator of platelet adhesion** to the endothelium. Absence of vWF leads to impaired platelet function and coagulation pathway abnormalities. vWD is inherited in an autosomal dominant fashion with variable penetrance and is the **most common heritable bleeding disorder**.

(Choice A) Disseminated intravascular coagulopathy (DIC) is a consumptive coagulopathy most commonly seen in septic shock. PT, PTT, and bleeding time are prolonged, and the D-dimer, a degradation product of cross-linked fibrin, is elevated.

1 2 3 4 5 6 7 8 9 10 11 12 13 14 15 16 17 18 19 20 21 22 23 24 25 26 27 28 29 30

von Willebrand disease (vWD) will cause both a prolonged PTT and bleeding time. von Willebrand factor (vWF) is produced by endothelial cells and megakaryocytes and functions as a **carrier protein for factor VIII** and as a **mediator of platelet adhesion** to the endothelium. Absence of vWF leads to impaired platelet function and coagulation pathway abnormalities. vWD is inherited in an autosomal dominant fashion with variable penetrance and is the **most common heritable bleeding disorder**.

(Choice A) Disseminated intravascular coagulopathy (DIC) is a consumptive coagulopathy most commonly seen in septic shock. PT, PTT, and bleeding time are prolonged, and the D-dimer, a degradation product of cross-linked fibrin, is elevated.

(Choice B) Dysfibrinogenemias are inherited abnormalities in the fibrinogen molecule that can cause excessive bleeding or thrombophilia. TT, PT, and PTT are abnormal in this condition, but bleeding time is unaffected.

(Choice C) Factor XIII is a transglutaminase that cross-links fibrin polymers, thereby stabilizing clots. Factor XIII deficiency causes spontaneous or excessive bleeding, but it would not prolong the bleeding time, PT, or PTT.

(Choice D) Hemophilia A is an X-linked hereditary deficiency of factor VIII that causes coagulopathy with a prolonged PTT but shows normal bleeding time.

(Choice E) Hemophilia B is an X-linked hereditary deficiency of factor IX that causes coagulopathy with a prolonged PTT but shows normal bleeding time.

(Choice F) Vitamin K is required for activation of clotting factors II, VII, IX, and X. Vitamin K deficiency causes a coagulopathy that primarily prolongs PT, with PTT prolongation occurring in severe cases. Bleeding time is not affected.

Educational objective:
von Willebrand disease is the most common inherited bleeding disorder. It has an autosomal dominant pattern of inheritance and variable penetrance. Absence of von Willebrand factor leads to impaired platelet function (prolonged bleeding time) and coagulation pathway abnormalities due to decreased factor VIII activity (prolonged partial thromboplastin time).

References

- Diagnosis and Management of Von Willebrand disease: guidelines for primary care
- Of von Willebrand factor and platelets.

von Willebrand disease (vWD) will cause both a prolonged PTT and bleeding time. von Willebrand factor (vWF) is produced by endothelial cells.

Exhibit Display

Platelet adhesion & activation via vWF

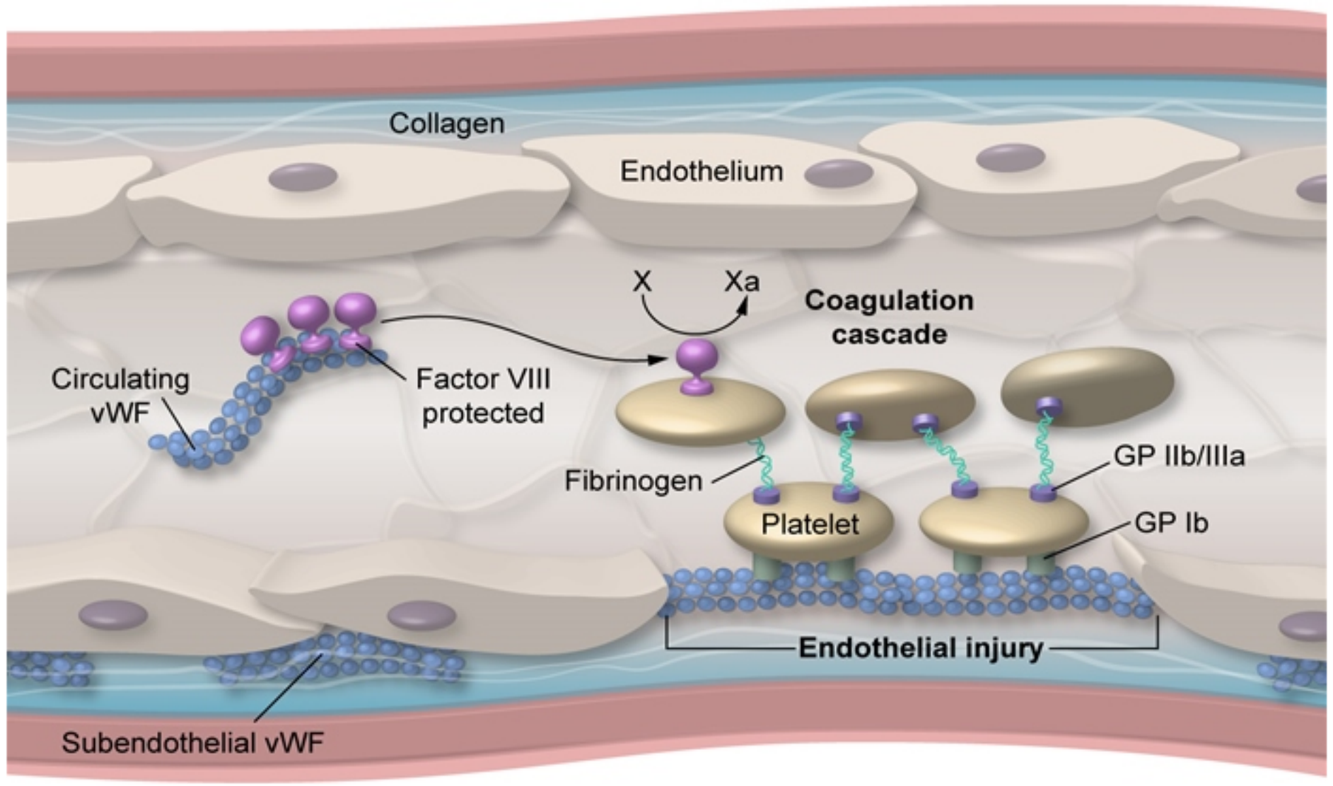

GP = glycoprotein; **vWF** = von Willebrand factor.

©UWorld

Zoom In | Zoom Out | Reset | Add To New Card | Existing Card

- Of von Willebrand factor and platelets.

A 16-year-old girl comes to the office due to fatigue for the past few months. She attends high school and plays on the school soccer team but says that her endurance has decreased. The patient sleeps 9 hours a night and has been a vegetarian for the past year. She reached menarche at age 13 and has had regular menses for the past 6 months. The patient is not sexually active and does not smoke cigarettes but does report drinking 1 or 2 cans of beer a month. Her blood pressure is 110/60 mm Hg, pulse is 70/min, and BMI is 21 kg/m^2. Physical examination shows a well-nourished teenage girl with pale conjunctivae. Her hemoglobin is 9.2 g/dL. Which of the following sets of additional laboratory findings are most likely to be seen in this patient?

	Serum ferritin	Circulating transferrin	Mean corpuscular volume	Hypersegmented neutrophils	Serum folate
A.	Normal	Normal	74	None	Normal
B.	Low	High	76	None	Normal
C.	Low	Low	84	None	Normal
D.	High	Low	95	None	Normal
E.	Normal	Normal	108	Present	Normal
F.	Normal	Normal	115	Present	Low

Submit

1
2
3
4
5
6
7
8
9
10
11
12
13
14
15
16
17
18
19
20
21
22
23
24
25
26
27
28
29
30

A 16-year-old girl comes to the office due to fatigue for the past few months. She attends high school and plays on the school soccer team but says that her endurance has decreased. The patient sleeps 9 hours a night and has been a vegetarian for the past year. She reached menarche at age 13 and has had regular menses for the past 6 months. The patient is not sexually active and does not smoke cigarettes but does report drinking 1 or 2 cans of beer a month. Her blood pressure is 110/60 mm Hg, pulse is 70/min, and BMI is 21 kg/m^2. Physical examination shows a well-nourished teenage girl with pale conjunctivae. Her hemoglobin is 9.2 g/dL. Which of the following sets of additional laboratory findings are most likely to be seen in this patient?

	Serum ferritin	Circulating transferrin	Mean corpuscular volume	Hypersegmented neutrophils	Serum folate
A. (1%)	Normal	Normal	74	None	Normal
✓ B. (54%)	Low	High	76	None	Normal
C. (6%)	Low	Low	84	None	Normal
D. (1%)	High	Low	95	None	Normal
E. (18%)	Normal	Normal	108	Present	Normal
F. (16%)	Normal	Normal	115	Present	Low

1
2
3
4
5
6
7
8
9
10
11
12
13
14
15
16
17
18
19
20
21
22
23
24
25
26
27
28
29
30

Evaluation of anemia

↓ Hemoglobin

↓ MCV

- Iron deficiency
- Lead intoxication
- Thalassemia
- Sideroblastic anemia

Normal MCV

↑ MCV

- Vitamin B_{12} deficiency
- Folate deficiency

↓ Reticulocyte count

- Leukemia
- Aplastic anemia
- Anemia of chronic

↑ Reticulocyte count

- Hemorrhage
- Hemolysis:
  - Spherocytosis

1
2
3
4
5
6
7
8
9
10
11
12
13
14
15
16
17
18
19
20
21
22
23
24
25
26
27
28
29
30

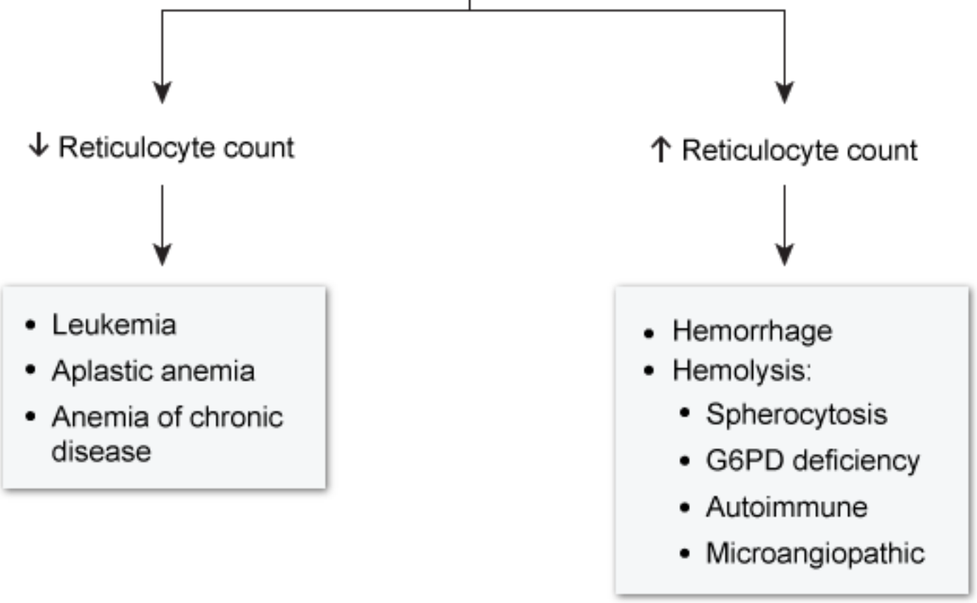

MCV = Mean corpuscular volume; **G6PD** = Glucose-6-phosphate-dehydrogenase deficiency. ©UWorld

This girl has fatigue and conjunctival pallor, which are suggestive of anemia. The diagnosis is confirmed by her low hemoglobin. Women of **childbearing age** are at risk for **iron-deficiency anemia** due to menstrual cycle blood loss, especially teenage girls who have higher iron requirements due to growth. In this patient, decreased consumption of dietary iron (eg, vegetarianism) is an additional risk factor. As iron deficiency develops, the following sequence can be seen with laboratory testing:

1. Decreased bone marrow iron stores (ferritin and hemosiderin)
2. **Decreased serum ferritin**
3. Increased serum total iron-binding capacity, reflecting **increased transferrin**
4. Decreased serum iron concentration
5. Decreased hemoglobin
6. Appearance of microcytic, hypochromic red blood cells (low mean corpuscular volume/mean corpuscular hemoglobin [MCV/MCH])

Ferritin is an intracellular iron-storage protein that is used as a serum marker of total body iron stores. It is decreased in iron deficiency and

MCV = Mean corpuscular volume; **G6PD** = Glucose-6-phosphate-dehydrogenase deficiency. ©UWorld

This girl has fatigue and conjunctival pallor, which are suggestive of anemia. The diagnosis is confirmed by her low hemoglobin. Women of **childbearing age** are at risk for **iron-deficiency anemia** due to menstrual cycle blood loss, especially teenage girls who have higher iron requirements due to growth. In this patient, decreased consumption of dietary iron (eg, vegetarianism) is an additional risk factor. As iron deficiency develops, the following sequence can be seen with laboratory testing:

1. Decreased bone marrow iron stores (ferritin and hemosiderin)
2. **Decreased serum ferritin**
3. Increased serum total iron-binding capacity, reflecting **increased transferrin**
4. Decreased serum iron concentration
5. Decreased hemoglobin
6. Appearance of microcytic, hypochromic red blood cells (low mean corpuscular volume/mean corpuscular hemoglobin [MCV/MCH])

Ferritin is an intracellular iron-storage protein that is used as a serum marker of total body iron stores. It is decreased in iron deficiency and elevated in iron overload or during infection/inflammation (acute phase reaction). Transferrin transports iron through the plasma. When iron levels are normal, approximately one third of circulating transferrin is bound to iron. In iron deficiency, hepatic synthesis of transferrin increases but transferrin saturation drops due to decreased release of iron into the plasma from intracellular stores.

(Choice A) The earliest signs of iron deficiency are low serum ferritin and high serum transferrin, which manifest before overt anemia develops. This pattern of findings is more consistent with α- or β-thalassemia, which usually cause microcytic anemia with normal ferritin and transferrin levels.

(Choice C) Circulating transferrin levels would increase and MCV would decrease in a patient with iron-deficiency anemia.

(Choice D) Low hemoglobin in the setting of a normal MCV, low circulating transferrin, and high serum ferritin is suggestive of anemia of chronic disease, which is often associated with infections and inflammatory conditions. Other acute phase reactants (eg, C-reactive protein, sedimentation rate) are usually elevated in these patients.

(Choices E and F) Hypersegmented neutrophils are characteristic of megaloblastic anemias, which can be caused by folate and vitamin B_{12} deficiency. Folate deficiency is unlikely in this patient, as folate is found in many vegetable products. Although vegetarians are at risk for vitamin

MCV = Mean corpuscular volume; **G6PD** = Glucose-6-phosphate-dehydrogenase deficiency. ©UWorld

Exhibit Display

Microcytic anemia

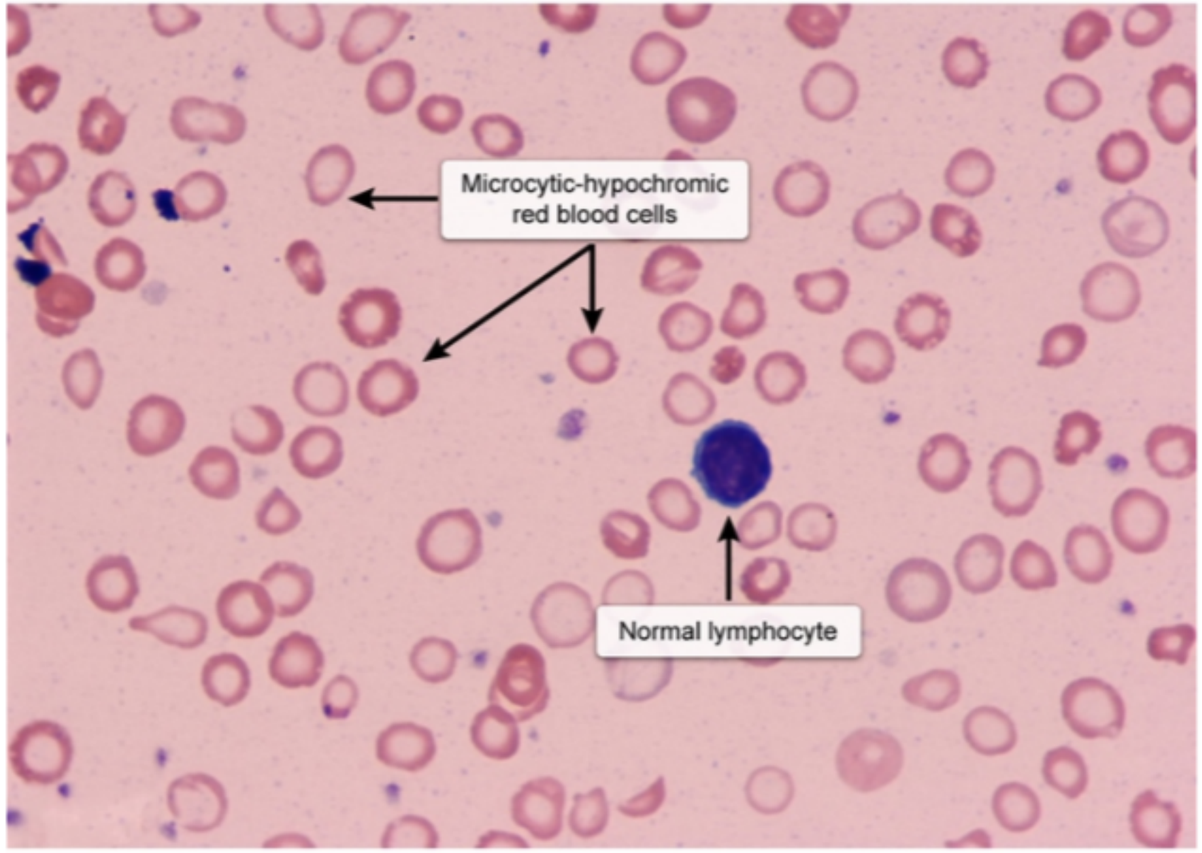

©UWorld

Zoom In | Zoom Out | Reset | Add To New Card | Existing Card

deficiency. Folate deficiency is unlikely in this patient, as folate is found in many vegetable products. Although vegetarians are at risk for vitamin

Ferritin is an intracellular iron-storage protein that is used as a serum marker of total body iron stores. It is decreased in iron deficiency and elevated in iron overload or during infection/inflammation (acute phase reaction). Transferrin transports iron through the plasma. When iron levels are normal, approximately one third of circulating transferrin is bound to iron. In iron deficiency, hepatic synthesis of transferrin increases but transferrin saturation drops due to decreased release of iron into the plasma from intracellular stores.

(Choice A) The earliest signs of iron deficiency are low serum ferritin and high serum transferrin, which manifest before overt anemia develops. This pattern of findings is more consistent with α- or β-thalassemia, which usually cause microcytic anemia with normal ferritin and transferrin levels.

(Choice C) Circulating transferrin levels would increase and MCV would decrease in a patient with iron-deficiency anemia.

(Choice D) Low hemoglobin in the setting of a normal MCV, low circulating transferrin, and high serum ferritin is suggestive of anemia of chronic disease, which is often associated with infections and inflammatory conditions. Other acute phase reactants (eg, C-reactive protein, sedimentation rate) are usually elevated in these patients.

(Choices E and F) Hypersegmented neutrophils are characteristic of megaloblastic anemias, which can be caused by folate and vitamin B_{12} deficiency. Folate deficiency is unlikely in this patient, as folate is found in many vegetable products. Although vegetarians are at risk for vitamin B_{12} deficiency, depletion of hepatic B_{12} stores takes several years, and this patient has been a vegetarian only for the past year.

Educational objective:
Anemia in a woman of childbearing age is most commonly caused by iron deficiency secondary to menstrual blood loss. Iron deficiency is associated with decreased serum ferritin, increased total iron-binding capacity (transferrin), and microcytic, hypochromic red blood cells.

References

- Guideline for the laboratory diagnosis of functional iron deficiency.

Pathology	Hematology & Oncology	Iron deficiency anemia
Subject	System	Topic

Copyright © UWorld. All rights reserved.

Ferritin is an intracellular iron-storage protein that is used as a serum marker of total body iron stores. It is decreased in iron deficiency and

Exhibit Display

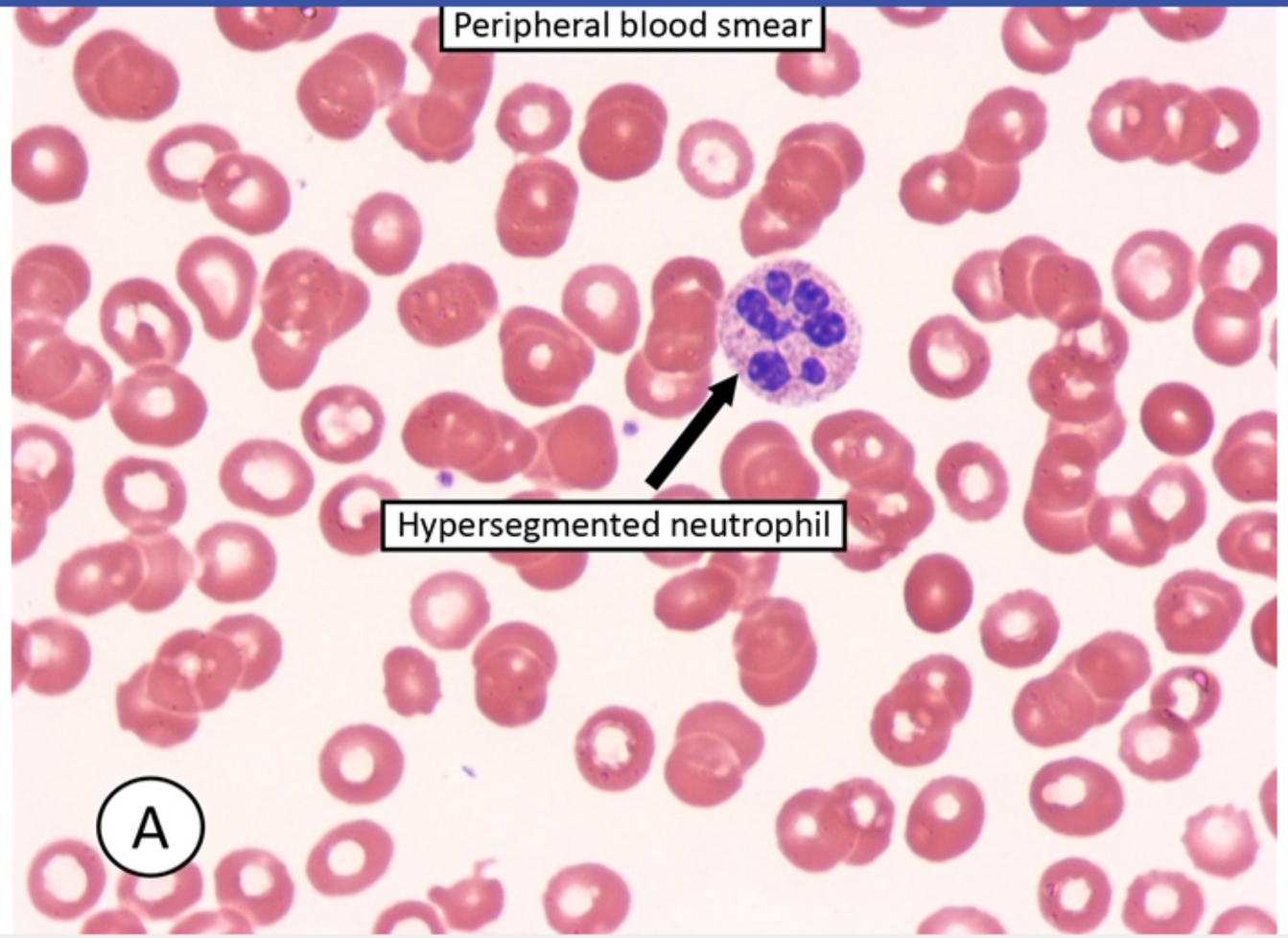

Zoom In | Zoom Out | Reset | Add To New Card | Existing Card

1
2
3
4
5
6
7
8
9
10
11
12
13
14
15
16
17
18
19
20
21
22
23
24
25
26
27
28
29
30

A 3-year-old boy comes to the emergency department for evaluation of oral bleeding that began 1 hour after a tooth extraction. The bleeding has persisted for approximately 30 minutes despite application of constant pressure with gauze. He has no significant past medical or surgical history. The patient takes no medications, and his vaccinations are up to date. Blood pressure is 90/60 mm Hg and pulse is 100/min. On physical examination, he has slow oozing of blood at the site of the dental extraction. Family history is significant for a maternal uncle who suffered from recurrent bleeding into his joints. Which of the following is most likely to be abnormal in this patient?

A. Haptoglobin level
B. Hemoglobin level
C. Partial thromboplastin time
D. Platelet count
E. Platelet function analyzer
F. Prothrombin time
G. Thrombin time

Submit

1
2
3
4
5
6
7
8
9
10
11
12
13
14
15
16
17
18
19
20
21
22
23
24
25
26
27
28
29
30

A 3-year-old boy comes to the emergency department for evaluation of oral bleeding that began 1 hour after a tooth extraction. The bleeding has persisted for approximately 30 minutes despite application of constant pressure with gauze. He has no significant past medical or surgical history. The patient takes no medications, and his vaccinations are up to date. Blood pressure is 90/60 mm Hg and pulse is 100/min. On physical examination, he has slow oozing of blood at the site of the dental extraction. Family history is significant for a maternal uncle who suffered from recurrent bleeding into his joints. Which of the following is most likely to be abnormal in this patient?

- A. Haptoglobin level (0%)
- B. Hemoglobin level (0%)
- ✓ C. Partial thromboplastin time (80%)
- D. Platelet count (3%)
- E. Platelet function analyzer (3%)
- F. Prothrombin time (8%)
- G. Thrombin time (1%)

Omitted
Correct answer
C

80%
Answered correctly

02 secs
Time Spent

03/24/2020
Last Updated

Explanation

Hemophilia A & B

Hemophilia A & B	
Inheritance	• X-linked recessive

Clinical features	• Delayed/prolonged bleeding after mild trauma
	  ◦ Hemarthrosis, intramuscular hematomas
	  ◦ Gastrointestinal or genitourinary tract bleeding
	  ◦ Intracranial hemorrhage
	• Complications: hemophilic arthropathy

Laboratory findings	• ↑ Activated PTT • Normal platelet count & PT • Absent or ↓ factor VIII (hemophilia A) or factor IX (hemophilia B) activity
Treatment	• Factor replacement • Desmopressin for mild hemophilia A

Abnormal bleeding following tooth extractions or other surgical procedures can signify a quantitative or qualitative platelet defect, coagulopathy, or abnormal fibrinolysis. This patient's **male sex** and **family history** of **hemarthrosis** in a maternal male relative suggest an **X-linked coagulopathy** such as hemophilia A (factor VIII deficiency) or hemophilia B (factor IX deficiency, Christmas disease). Hemophilia A and B are indistinguishable clinically as both demonstrate similar symptoms and inheritance patterns. Both conditions are characterized by isolated prolongation of partial thromboplastin time due to defects in the intrinsic coagulation pathway. Prothrombin time [PT] and thrombin time [TT] are normal in patients with hemophilia.

When endothelial injury occurs, platelets are activated and form a hemostatic plug first, followed by activation of the coagulation cascade. Patients with hemophilia have normal platelet function and can form a platelet plug, so bleeding after procedures can be delayed rather than immediate, in contrast to patients with platelet disorders. Manifestations include **intramuscular hemorrhage**, hemarthrosis, and prolonged or

Abnormal bleeding following tooth extractions or other surgical procedures can signify a quantitative or qualitative platelet defect, coagulopathy, or abnormal fibrinolysis. This patient's **male sex** and **family history** of **hemarthrosis** in a maternal male relative suggest an **X-linked coagulopathy** such as hemophilia A (factor VIII deficiency) or hemophilia B (factor IX deficiency, Christmas disease). Hemophilia A and B are indistinguishable clinically as both demonstrate similar symptoms and inheritance patterns. Both conditions are characterized by isolated prolongation of partial thromboplastin time due to defects in the intrinsic coagulation pathway. Prothrombin time [PT] and thrombin time [TT] are normal in patients with hemophilia.

When endothelial injury occurs, platelets are activated and form a hemostatic plug first, followed by activation of the coagulation cascade. Patients with hemophilia have normal platelet function and can form a platelet plug, so bleeding after procedures can be delayed rather than immediate, in contrast to patients with platelet disorders. Manifestations include **intramuscular hemorrhage**, hemarthrosis, and prolonged or **delayed bleeding** after surgical procedures.

(Choice A) Low haptoglobin is a sign of hemolytic anemia. Other associated findings include increased indirect bilirubin and lactate dehydrogenase.

(Choice B) This patient's hemoglobin level is likely normal since the oozing began recently and he has no history of chronic or recurrent bleeding.

(Choice D) Signs of thrombocytopenia include easy bruisability, petechiae, and mucocutaneous hemorrhage (eg, recurrent epistaxis, gingival hemorrhage). The absence of petechiae and the delayed bleeding onset make a platelet disorder unlikely.

(Choice E) The platelet function analyzer (PFA-100) test monitors the time needed for a patient's blood to form a platelet-based hemostatic plug in an in vitro environment. Abnormal results are seen in von Willebrand disease, inherited/acquired platelet dysfunction (eg, NSAID use), and thrombocytopenia.

(Choice F) PT reflects the extrinsic clotting pathway, which involves tissue factor, fibrinogen, and factors II, V, VII, and X. Vitamin K deficiency and warfarin anticoagulant therapy are common causes of isolated PT prolongation as they lead to decreased activity of factors II, VII, IX, and X. Inherited deficiencies of these clotting factors are very rare.

(Choice G) The TT measures the rate of conversion of fibrinogen to fibrin. It is prolonged in patients with deficient or defective fibrinogen, which can be congenital or acquired. The most common cause of acquired dysfibrinogenemia is liver disease.

Educational objective:

Abnormal bleeding following tooth extractions or other surgical procedures can signify a quantitative or qualitative platelet defect, coagulopathy, or

Exhibit Display

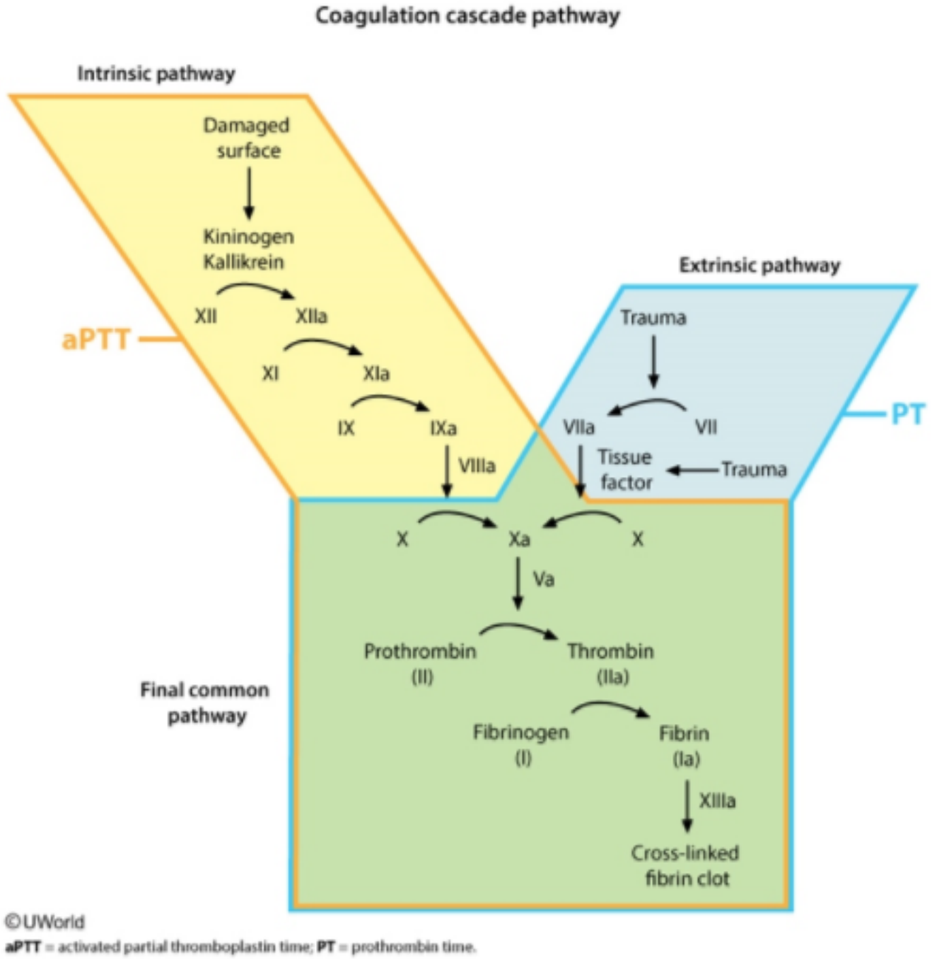

Zoom In | Zoom Out | Reset | Add To New Card | Existing Card

Educational objective:

(Choice A) Low haptoglobin is a sign of hemolytic anemia. Other associated findings include increased indirect bilirubin and lactate dehydrogenase.

(Choice B) This patient's hemoglobin level is likely normal since the oozing began recently and he has no history of chronic or recurrent bleeding.

(Choice D) Signs of thrombocytopenia include easy bruisability, petechiae, and mucocutaneous hemorrhage (eg, recurrent epistaxis, gingival hemorrhage). The absence of petechiae and the delayed bleeding onset make a platelet disorder unlikely.

(Choice E) The platelet function analyzer (PFA-100) test monitors the time needed for a patient's blood to form a platelet-based hemostatic plug in an in vitro environment. Abnormal results are seen in von Willebrand disease, inherited/acquired platelet dysfunction (eg, NSAID use), and thrombocytopenia.

(Choice F) PT reflects the extrinsic clotting pathway, which involves tissue factor, fibrinogen, and factors II, V, VII, and X. Vitamin K deficiency and warfarin anticoagulant therapy are common causes of isolated PT prolongation as they lead to decreased activity of factors II, VII, IX, and X. Inherited deficiencies of these clotting factors are very rare.

(Choice G) The TT measures the rate of conversion of fibrinogen to fibrin. It is prolonged in patients with deficient or defective fibrinogen, which can be congenital or acquired. The most common cause of acquired dysfibrinogenemia is liver disease.

Educational objective:
Hemophilia is an X-linked recessive coagulopathy that presents with intramuscular hemorrhage, hemarthroses, and delayed bleeding after procedures. Laboratory results show partial thromboplastin time prolongation; other tests of hemostatic function are generally normal.

References

- Bleeding and bruising: a diagnostic work-up.
- Diagnosis and management of von Willebrand disease: guidelines for primary care.

Pathology	Hematology & Oncology	Hemophilias
Subject	System	Topic

Copyright © UWorld. All rights reserved.

1
2
3
4
5
6
7
8
9
10
11
12
13
14
15
16
17
18
19
20
21
22
23
24
25
26
27
28
29
30

A 34-year-old male notes a lump in his neck that has grown slowly over the past several months. His social history is significant for smoking one pack of cigarettes per day and occasional alcohol use. On review of systems, he denies dysphagia, chest pain, weight loss or fever. Biopsy of the mass reveals abnormal cells with the t(14;18) chromosomal translocation. This chromosomal change is most likely to cause which of the following abnormalities in gene expression?

A. Bcl2 overexpression

B. Bcr-abl hybrid formation

C. C-myc overexpression

D. Erb-B2 overexpression

E. p53 inactivation

Submit

1
2
3
4
5
6
7
8
9
10
11
12
13
14
15
16
17
18
19
20
21
22
23
24
25
26
27
28
29
30

A 34-year-old male notes a lump in his neck that has grown slowly over the past several months. His social history is significant for smoking one pack of cigarettes per day and occasional alcohol use. On review of systems, he denies dysphagia, chest pain, weight loss or fever. Biopsy of the mass reveals abnormal cells with the t(14;18) chromosomal translocation. This chromosomal change is most likely to cause which of the following abnormalities in gene expression?

- ✓ A. Bcl2 overexpression (64%)
- B. Bcr-abl hybrid formation (9%)
- C. C-myc overexpression (19%)
- D. Erb-B2 overexpression (2%)
- E. p53 inactivation (3%)

Omitted
Correct answer
A

64%
Answered correctly

02 secs
Time Spent

02/03/2020
Last Updated

Explanation

This patient has follicular lymphoma, a non-Hodgkin lymphoma of the cleaved and noncleaved B-lymphocytes of the follicular center. The classic cytogenetic abnormality in follicular lymphoma is the t(14;18) translocation, which moves the *Bcl*-2 (B-cell lymphoma-2) protooncogene from chromosome 18 to chromosome 14, near the site of the immunoglobulin heavy chain enhancer element. *Bcl*-2 is considered a protooncogene because it has anti-apoptotic effects (prevents the release of pro-apoptotic factors within affected cells). When this protooncogene is positioned near the immunoglobulin enhancer element, the resultant *Bcl*-2 overexpression allows for cell immortality.

This patient has follicular lymphoma, a non-Hodgkin lymphoma of the cleaved and noncleaved B-lymphocytes of the follicular center. The classic cytogenetic abnormality in follicular lymphoma is the t(14;18) translocation, which moves the *Bcl*-2 (B-cell lymphoma-2) protooncogene from chromosome 18 to chromosome 14, near the site of the immunoglobulin heavy chain enhancer element. *Bcl*-2 is considered a protooncogene because it has anti-apoptotic effects (prevents the release of pro-apoptotic factors within affected cells). When this protooncogene is positioned near the immunoglobulin enhancer element, the resultant *Bcl*-2 overexpression allows for cell immortality.

(Choice B) The Bcr-abl hybrid is formed as a result of a reciprocal translocation between chromosomes 9 and 22 (the Philadelphia chromosome). This is the characteristic cytogenetic abnormality in chronic myelogenous leukemia (CML).

(Choice C) C-myc overexpression occurs in many malignancies. The myc oncogene is located on chromosome 8. Translocations between chromosome 8 and chromosomes coding for the immunoglobulin heavy chain (14), the kappa light chain (2), or the lambda light chain (22) may result in Burkitt lymphoma.

(Choice D) ErbB2, HER2 and neu are all names for the same epidermal growth factor receptor, which is overexpressed in many cases of breast cancer.

(Choice E) p53 gene inactivation occurs as one of the two "hits" in many human malignancies. Normally, the p53 protein functions as a tumor suppressor. Li-Fraumeni syndrome is an autosomal dominant cancer syndrome caused by an inherited mutation in p53.

Educational Objective:
Follicular lymphoma is a non-Hodgkin lymphoma of follicular B-lymphocytes. Patients with follicular lymphoma characteristically have a translocation between chromosomes 14 and 18 which causes *Bcl*-2 overexpression. *Bcl*-2 is considered a protooncogene because it has anti-apoptotic effects.

Pathology	Hematology & Oncology	Nonhodgkin lymphoma
Subject	System	Topic

Copyright © UWorld. All rights reserved.

1
2
3
4
5
6
7
8
9
10
11
12
13
14
15
16
17
18
19
20
21
22
23
24
25
26
27
28
29
30

A 44-year-old woman comes to the office due to "indigestion." The patient often develops right upper quadrant abdominal discomfort and nausea after fatty meals, which subside spontaneously in several hours. She does not use tobacco, alcohol, or illicit drugs. The patient immigrated to the United States from Nepal 10 years ago. Abdominal ultrasound reveals numerous gallstones, and she undergoes elective laparoscopic cholecystectomy. The stones in her gallbladder have very low cholesterol content and appear small, dark, and spiculated. Which of the following conditions most likely predisposed this patient to gallstone formation?

A. Chronic hemolysis

B. Metabolic syndrome

C. Multiparity

D. Oral contraceptive use

E. Rapid weight loss

Submit

1
2
3
4
5
6
7
8
9
10
11
12
13
14
15
16
17
18
19
20
21
22
23
24
25
26
27
28
29
30

A 44-year-old woman comes to the office due to "indigestion." The patient often develops right upper quadrant abdominal discomfort and nausea after fatty meals, which subside spontaneously in several hours. She does not use tobacco, alcohol, or illicit drugs. The patient immigrated to the United States from Nepal 10 years ago. Abdominal ultrasound reveals numerous gallstones, and she undergoes elective laparoscopic cholecystectomy. The stones in her gallbladder have very low cholesterol content and appear small, dark, and spiculated. Which of the following conditions most likely predisposed this patient to gallstone formation?

- ✓ A. Chronic hemolysis (85%)
- B. Metabolic syndrome (4%)
- C. Multiparity (3%)
- D. Oral contraceptive use (3%)
- E. Rapid weight loss (3%)

Omitted
Correct answer
A

85%
Answered correctly

01 sec
Time Spent

02/10/2020
Last Updated

Explanation

1
2
3
4
5
6
7
8
9
10
11
12
13
14
15
16
17
18
19
20
21
22
23
24
25
26
27
28
29
30

Pathogenesis of pigment stones

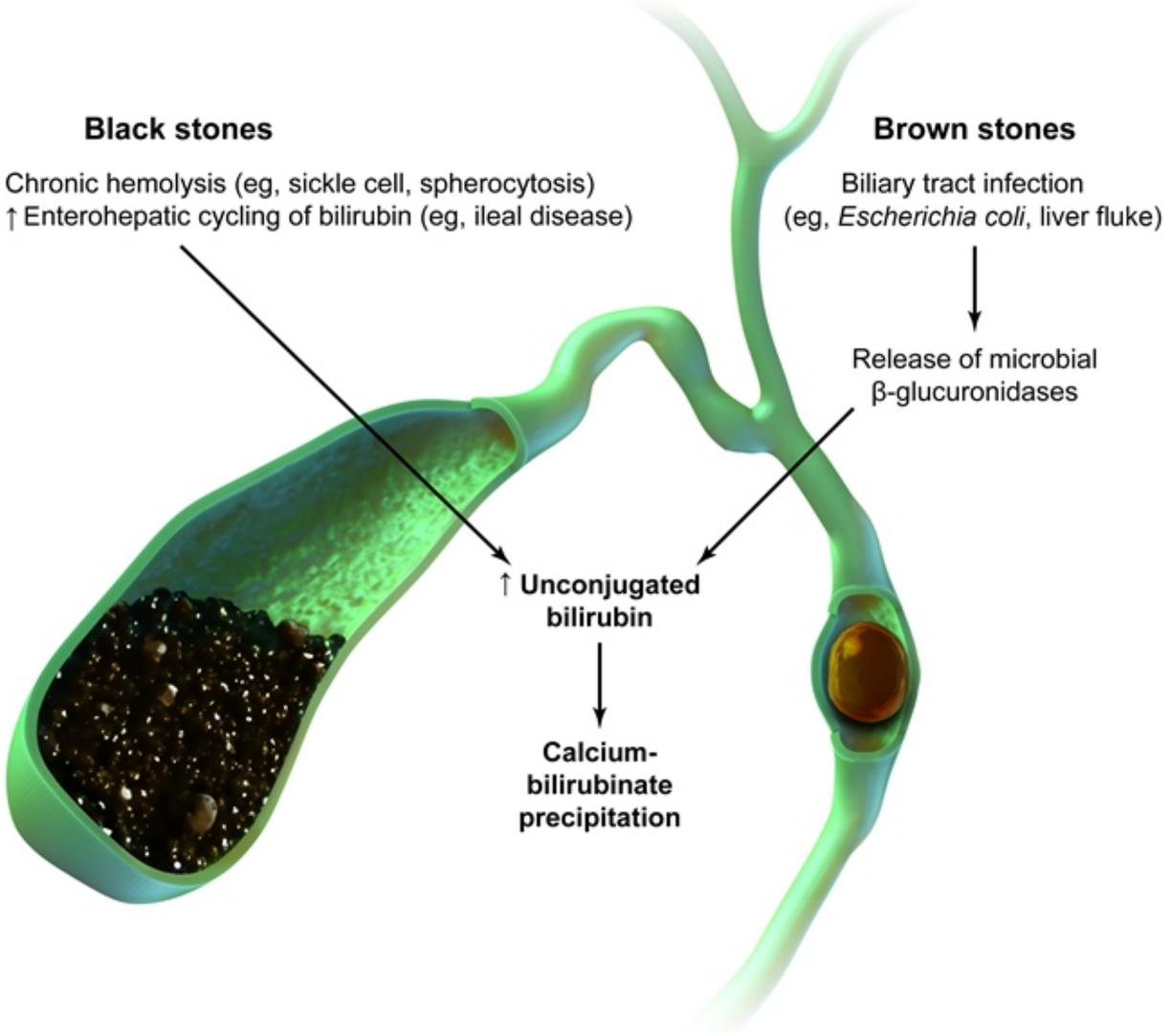

©UWorld

©UWorld

Gallstones are formed by the aggregation of bile constituents and are categorized as cholesterol stones, pigment stones, or mixed stones. **Pigment gallstones**, which account for only 10%-25% of gallstone cases in the United States, are most common in rural Asian populations. These stones can be brown to black and arise from conditions that increase the amount of **unconjugated bilirubin** in bile, which promotes calcium bilirubinate precipitation. Brown pigment stones are associated with biliary tract infections (microbes producing β-glucuronidases), whereas **black stones** occur in the setting of chronic **hemolysis** (eg, sickle cell anemia, β-thalassemia, hereditary spherocytosis) and increased enterohepatic cycling of bilirubin (eg, **ileal disease**).

Grossly, black pigment stones are usually present in significant numbers and are small, spiculated, and friable. Because these stones contain high amounts of calcium carbonates and phosphates, they are often radiopaque and appear on x-ray.

(Choices B, C, D, and E) Obesity/metabolic syndrome, multiparity, oral contraceptive use, and rapid weight loss are significant risk factors for development of cholesterol gallstones.

Educational objective:
Black pigment stones arise from conditions that increase the amount of unconjugated bilirubin in bile, which promotes calcium bilirubinate precipitation. This may occur in the setting of chronic hemolysis (eg, sickle cell anemia, β-thalassemia, hereditary spherocytosis) and increased enterohepatic cycling of bilirubin (eg, ileal disease).

References

- New pathophysiological concepts underlying pathogenesis of pigment gallstones.

Pathology	Hematology & Oncology	Gallstone disease
Subject	System	Topic

Copyright © UWorld. All rights reserved.

A 23-year-old man comes to the emergency department due to 4 days of cramping abdominal pain. He has been feeling weak for the past 2 weeks. He tried over-the-counter antacids without relief. He is an industrial laborer with no significant medical history or known allergies. The patient's parents have hypertension, and his siblings are healthy. Temperature is 37.1 C (98.8 F). Physical examination is unremarkable. The patient's peripheral blood smear is shown on the image below.

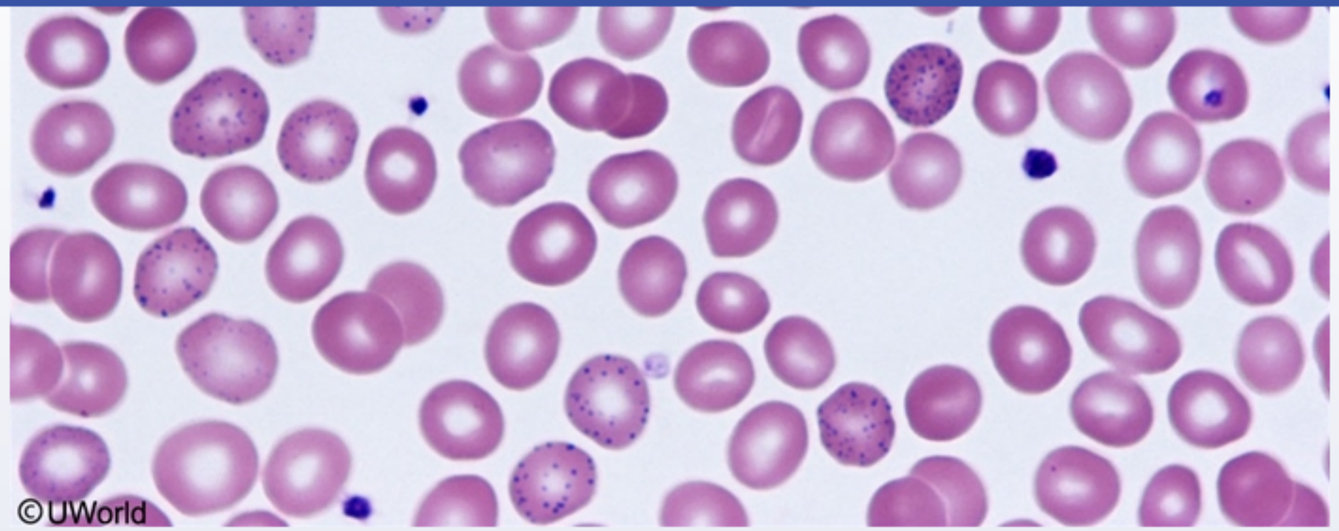

Which of the following is the most likely cause of this patient's symptoms?

- A. Acute intermittent porphyria
- B. Acute leukemia
- C. Atrophic gastritis
- D. Metal poisoning
- E. Non-Hodgkin lymphoma
- F. Poor nutrition

Submit

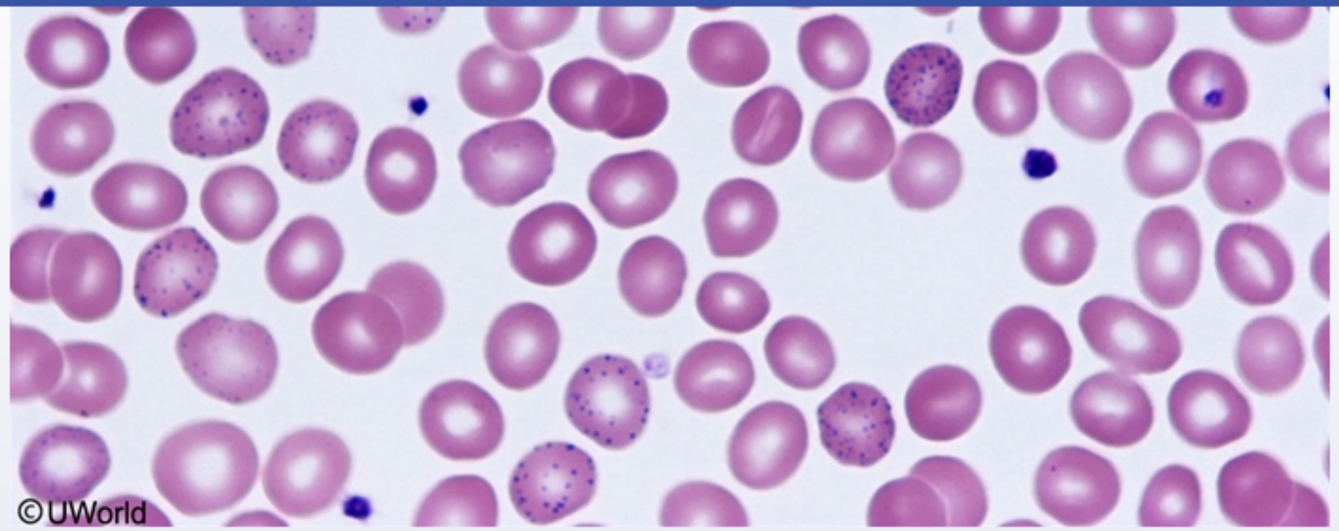

Which of the following is the most likely cause of this patient's symptoms?

- A. Acute intermittent porphyria (5%)
- B. Acute leukemia (0%)
- C. Atrophic gastritis (1%)
- ✓ D. Metal poisoning (90%)
- E. Non-Hodgkin lymphoma (0%)
- F. Poor nutrition (0%)

Omitted
Correct answer

90%
Answered correctly

04 secs
Time Spent

05/09/2020
Last Updated

1
2
3
4
5
6
7
8
9
10
11
12
13
14
15
16
17
18
19
20
21
22
23
24
25
26
27
28
29
30

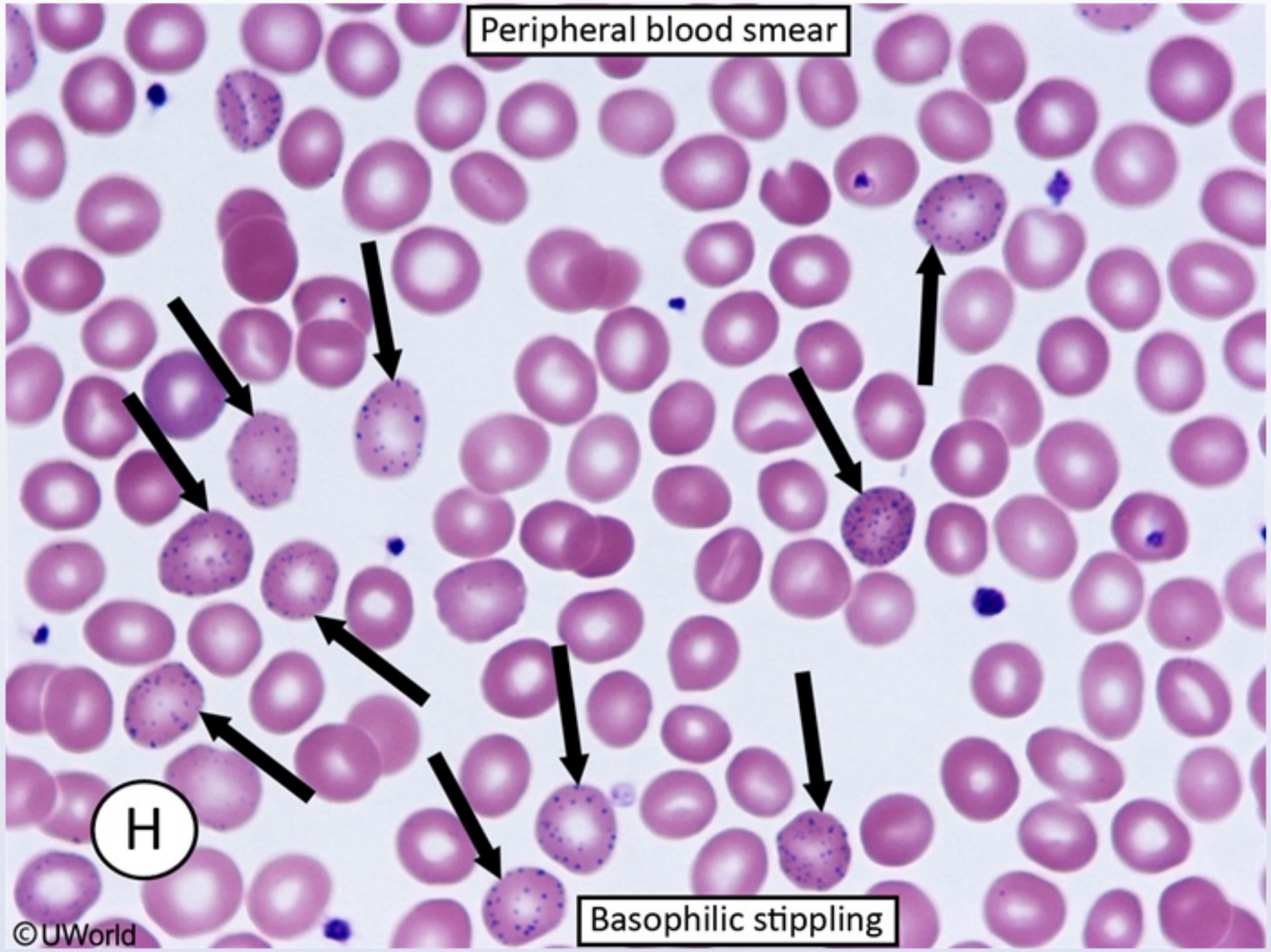

This patient likely has **lead poisoning**. In the United States, lead poisoning (plumbism) is typically a pediatric condition that results from children ingesting lead-containing **paint** chips. However, lead poisoning can also occur in adults. Affected individuals are usually **miners** or industrial workers (especially those in battery manufacturing) who inhale particulate lead while working. Adults with lead poisoning present with weakness, **abdominal pain**, and constipation. In severe cases, there may be **neurologic** manifestations (eg, headache, cognitive symptoms, peripheral

©UWorld

This patient likely has **lead poisoning**. In the United States, lead poisoning (plumbism) is typically a pediatric condition that results from children ingesting lead-containing **paint** chips. However, lead poisoning can also occur in adults. Affected individuals are usually **miners** or industrial workers (especially those in battery manufacturing) who inhale particulate lead while working. Adults with lead poisoning present with weakness, **abdominal pain**, and constipation. In severe cases, there may be **neurologic** manifestations (eg, headache, cognitive symptoms, peripheral neuropathy). On physical examination, patients may have **blue "lead lines"** at the junction of the teeth and gingivae.

The classic diagnostic finding on peripheral blood smear is coarse **basophilic stippling** on a background of hypochromic microcytic anemia. Basophilic stippling results from the abnormal degradation of ribosomal RNA (due to lead-induced inhibition of a nucleotidase). The hypochromic microcytic anemia results from inhibition of δ-aminolevulinate dehydratase (δ-ALA dehydratase) and the resultant reduced incorporation of iron into heme. The net effect of these defects is decreased hemoglobin synthesis.

(Choice A) Acute intermittent porphyria can cause attacks of abdominal pain (without abdominal tenderness) due to autonomic neuropathy. Erythropoiesis is not affected, and the peripheral blood smear is normal.

(Choice B) Myeloblasts containing cytoplasmic Auer rods on peripheral blood smear are a characteristic finding of acute myelogenous leukemia.

(Choice C) The autoimmune destruction of gastric parietal cells and/or intrinsic factor cause atrophic (autoimmune) gastritis, which can lead to pernicious anemia due to vitamin B_{12} malabsorption.

(Choice E) Non-Hodgkin lymphoma can invade the bone marrow, causing myelophthisic anemia. A peripheral blood smear would show leukoerythroblastosis (immature granulocytes and nucleated teardrop-shaped erythrocytes).

(Choice F) Malnutrition may lead to folate deficiency or, more rarely, vitamin B_{12} deficiency. Deficiencies of either vitamin cause megaloblastic anemia, with hypersegmented neutrophils and large erythrocytes on peripheral blood smear.

Educational objective:
Coarse erythrocyte basophilic stippling and microcytic hypochromic anemia are common peripheral blood smear findings in lead poisoning. High-risk groups include young children ingesting paint chips and industrial workers inhaling particulate lead.

Pathology Hematology & Oncology Lead poisoning

©UWorld

Exhibit Display

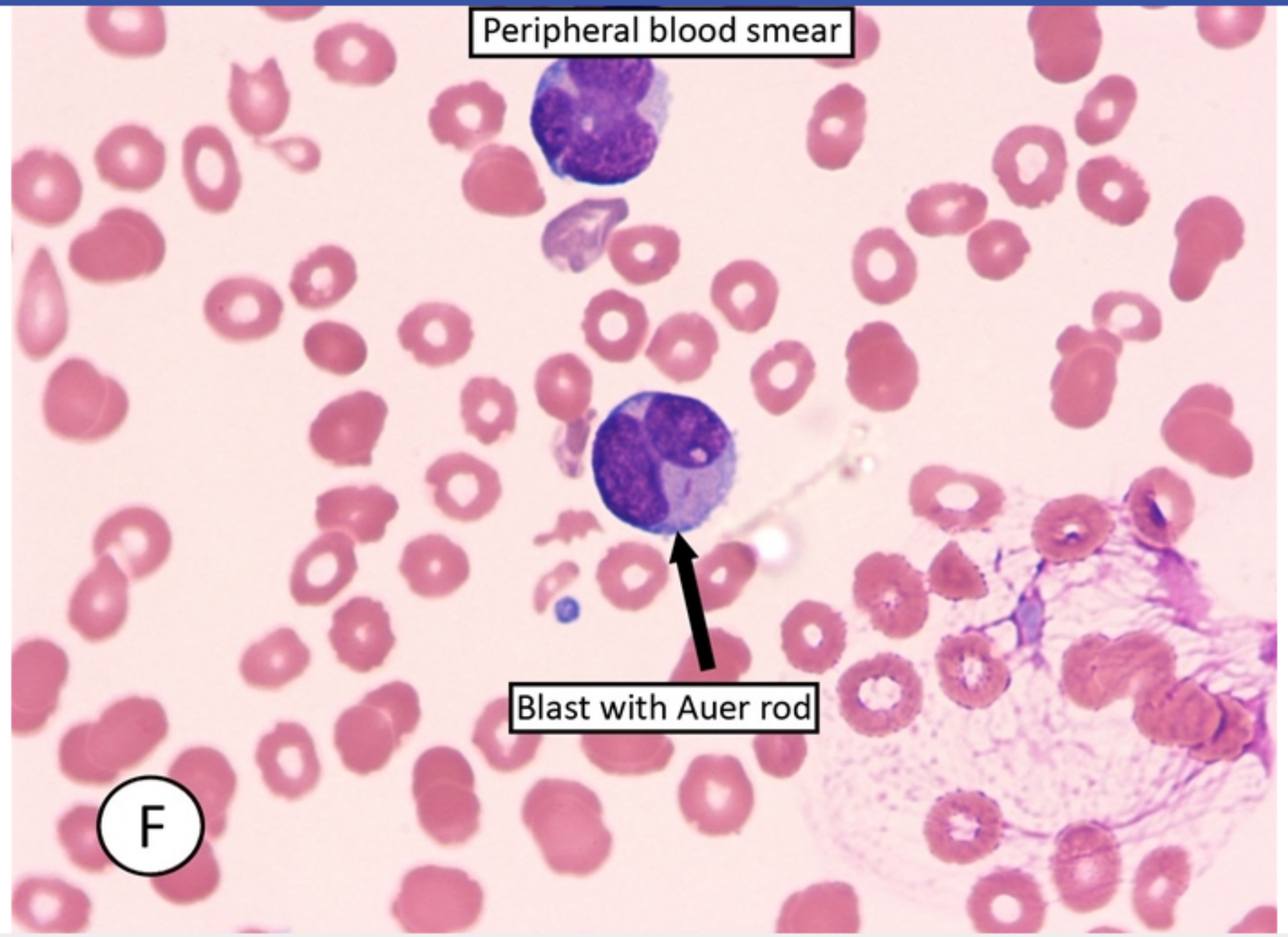

Zoom In | Zoom Out | Reset | Add To New Card | Existing Card

Pathology | Hematology & Oncology | Lead poisoning

1
2
3
4
5
6
7
8
9
10
11
12
13
14
15
16
17
18
19
20
21
22
23
24
25
26
27
28
29
30

©UWorld

Exhibit Display

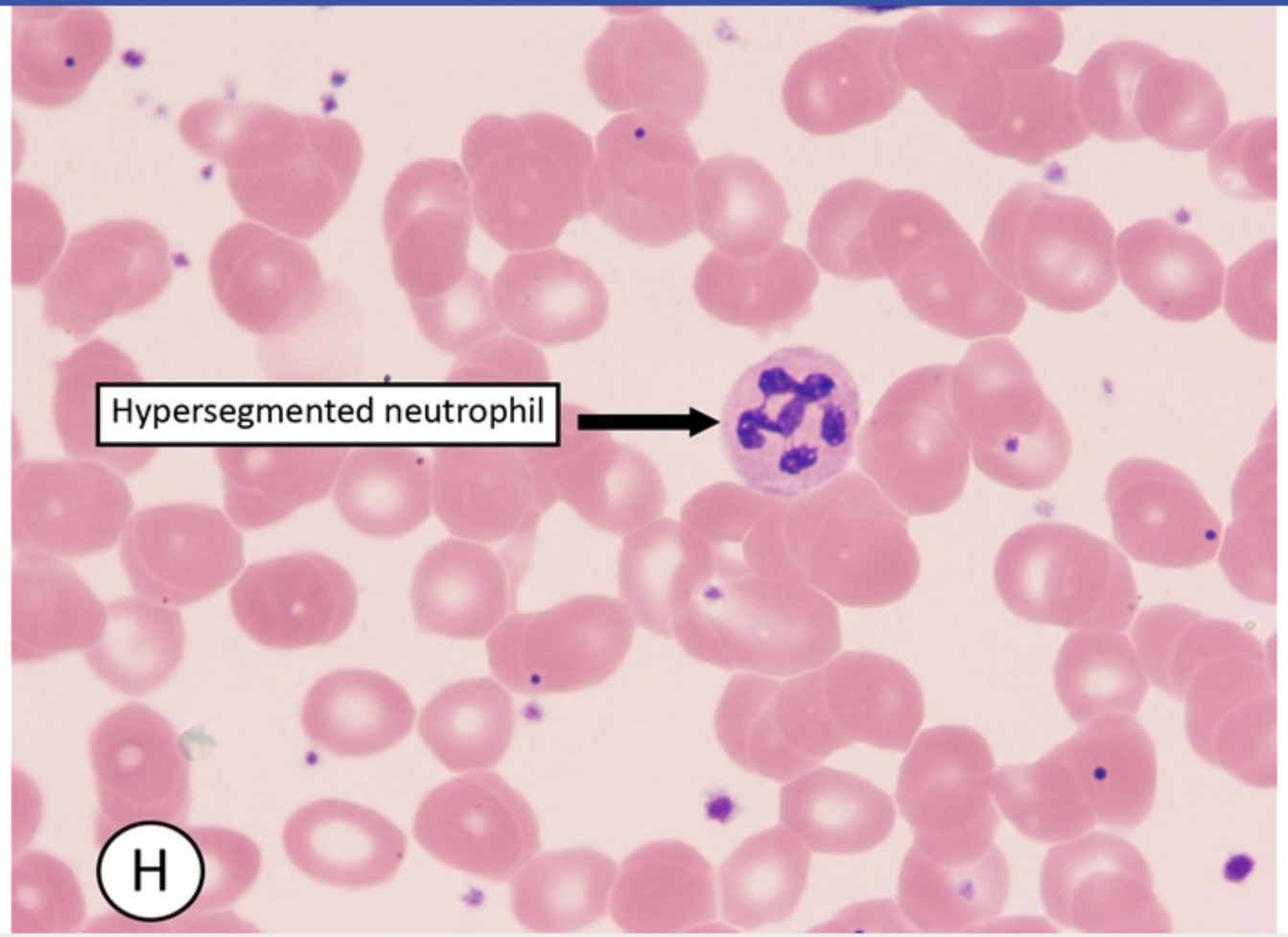

Zoom In | Zoom Out | Reset | Add To New Card | Existing Card

Pathology | Hematology & Oncology | Lead poisoning

1
2
3
4
5
6
7
8
9
10
11
12
13
14
15
16
17
18
19
20
21
22
23
24
25
26
27
28
29
30

A 46-year-old smoker presents to your office with a three week history of low-grade fever, weakness and neck swelling. Biopsy of the affected tissue reveals the following histologic findings:

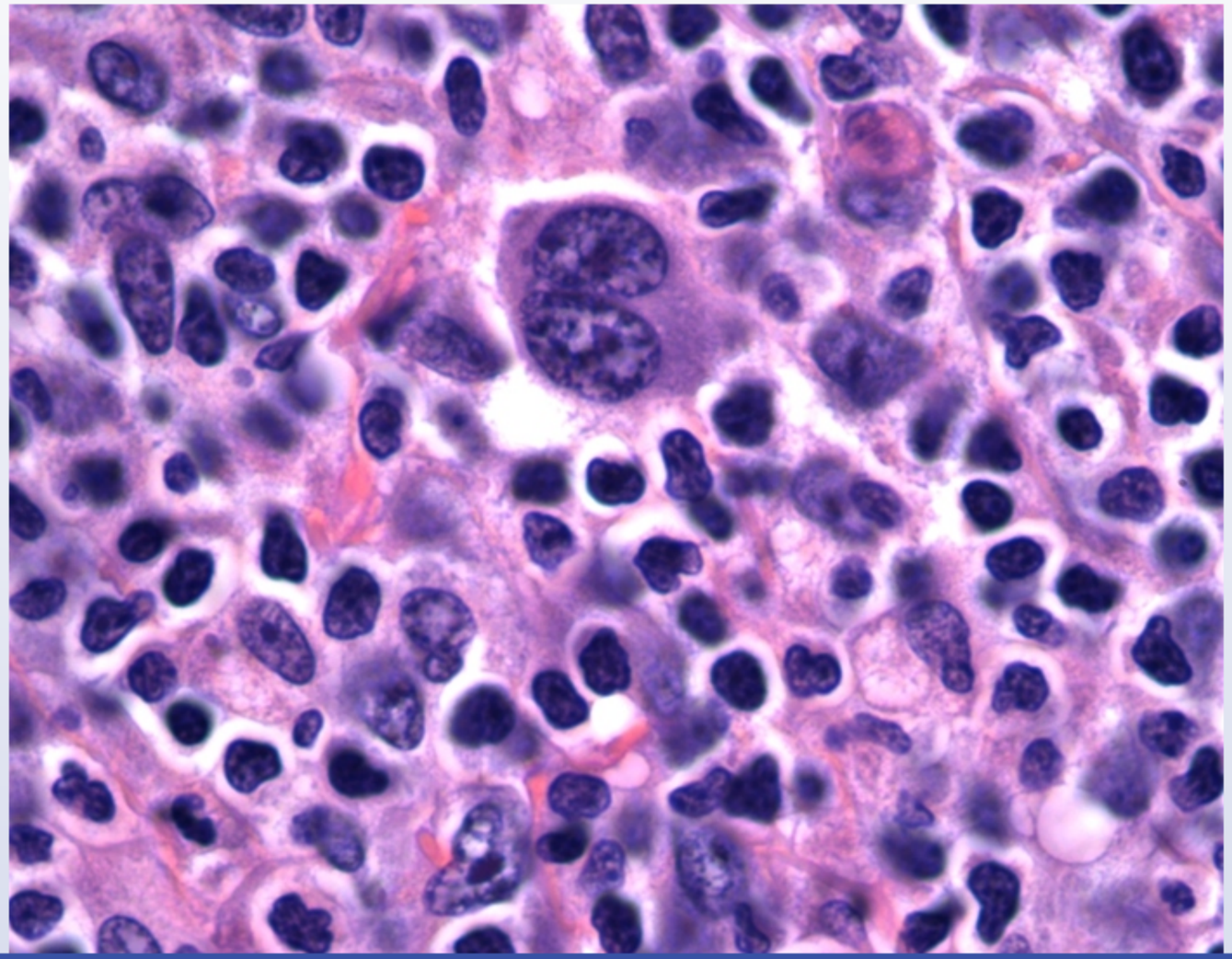

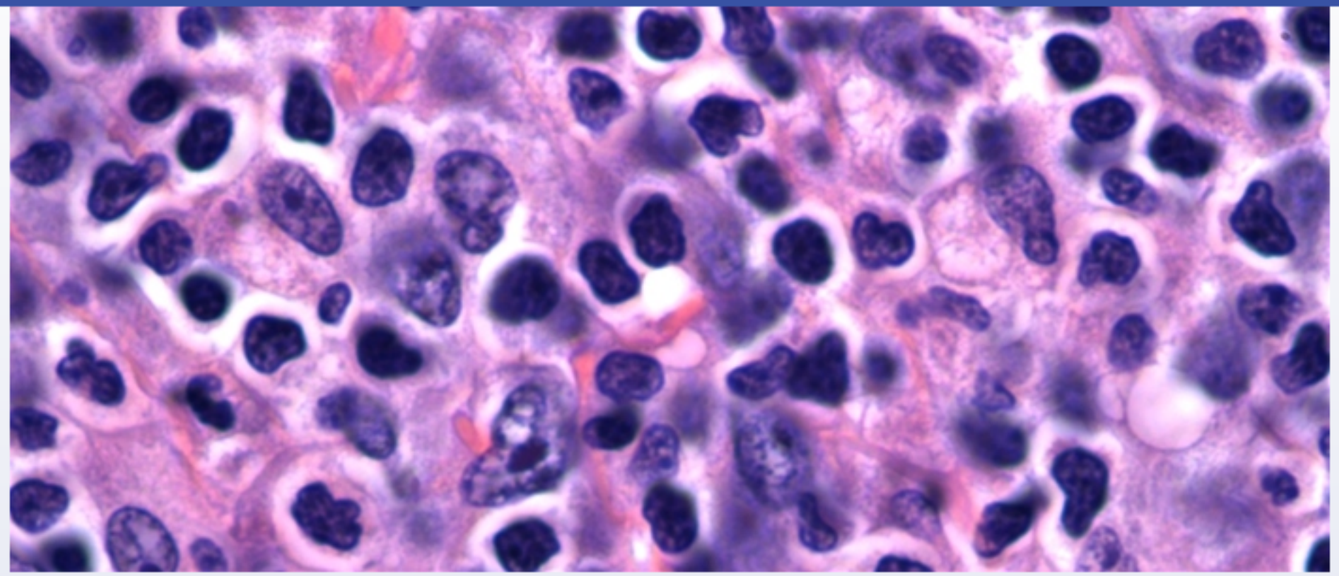

An abnormality in which of the following tissues is most likely responsible for this patient's symptoms?

- A. Respiratory epithelium
- B. Thyroid gland
- C. Lymphoid tissue
- D. Myeloid precursors
- E. Skin epithelium

Submit

1
2
3
4
5
6
7
8
9
10
11
12
13
14
15
16
17
18
19
20
21
22
23
24
25
26
27
28
29
30

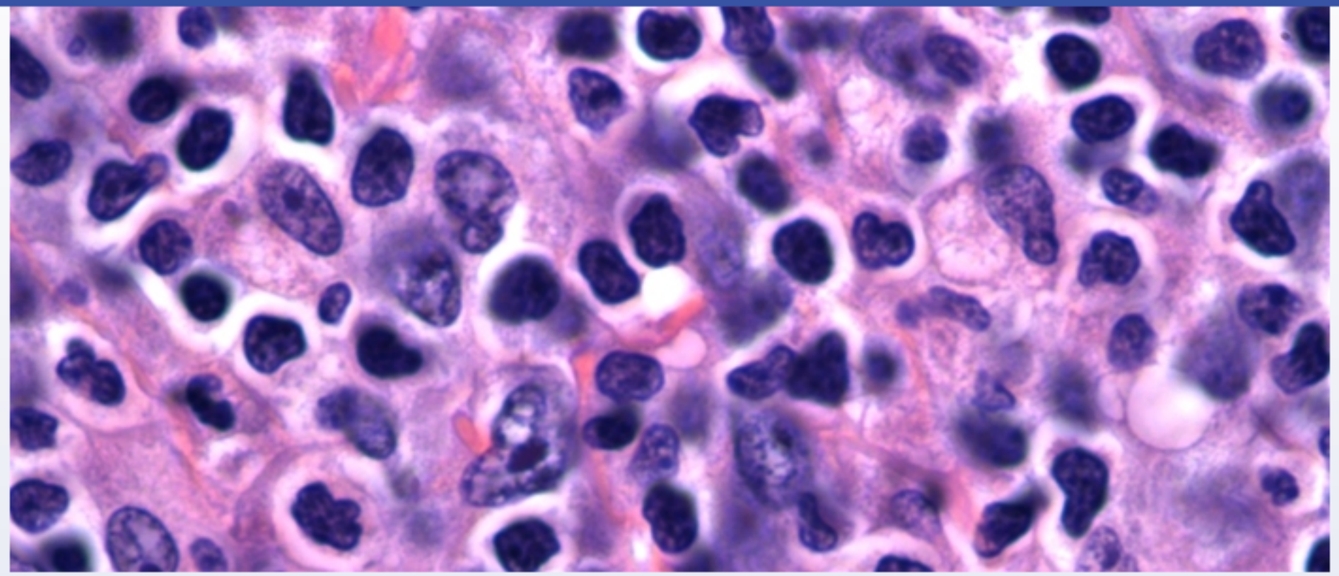

An abnormality in which of the following tissues is most likely responsible for this patient's symptoms?

- A. Respiratory epithelium (6%)
- B. Thyroid gland (7%)
- ✓ C. Lymphoid tissue (78%)
- D. Myeloid precursors (7%)
- E. Skin epithelium (0%)

Omitted
Correct answer

78%
Answered correctly

06 secs
Time Spent

02/03/2020
Last Updated

1
2
3
4
5
6
7
8
9
10
11
12
13
14
15
16
17
18
19
20
21
22
23
24
25
26
27
28
29
30

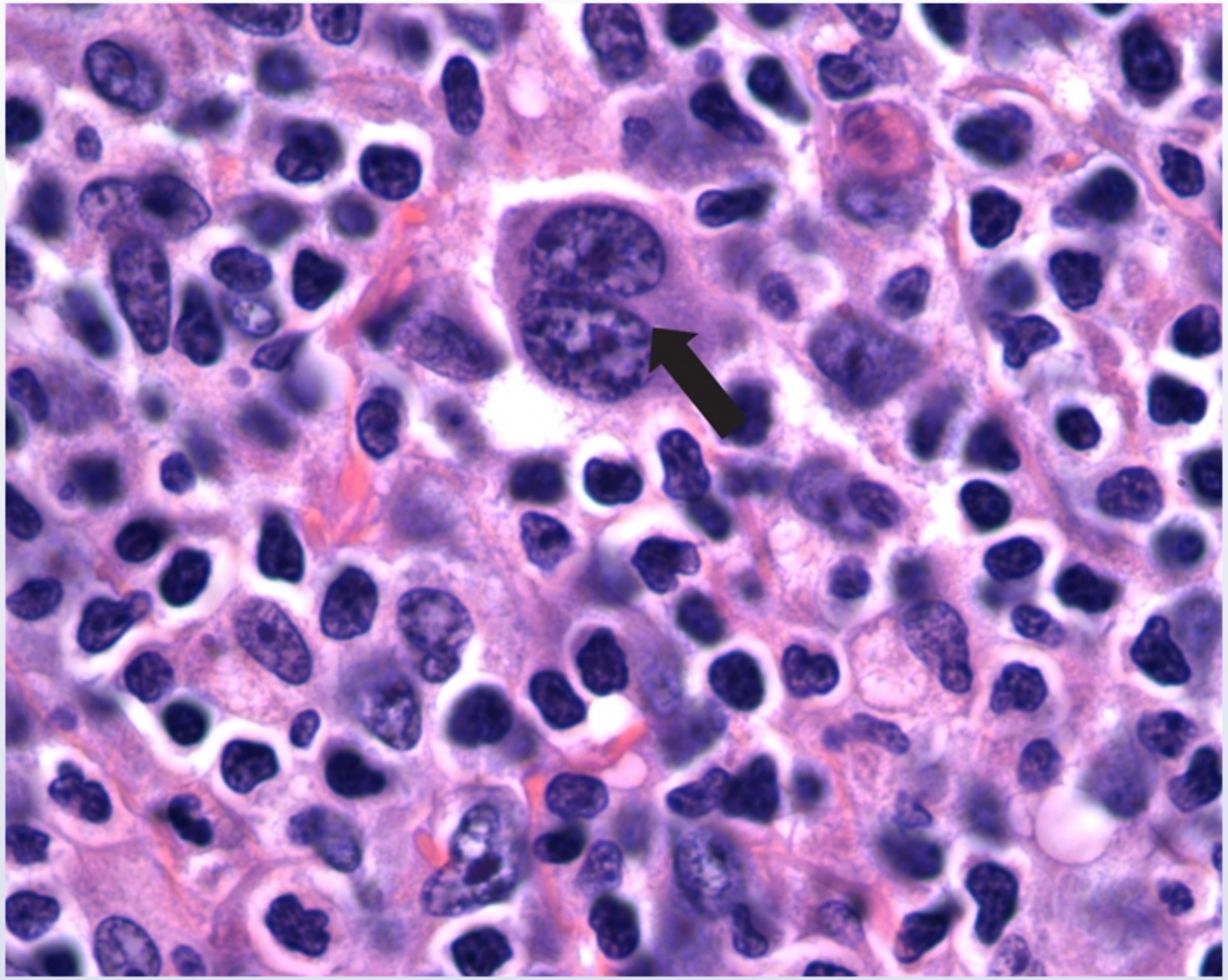

In order to answer this question, you must be able to recognize the characteristic histology. The tissue biopsy shows numerous lymphocytes (small cells with dark, round nuclei and a small rim of cytoplasm), meaning that it was most likely taken from a lymph node. The key finding is the

In order to answer this question, you must be able to recognize the characteristic histology. The tissue biopsy shows numerous lymphocytes (small cells with dark, round nuclei and a small rim of cytoplasm), meaning that it was most likely taken from a lymph node. The key finding is the giant binucleated cell, a Reed-Sternberg (RS) cell, in the center of the slide. RS cells are derived from germinal center B-lymphocytes and are the neoplastic cells of Hodgkin lymphoma (HL). RS cells must be present in order to make the diagnosis of HL. The two mirror-image nuclei of RS cells are often described as having the appearance of "owl's eyes."

(Choice A) The respiratory epithelium is a pseudostratified columnar ciliated epithelium that extends down to the level of the bronchioles. At the bronchioles, the epithelium gradually becomes cuboidal and then transitions to a flat, single-celled alveolar lining of Type I pneumocytes.

(Choice B) A goiter may cause neck swelling. Histologically, Hashimoto thyroiditis has the appearance of lymphocytes infiltrating between thyroid follicles.

(Choice D) Reed-Sternberg cells are not associated with leukemia. The classic finding in patients with leukemia is a peripheral blood smear with leukemic cells, leukocytosis and thrombocytopenia.

(Choice E) Both melanoma and squamous cell carcinoma can metastasize from the skin causing lymphadenopathy. The cells on this tissue biopsy show no evidence of squamous or melanocytic differentiation, however.

Educational Objective:
Reed-Sternberg cells are large binucleated cells with an "owl's eyes" appearance that appear on a background of lymphocytic infiltrates. Reed-Sternberg cells must be present histopathologically in order to make the diagnosis of Hodgkin lymphoma.

Pathology	Hematology & Oncology	Hodgkins lymphoma
Subject	System	Topic

Copyright © UWorld. All rights reserved.

A 15-year-old girl is evaluated due to persistent fever, fatigue, and sore throat. Physical examination reveals splenomegaly and symmetric posterior cervical lymphadenopathy. Peripheral blood smear results are shown in the image below:

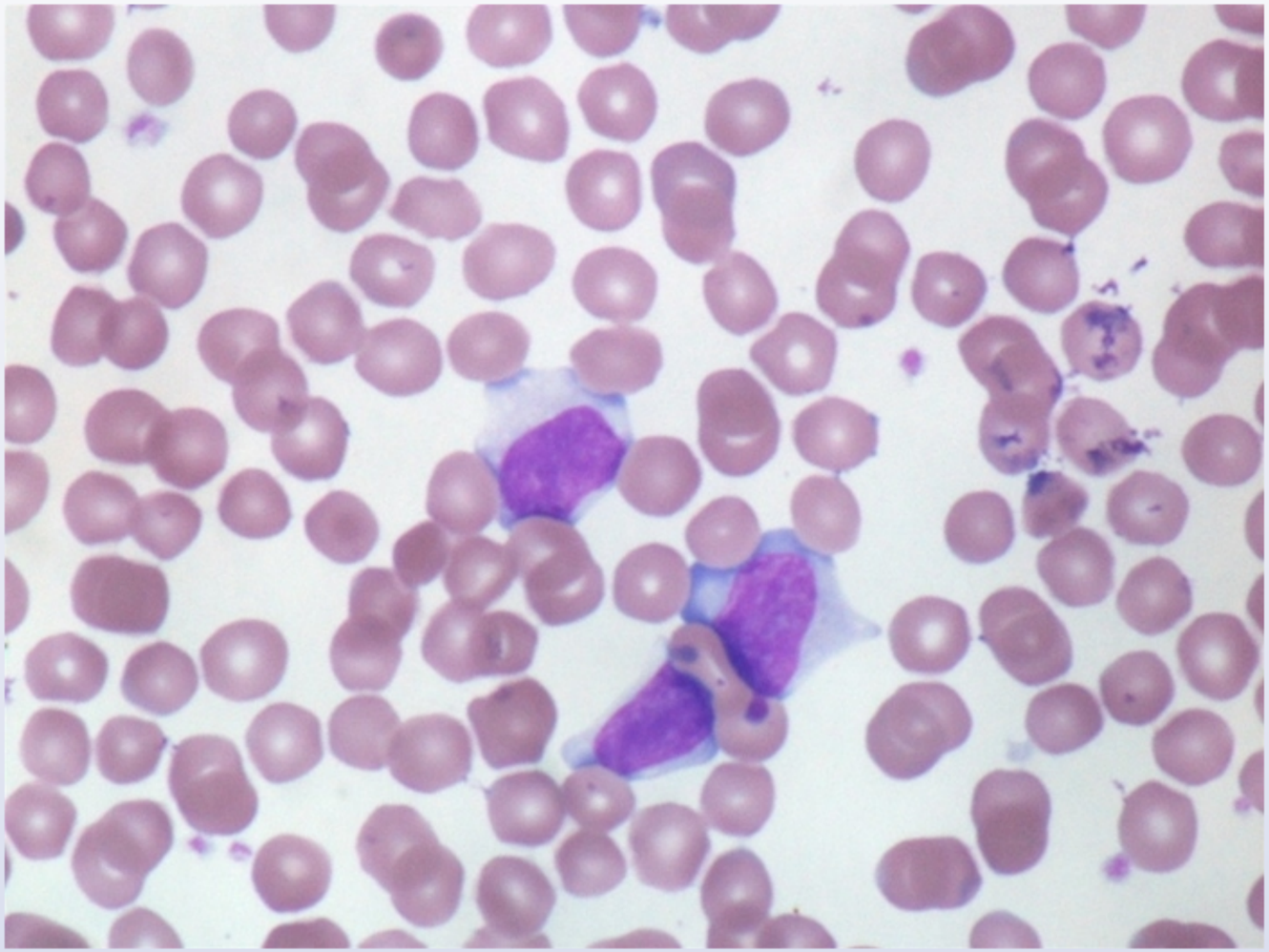

The atypical cells seen here are most likely an activated form of which of the following?

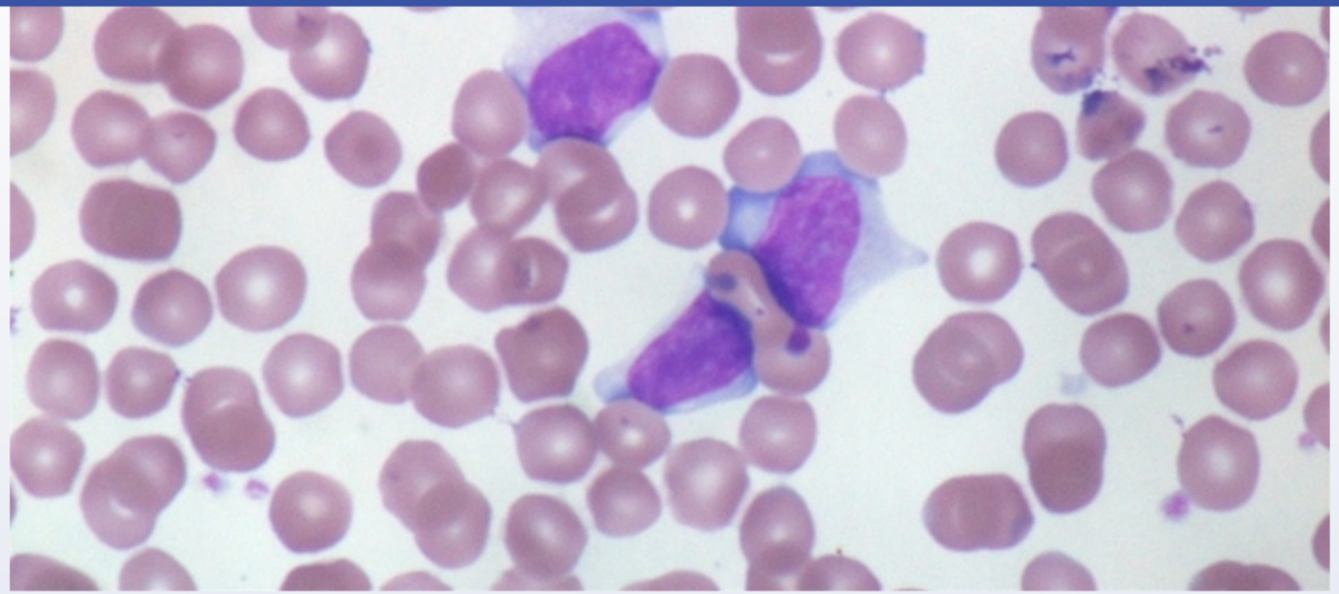

The atypical cells seen here are most likely an activated form of which of the following?

- A. $CD4^+$ Helper lymphocytes
- B. $CD8^+$ Cytotoxic lymphocytes
- C. $CD14^+$ Monocytes
- D. $CD21^+$ Lymphocytes
- E. $CD27^+$ Plasma cells

Submit

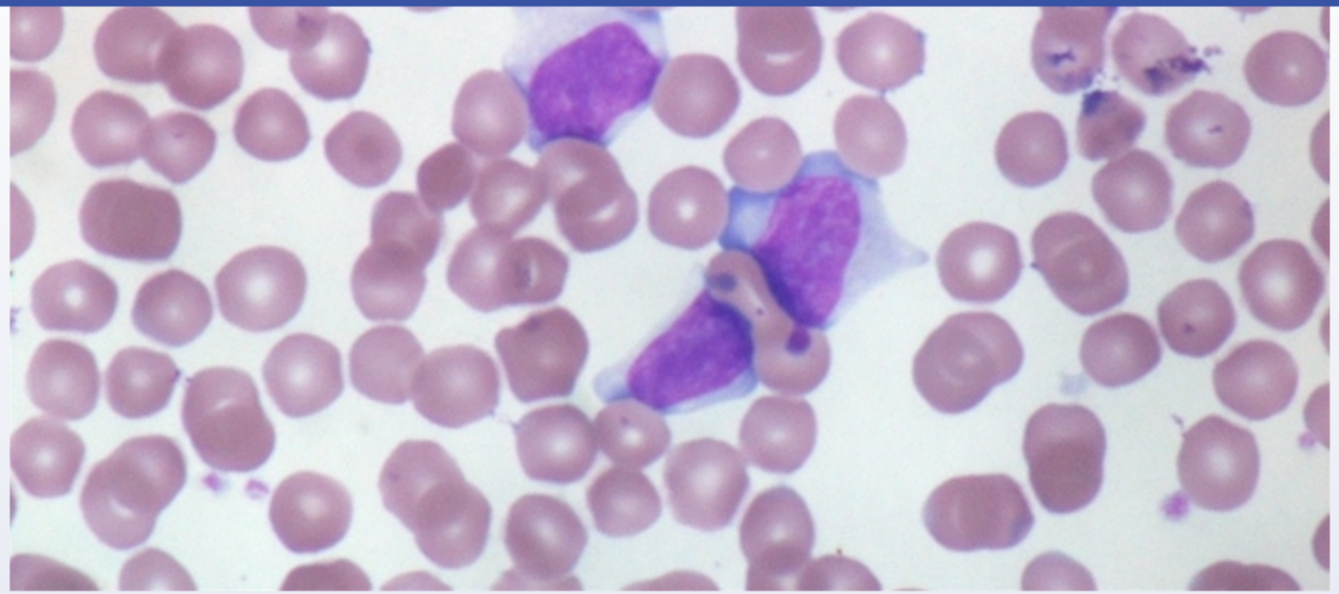

The atypical cells seen here are most likely an activated form of which of the following?

- A. CD4+ Helper lymphocytes (9%)
- ✓ B. CD8+ Cytotoxic lymphocytes (52%)
- C. CD14+ Monocytes (7%)
- D. CD21+ Lymphocytes (27%)
- E. CD27+ Plasma cells (3%)

Omitted
Correct answer

52%
Answered correctly

04 secs
Time Spent

04/08/2020
Last Updated

1
2
3
4
5
6
7
8
9
10
11
12
13
14
15
16
17
18
19
20
21
22
23
24
25
26
27
28
29
30

Atypical CD8+ T lymphocyte

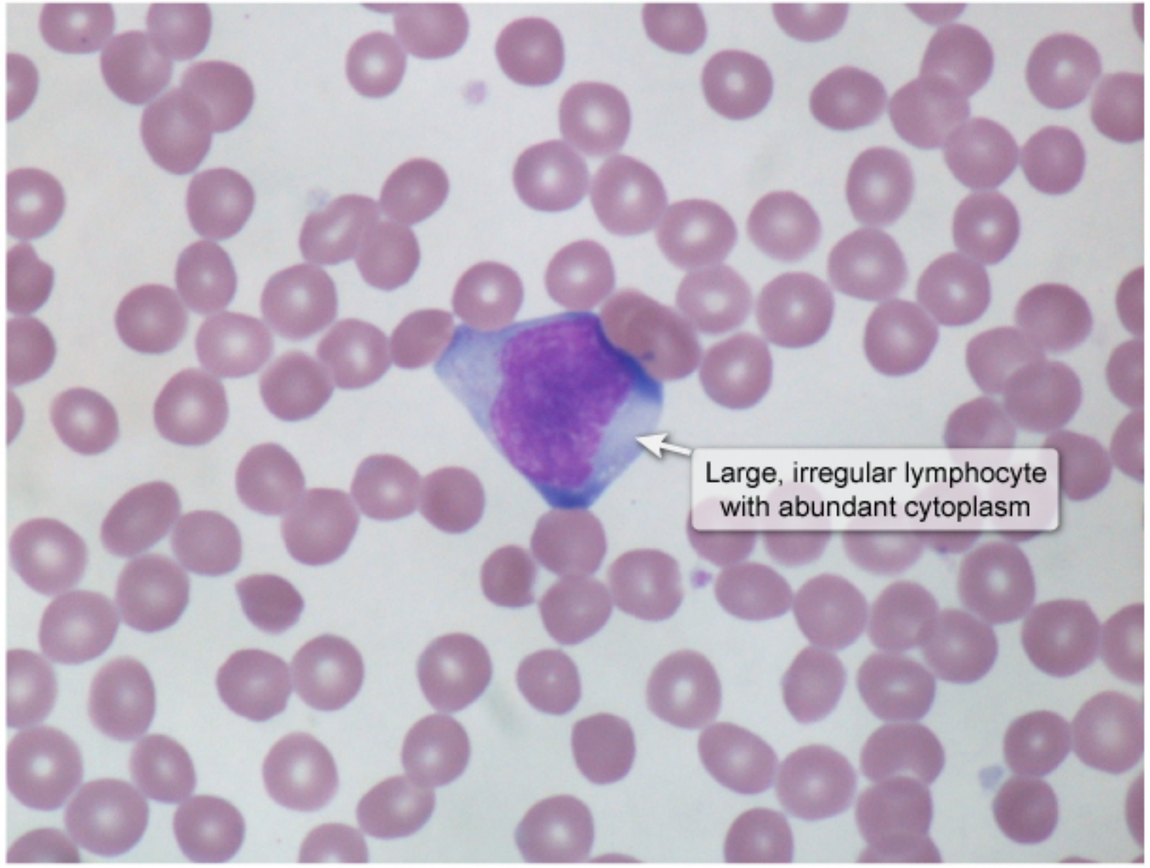

This patient has fever, fatigue, sore throat, splenomegaly, symmetric posterior cervical lymphadenopathy, and atypical lymphocytosis characteristic of **infectious mononucleosis** (IM). After entering the bloodstream through the pharyngeal mucosa and tonsillar crypts, the **Epstein-Barr virus** (EBV) preferentially infects B lymphocytes by binding to CD21 cell surface receptors. EBV-infected B lymphocytes then activate **cytotoxic T lymphocytes (CD8⁺)** through the presentation of viral antigens on major histocompatibility complex class I molecules. These reactive (atypical)

This patient has fever, fatigue, sore throat, splenomegaly, symmetric posterior cervical lymphadenopathy, and atypical lymphocytosis characteristic of **infectious mononucleosis** (IM). After entering the bloodstream through the pharyngeal mucosa and tonsillar crypts, the **Epstein-Barr virus** (EBV) preferentially infects B lymphocytes by binding to CD21 cell surface receptors. EBV-infected B lymphocytes then activate **cytotoxic T lymphocytes (CD8⁺)** through the presentation of viral antigens on major histocompatibility complex class I molecules. These reactive (atypical) CD8⁺ T lymphocytes are the primary immune response to EBV and clonally expand to destroy virus-infected cells.

Atypical lymphocytes make up more than 10% of the cells in a peripheral blood smear in IM, and most (>95%) of those cells are CD8⁺ T lymphocytes. They classically appear as **irregular cells** much larger than quiescent lymphocytes, with abundant basophilic cytoplasm and a cell membrane that appears to conform to the borders of neighboring cells. Although activated CD21⁺ B lymphocytes and CD4⁺ helper T lymphocytes can have a similar appearance in response to EBV infection, they make up <5% of the atypical lymphocytes in the peripheral circulation **(Choices A and D)**.

(Choice C) Monocytosis (eg, juvenile myelomonocytic leukemia) can be associated with persistent fever, fatigue, and splenomegaly; however, peripheral blood smear would show proliferation of blasts and dysplastic monocytes rather than atypical lymphocytes.

(Choice E) Activated plasma cells appear on histology as ovoid cells with abundant cytoplasm and an eccentric nucleus with a spoke-wheel chromatin pattern. A zone of perinuclear clearing within the cytoplasm may also be noted, corresponding to the active Golgi body.

Educational objective:
The primary immune response to Epstein-Barr virus is mediated by CD8⁺ T lymphocytes, which are activated through the presentation of viral antigens on infected CD21⁺ B lymphocytes. These reactive (atypical) CD8⁺ T lymphocytes can be observed in the peripheral blood smears of patients with infectious mononucleosis.

Pathology	Hematology & Oncology	Infectious mononucleosis
Subject	System	Topic

Copyright © UWorld. All rights reserved.

Exhibit Display

Leukocytes in peripheral blood

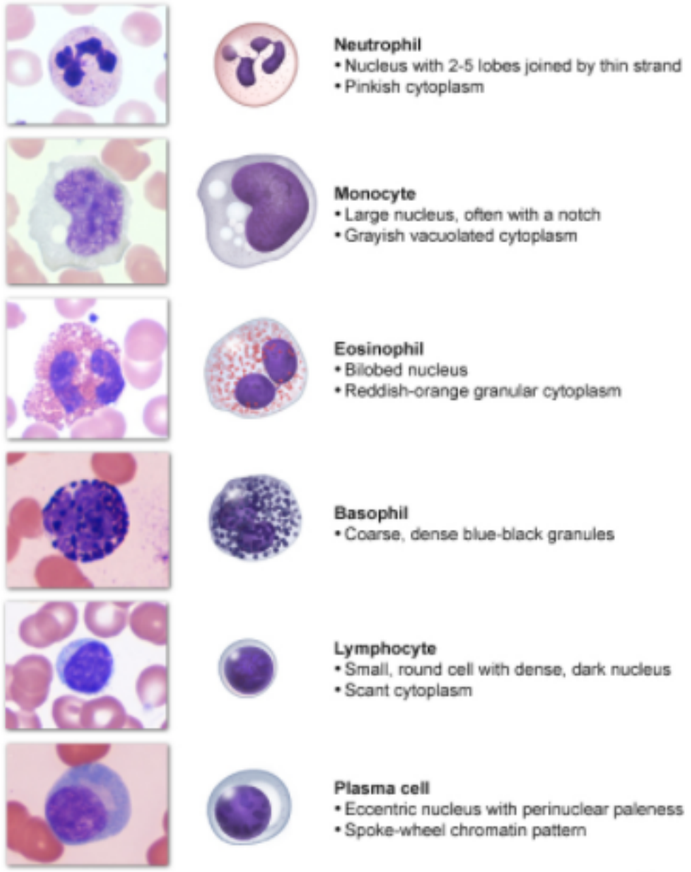

©UWorld

Zoom In | Zoom Out | Reset | Add To New Card | Existing Card

Exhibit Display

Monocytosis

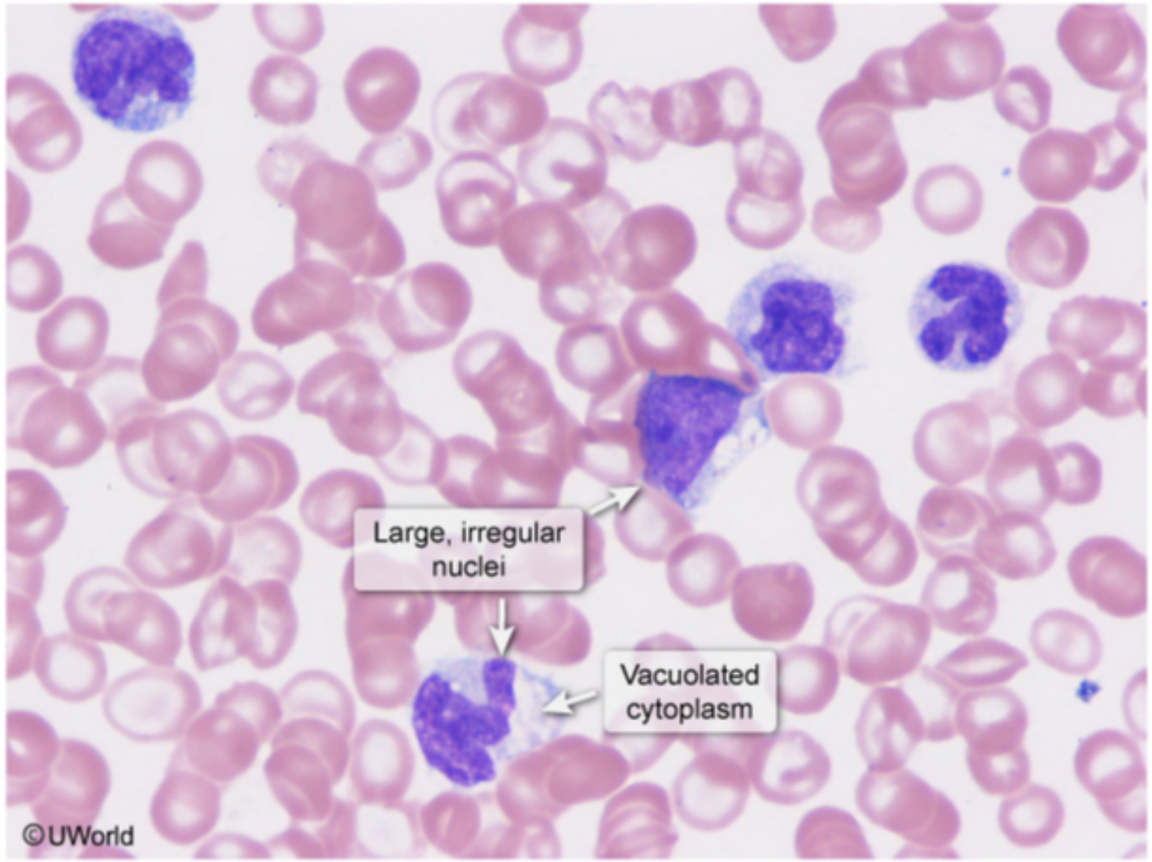

Zoom In | Zoom Out | Reset | Add To New Card | Existing Card

A 52-year-old man comes to the physician complaining of dizziness, headaches, and pruritus after showering. He has smoked half a pack of cigarettes daily for the past fifteen years and drinks alcohol socially. Physical examination shows a reddish facial complexion and mild splenomegaly. Laboratory results are as follows:

Complete blood count

Hemoglobin	19 g/dL
Hematocrit	59%
Erythrocytes	7.5 million/μL
Platelets	550,000 /μL
Leukocytes	15,600 /μL

Which of the following is the most likely cause of this patient's findings?

A. Decreased circulating plasma volume

B. Decreased blood oxygen saturation

C. Increased bone marrow sensitivity to growth factors

D. Increased red blood cell life span

E. Increased serum erythropoietin levels

Submit

A 52-year-old man comes to the physician complaining of dizziness, headaches, and pruritus after showering. He has smoked half a pack of cigarettes daily for the past fifteen years and drinks alcohol socially. Physical examination shows a reddish facial complexion and mild splenomegaly. Laboratory results are as follows:

Complete blood count

Hemoglobin	19 g/dL
Hematocrit	59%
Erythrocytes	7.5 million/μL
Platelets	550,000 /μL
Leukocytes	15,600 /μL

Which of the following is the most likely cause of this patient's findings?

A. Decreased circulating plasma volume (6%)
B. Decreased blood oxygen saturation (4%)
✓ C. Increased bone marrow sensitivity to growth factors (56%)
D. Increased red blood cell life span (3%)
E. Increased serum erythropoietin levels (29%)

Omitted
Correct answer

56%
Answered correctly

01 sec
Time Spent

04/05/2020
Last Updated

1
2
3
4
5
6
7
8
9
10
11
12
13
14
15
16
17
18
19
20
21
22
23
24
25
26
27
28
29
30

Causes of polycythemia

	Etiology	Plasma volume	RBC mass	SaO_2	EPO level
Relative polycythemia	Dehydration, excessive diureses	Decreased	Normal	Normal	Normal
Primary polycythemia*	Polycythemia vera	Increased	Increased	Normal	Decreased
Secondary polycythemia*	Physiologic (eg, hypoxia)	Normal	Increased	Decreased	Increased
	Inappropriate (eg, EPO-producing tumors)	Normal	Increased	Normal	Increased

* Primary & secondary polycythemias are absolute polycythemias.

©UWorld

Polycythemia vera (PV) is a clonal myeloproliferative disease of pluripotent hematopoietic stem cells. Approximately 95% of patients with PV have a V617F mutation involving the JAK2 gene, which is involved in signal transduction. This mutation replaces a valine with phenylalanine at the 617 position, rendering hematopoietic cells **more sensitive to growth factors** such as erythropoietin and thrombopoietin.

PV presents with **increased RBC mass**, increased plasma volume, and **low erythropoietin** levels. Additional manifestations can include an **elevated platelet** and/or **WBC count**, thrombotic events (from blood hyperviscosity), peptic ulceration and aquagenic pruritus (due to histamine

Polycythemia vera (PV) is a clonal myeloproliferative disease of pluripotent hematopoietic stem cells. Approximately 95% of patients with PV have a V617F mutation involving the JAK2 gene, which is involved in signal transduction. This mutation replaces a valine with phenylalanine at the 617 position, rendering hematopoietic cells **more sensitive to growth factors** such as erythropoietin and thrombopoietin.

PV presents with **increased RBC mass**, increased plasma volume, and **low erythropoietin** levels. Additional manifestations can include an **elevated platelet** and/or **WBC count**, thrombotic events (from blood hyperviscosity), peptic ulceration and aquagenic pruritus (due to histamine release from basophils), and gouty arthritis (from increased cell turnover). Physical examination typically shows a plethoric, reddened face and splenomegaly. Diagnosis is established by confirming low serum erythropoietin levels and bone marrow aspiration cytogenetic studies showing a **JAK2 mutation**. Treatment involves serial phlebotomy as necessary to keep the hematocrit < 45%.

(Choice A) Dehydration or excessive diuresis can also cause elevated hematocrit, mild leukocytosis, and thrombocytosis due to low effective circulating volume. However, splenomegaly and symptoms such as pruritus would not be seen.

(Choice B) Hypoxia is a strong stimulus for erythropoietin production. SaO_2 < 92% (PaO_2 < 65 mm Hg) appears to be the threshold for the development of (physiologic) secondary polycythemia. Conditions such as chronic obstructive pulmonary disease and obstructive sleep apnea can cause secondary polycythemia. However, these will not cause leukocytosis, thrombocytosis, or splenomegaly.

(Choice D) Increased red cell life span would not be expected to cause leukocytosis and thrombocytosis.

(Choice E) EPO-producing tumors (eg, renal cell carcinoma, hepatocellular carcinoma) can cause secondary polycythemia due to abnormal erythropoietin production. Workup will show an elevated erythropoietin level. However, the combination of multiple elevated cell lines and splenomegaly is unlikely to result from a process causing secondary polycythemia.

Educational objective:
Polycythemia vera (PV) is a clonal myeloproliferative disease characterize by an increased RBC mass, increased plasma volume, and low erythropoietin levels. PV can be differentiated from secondary polycythemia by the presence of leukocytosis, thrombocytosis, and/or splenomegaly. The majority of patients with PV have a JAK2 mutation rendering hematopoietic stem cells more sensitive to growth factors.

References

- Polycythemia vera.

1
2
3
4
5
6
7
8
9
10
11
12
13
14
15
16
17
18
19
20
21
22
23
24
25
26
27
28
29
30

A 59-year-old man comes to the office due to 3 months of progressive fatigue and back pain. The back pain occurs mainly with movement or positional changes. Physical examination reveals midline tenderness over the middle and lower back. Laboratory evaluation shows a hemoglobin level of 10.2 g/dL and serum calcium level of 12 mg/dL. A bone marrow aspirate is performed, and the histopathologic findings are shown below.

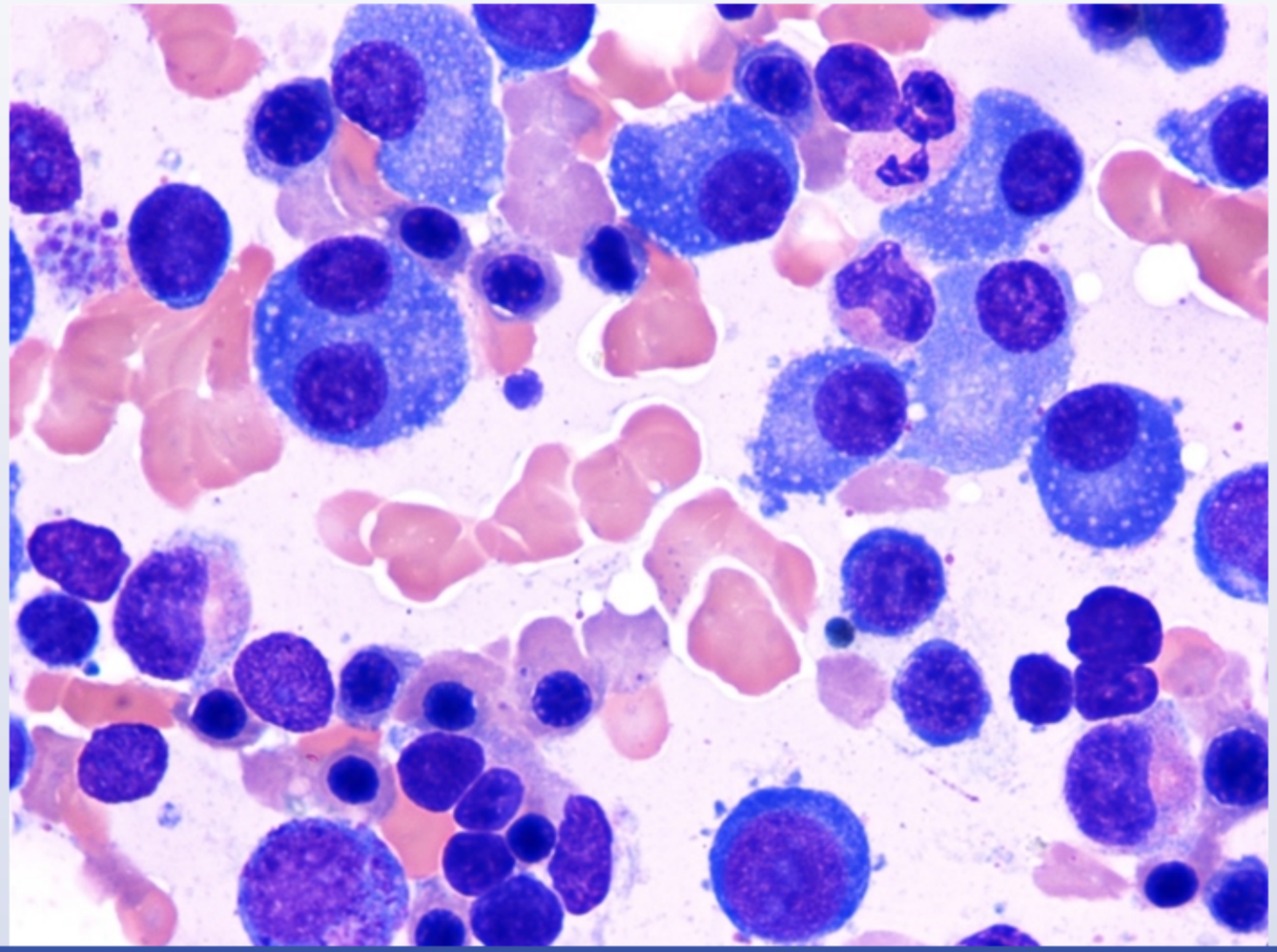

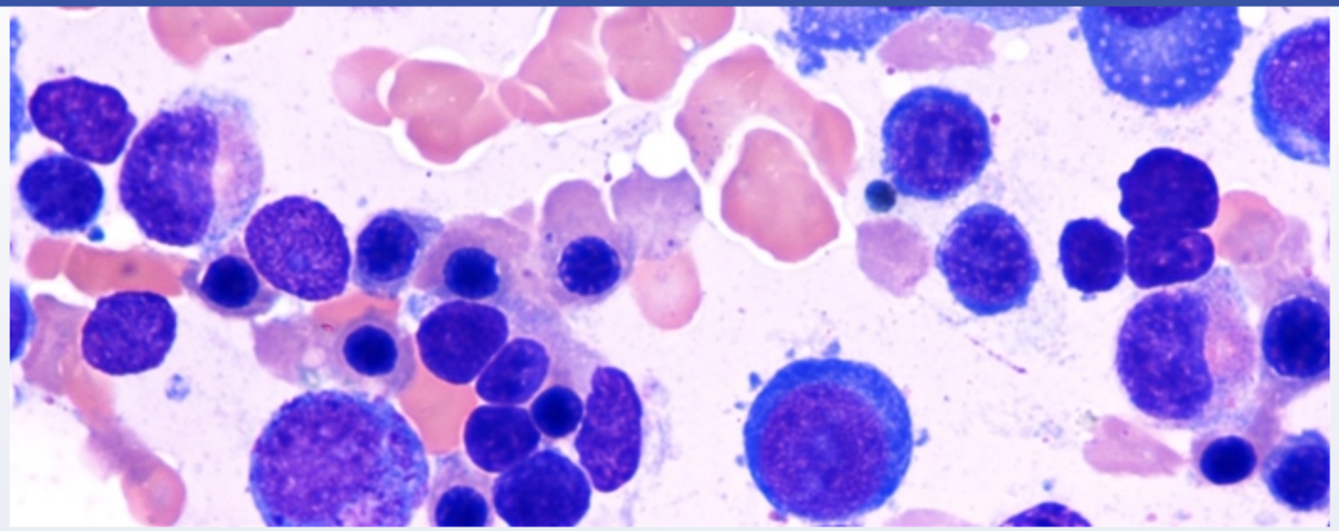

This patient is at greatest risk for which of the following?

- A. Amyloidosis
- B. Cardiac tamponade
- C. Hepatic failure
- D. Hyperthyroidism
- E. Meningeal carcinomatosis
- F. Splenic rupture

Submit

1
2
3
4
5
6
7
8
9
10
11
12
13
14
15
16
17
18
19
20
21
22
23
24
25
26
27
28
29
30

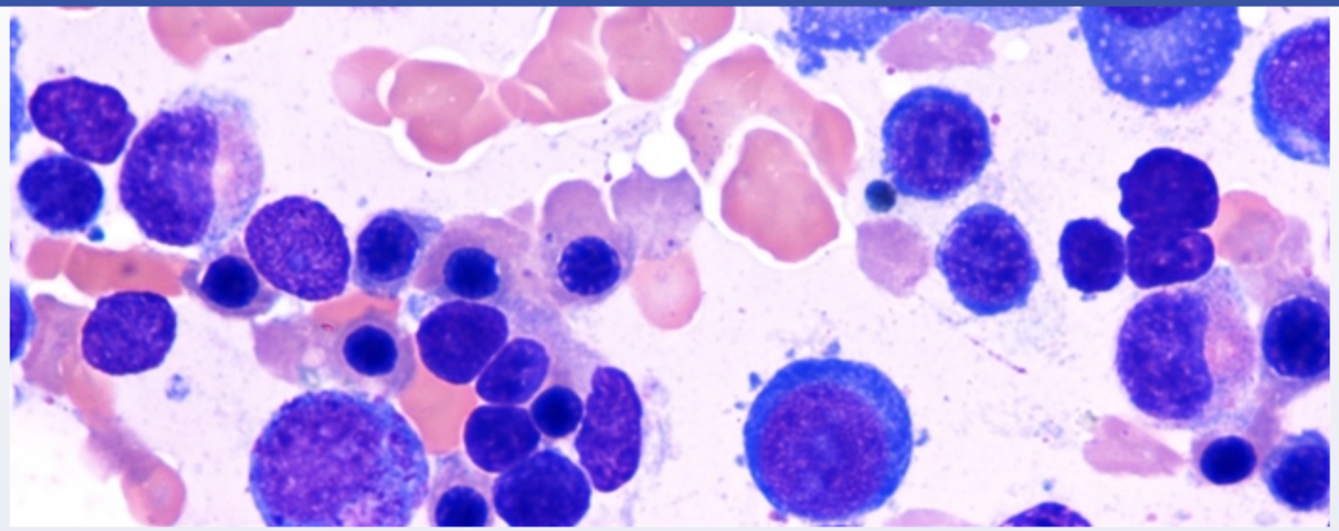

This patient is at greatest risk for which of the following?

- ✓ A. Amyloidosis (69%)
- B. Cardiac tamponade (2%)
- C. Hepatic failure (5%)
- D. Hyperthyroidism (1%)
- E. Meningeal carcinomatosis (3%)
- F. Splenic rupture (17%)

Omitted
Correct answer

69%
Answered correctly

04 secs
Time Spent

05/29/2020
Last Updated

Explanation

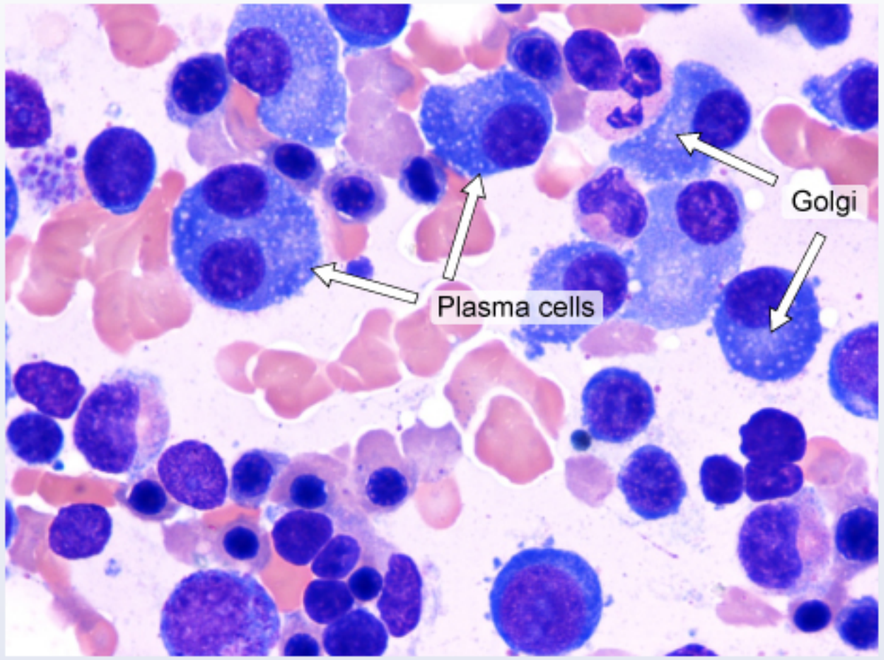

This patient's bone marrow aspirate shows **numerous plasma cells**, which can be identified by abundant basophilic cytoplasm, well-developed Golgi apparatus (perinuclear paleness), and "clock-face" (peripheral) chromatin. A bone marrow sample with >10% plasma cells is strongly suggestive of **multiple myeloma** (MM), a clonal plasma cell malignancy.

In MM, neoplastic plasma cells:

- Replicate in the bone marrow and choke out normal hematopoiesis, leading to **normocytic**, **normochromic anemia** (impaired erythropoiesis) and increased risk of infection (impaired B-cell lymphopoiesis).
- Secrete osteolytic cytokines, leading to bone pain, osteolytic (radiolucent) bone lesions, and **hypercalcemia**.
- Produce large quantities of **monoclonal immunoglobulin** (paraprotein) composed of heavy and light chains (eg, IgG, IgA) or light chains

This patient's bone marrow aspirate shows **numerous plasma cells**, which can be identified by abundant basophilic cytoplasm, well-developed Golgi apparatus (perinuclear paleness), and "clock-face" (peripheral) chromatin. A bone marrow sample with >10% plasma cells is strongly suggestive of **multiple myeloma** (MM), a clonal plasma cell malignancy.

In MM, neoplastic plasma cells:

- Replicate in the bone marrow and choke out normal hematopoiesis, leading to **normocytic**, **normochromic anemia** (impaired erythropoiesis) and increased risk of infection (impaired B-cell lymphopoiesis).
- Secrete osteolytic cytokines, leading to bone pain, osteolytic (radiolucent) bone lesions, and **hypercalcemia**.
- Produce large quantities of **monoclonal immunoglobulin** (paraprotein) composed of heavy and light chains (eg, IgG, IgA) or light chains alone. Light chains can deposit in the renal tubules, leading to **light-chain cast nephropathy**, which is usually characterized by mild renal insufficiency and waxy, laminated urinary casts (Bence Jones).
- Light chains can also form **insoluble fibrils** and deposit in major organs, leading to **amyloid light-chain amyloidosis**. This can contribute to the already elevated risk of renal failure as well as heart failure and neurologic dysfunction. Amyloidosis can often be identified on biopsy using hematoxylin and eosin stain (eosinophilic extracellular deposits) or Congo red stain viewed under polarized light (apple-green birefringence).

(Choice B) Cardiac tamponade can be associated with some neoplasms (eg, lung, breast, Hodgkin disease, melanoma) due to tumor invasion of the pericardium. MM does not typically cause pericardial disease; therefore, it is not associated with cardiac tamponade.

(Choice C) Hepatic failure is most often linked to viral hepatitis or alcohol abuse. It occasionally occurs due to malignant infiltration of the liver with metastatic breast cancer, small cell lung cancer, melanoma, or lymphoma. Risk of hepatic failure with MM is low; amyloidosis is far more common.

(Choice D) Hyperthyroidism is most often due to Graves disease, an autoimmune disorder that generates TSH-receptor antibodies. It can also be seen with medications (eg, lithium) and tumors that produce TSH (eg, pituitary adenoma). MM is not linked to hyperthyroidism.

(Choice E) Meningeal carcinomatosis is a rare condition associated with some solid tumors (eg, breast cancer, lung cancer, melanoma). Tumor spread to the leptomeninges can cause mass effect (eg, headache, hydrocephalus), cranial/spinal nerve dysfunction, and focal neurologic issues.

1
2
3
4
5
6
7
8
9
10
11
12
13
14
15
16
17
18
19
20
21
22
23
24
25
26
27
28
29
30

alone. Light chains can deposit in the renal tubules, leading to **light-chain cast nephropathy**, which is usually characterized by mild renal insufficiency and waxy, laminated urinary casts (Bence Jones).

- Light chains can also form **insoluble fibrils** and deposit in major organs, leading to **amyloid light-chain amyloidosis**. This can contribute to the already elevated risk of renal failure as well as heart failure and neurologic dysfunction. Amyloidosis can often be identified on biopsy using hematoxylin and eosin stain (eosinophilic extracellular deposits) or Congo red stain viewed under polarized light (apple-green birefringence).

(Choice B) Cardiac tamponade can be associated with some neoplasms (eg, lung, breast, Hodgkin disease, melanoma) due to tumor invasion of the pericardium. MM does not typically cause pericardial disease; therefore, it is not associated with cardiac tamponade.

(Choice C) Hepatic failure is most often linked to viral hepatitis or alcohol abuse. It occasionally occurs due to malignant infiltration of the liver with metastatic breast cancer, small cell lung cancer, melanoma, or lymphoma. Risk of hepatic failure with MM is low; amyloidosis is far more common.

(Choice D) Hyperthyroidism is most often due to Graves disease, an autoimmune disorder that generates TSH-receptor antibodies. It can also be seen with medications (eg, lithium) and tumors that produce TSH (eg, pituitary adenoma). MM is not linked to hyperthyroidism.

(Choice E) Meningeal carcinomatosis is a rare condition associated with some solid tumors (eg, breast cancer, lung cancer, melanoma). Tumor spread to the leptomeninges can cause mass effect (eg, headache, hydrocephalus), cranial/spinal nerve dysfunction, and focal neurologic issues. MM does not typically spread to the leptomeninges.

(Choice F) Atraumatic splenic rupture can occur with leukemia and lymphoma due to massive splenomegaly from extramedullary hematopoiesis and/or underlying tumor infiltration. MM does not typically cause significant extramedullary hematopoiesis and usually replicates in the bone marrow, not the spleen.

Educational objective:
Amyloid light-chain amyloidosis is associated with multiple myeloma and other monoclonal plasma cell dyscrasias due to the deposition of insoluble immunoglobulin light-chain fibrils in major organs (eg, kidneys, heart, neurologic system). A bone marrow sample with >10% plasma cells is strongly suggestive of multiple myeloma.

References

- Replicate in the bone marrow and choke out normal hematopoiesis, leading to **normocytic**, **normochromic anemia** (impaired

Exhibit Display



Zoom In | Zoom Out | Reset | Add To New Card | Existing Card

(Choice B) Cardiac tamponade can be associated with some neoplasms (eg, lung, breast, Hodgkin disease, melanoma) due to tumor invasion of the pericardium. MM does not typically cause pericardial disease; therefore, it is not associated with cardiac tamponade.

(Choice C) Hepatic failure is most often linked to viral hepatitis or alcohol abuse. It occasionally occurs due to malignant infiltration of the liver with metastatic breast cancer, small cell lung cancer, melanoma, or lymphoma. Risk of hepatic failure with MM is low; amyloidosis is far more common.

(Choice D) Hyperthyroidism is most often due to Graves disease, an autoimmune disorder that generates TSH-receptor antibodies. It can also be seen with medications (eg, lithium) and tumors that produce TSH (eg, pituitary adenoma). MM is not linked to hyperthyroidism.

(Choice E) Meningeal carcinomatosis is a rare condition associated with some solid tumors (eg, breast cancer, lung cancer, melanoma). Tumor spread to the leptomeninges can cause mass effect (eg, headache, hydrocephalus), cranial/spinal nerve dysfunction, and focal neurologic issues. MM does not typically spread to the leptomeninges.

(Choice F) Atraumatic splenic rupture can occur with leukemia and lymphoma due to massive splenomegaly from extramedullary hematopoiesis and/or underlying tumor infiltration. MM does not typically cause significant extramedullary hematopoiesis and usually replicates in the bone marrow, not the spleen.

Educational objective:
Amyloid light-chain amyloidosis is associated with multiple myeloma and other monoclonal plasma cell dyscrasias due to the deposition of insoluble immunoglobulin light-chain fibrils in major organs (eg, kidneys, heart, neurologic system). A bone marrow sample with >10% plasma cells is strongly suggestive of multiple myeloma.

References

- Clinical features and treatment response of light chain (AL) amyloidosis diagnosed in patients with previous diagnosis of multiple myeloma.

Pathology	Hematology & Oncology	Multiple myeloma
Subject	System	Topic

Copyright © UWorld. All rights reserved.

1 2 3 4 5 6 7 8 9 10 11 12 13 14 15 16 17 18 19 20 21 22 23 24 25 26 27 28 29 30

1
2
3
4
5
6
7
8
9
10
11
12
13
14
15
16
17
18
19
20
21
22
23
24
25
26
27
28
29
30

A 35-year-old man comes to the physician with a skin rash. He was treated in the hospital for pneumocystic pneumonia and painful oral ulcers 6 months ago. He currently takes no medications but drinks alcohol frequently and uses illicit drugs. Physical examination shows a widespread rash consisting of lesions similar to that shown in the image below.

Which of the following is the most likely cause of this patient's current condition?

A. Arsenic exposure

B. Cytomegalovirus

C. Epstein-Barr virus



Which of the following is the most likely cause of this patient's current condition?

A. Arsenic exposure
B. Cytomegalovirus
C. Epstein-Barr virus
D. Hepatitis C virus
E. Herpes simplex virus type 1
F. Human herpes virus type 8
G. Human papilloma virus
H. Human T-cell leukemia virus type 1
I. Ultraviolet radiation
J. Vinyl chloride exposure

Submit



Which of the following is the most likely cause of this patient's current condition?

- A. Arsenic exposure (0%)
- B. Cytomegalovirus (2%)
- C. Epstein-Barr virus (3%)
- D. Hepatitis C virus (2%)
- E. Herpes simplex virus type 1 (2%)
- ✓ F. Human herpes virus type 8 (77%)
- G. Human papilloma virus (1%)
- H. Human T-cell leukemia virus type 1 (7%)
- I. Ultraviolet radiation (1%)
- J. Vinyl chloride exposure (0%)

Omitted
Correct answer

77%
Answered correctly

03 secs
Time Spent

05/21/2020
Last Updated

1
2
3
4
5
6
7
8
9
10
11
12
13
14
15
16
17
18
19
20
21
22
23
24
25
26
27
28
29
30

1
2
3
4
5
6
7
8
9
10
11
12
13
14
15
16
17
18
19
20
21
22
23
24
25
26
27
28
29
30

Explanation

The clinical history of pneumocystic pneumonia and painful oral ulcers in an illicit drug user is highly suggestive of HIV infection, a diagnosis further supported by the presence of Kaposi's sarcoma (KS).

The most common tumor in HIV-positive individuals, KS presents as multiple blue-violet or brownish dermal plaques that first appear on the feet and legs before spreading proximally. KS lesions can also develop on the mucosal membranes of the face and genitals. In patients with late-stage disease, the lesions spread to the lungs and gastrointestinal tract. Histologic examination of skin afflicted with Kaposi's sarcoma shows spindle and endothelial cell proliferation, red blood cell extravasation, and inflammation.

KS is strongly associated with both HIV and the human herpes virus type 8 (HHV-8); HHV-8 DNA has been isolated in the neoplastic cells of KS. HHV-8 infects vascular and lymphatic endothelial cells, causing their differentiation into a mixed phenotype that is thought to increase oncogenic potential. The HHV-8 genome also contains several viral oncogenes that inhibit both cell cycle regulation and apoptosis, thus promoting tumorigenesis.

(Choice B) Cytomegalovirus (CMV) infection in HIV patients typically cause esophagitis, colitis, and retinitis. CMV can also cause a mononucelosis like illness with rash; but the rash usually has a maculopapular/morbilliform appearance.

(Choice C) Like HHV-8, Epstein-Barr virus also belongs to *Herpesviridae*. Epstein-Barr virus causes infectious mononucleosis and is associated with Burkitt lymphoma, nasopharyngeal carcinoma, and central nervous system lymphoma in HIV-positive patients.

(Choice D) Chronic infection with hepatitis C virus increases the risk of developing hepatocellular carcinoma.

(Choice G) Human papilloma virus strains 16, 18, 31, and 33 are associated with squamous cell carcinoma of the cervix and vulva.

(Choice H) Human T-cell leukemia virus type1 (HTLV-1) belongs to *Retroviridae*. It causes T-cell leukemia, especially in patients originating from southern Japan.

Educational objective:
Kaposi's sarcoma typically presents as blue-violet or brownish skin plaques on the extremities and mucous membranes of HIV-positive patients. This tumor arises from primitive mesenchymal cells and is strongly associated with human herpes virus type 8.

spindle and endothelial cell proliferation, red blood cell extravasation, and inflammation.

KS is strongly associated with both HIV and the human herpes virus type 8 (HHV-8); HHV-8 DNA has been isolated in the neoplastic cells of KS. HHV-8 infects vascular and lymphatic endothelial cells, causing their differentiation into a mixed phenotype that is thought to increase oncogenic potential. The HHV-8 genome also contains several viral oncogenes that inhibit both cell cycle regulation and apoptosis, thus promoting tumorigenesis.

(Choice B) Cytomegalovirus (CMV) infection in HIV patients typically cause esophagitis, colitis, and retinitis. CMV can also cause a mononucelosis like illness with rash; but the rash usually has a maculopapular/morbilliform appearance.

(Choice C) Like HHV-8, Epstein-Barr virus also belongs to *Herpesviridae*. Epstein-Barr virus causes infectious mononucleosis and is associated with Burkitt lymphoma, nasopharyngeal carcinoma, and central nervous system lymphoma in HIV-positive patients.

(Choice D) Chronic infection with hepatitis C virus increases the risk of developing hepatocellular carcinoma.

(Choice G) Human papilloma virus strains 16, 18, 31, and 33 are associated with squamous cell carcinoma of the cervix and vulva.

(Choice H) Human T-cell leukemia virus type1 (HTLV-1) belongs to *Retroviridae*. It causes T-cell leukemia, especially in patients originating from southern Japan.

Educational objective:
Kaposi's sarcoma typically presents as blue-violet or brownish skin plaques on the extremities and mucous membranes of HIV-positive patients. This tumor arises from primitive mesenchymal cells and is strongly associated with human herpes virus type 8.

References

- Lymphatic reprogramming by Kaposi sarcoma herpes virus promotes the oncogenic activity of the virus-encoded G-protein-coupled receptor.

Pathology	Hematology & Oncology	Kaposi sarcoma
Subject	System	Topic

Copyright © UWorld. All rights reserved.

1
2
3
4
5
6
7
8
9
10
11
12
13
14
15
16
17
18
19
20
21
22
23
24
25
26
27
28
29
30

A 62-year-old woman comes to the office with severe fatigue and progressive exertional dyspnea for the past 6 months. She reports several episodes of food getting stuck in her throat, especially when attempting to swallow large chunks of solid food. On physical examination, she has mucosal pallor and her tongue appears smooth and red. Additional findings are shown below.

Displayed with permission from DermNet NZ.

Supplementation with which of the following is most likely to improve this patient's condition?

A. Erythropoietin

B. Filgrastim

C. Folic acid

Displayed with permission from DermNet NZ.

Supplementation with which of the following is most likely to improve this patient's condition?

- A. Erythropoietin
- B. Filgrastim
- C. Folic acid
- D. Iron
- E. Pyridoxine
- F. Vitamin B_{12}
- G. Vitamin C

Submit

Displayed with permission from DermNet NZ.

Supplementation with which of the following is most likely to improve this patient's condition?

- A. Erythropoietin (2%)
- B. Filgrastim (1%)
- C. Folic acid (3%)
- ✓ D. Iron (78%)
- E. Pyridoxine (5%)
- F. Vitamin B_{12} (5%)
- G. Vitamin C (3%)

Omitted
Correct answer

78%
Answered correctly

03 secs
Time Spent

05/03/2020
Last Updated

1 2 3 4 5 6 7 8 9 10 11 12 13 14 15 16 17 18 19 20 21 22 23 24 25 26 27 28 29 30

Explanation

Plummer-Vinson syndrome (PVS) is a rare disease characterized by **dysphagia and iron deficiency anemia**. Patients develop weakness, fatigue, and dyspnea secondary to the anemia; dysphagia develops due to **esophageal web** formation. Other physical examination findings associated with iron deficiency include **koilonychia** (spoon-shaped nails) and a **shiny red tongue** secondary to atrophy of lingual papillae. PVS is treated with **iron supplementation**, which resolves the symptoms related to iron-deficiency anemia and often improves the dysphagia.

(Choice A) Erythropoietin is used to treat anemia associated with chronic renal failure and chemotherapy.

(Choice B) Filgrastim is a granulocyte colony-stimulating factor analog used to treat neutropenia in patients following chemotherapy or bone marrow transplant.

(Choices C and F) Deficiency of vitamin B_{12} or folic acid results in megaloblastic anemia. This patient's presentation is more specific for iron deficiency, which causes microcytic anemia.

(Choice E) Pyridoxine (vitamin B_6) is required as a cofactor for the first step in heme synthesis. Deficiency causes sideroblastic anemia, neurologic deficits, and dermatitis.

(Choice G) Vitamin C is sometimes added to improve oral absorption of non-heme iron, but would be ineffective without concurrent iron supplementation.

Educational objective:
Plummer-Vinson syndrome is characterized by dysphagia (esophageal web formation) and iron deficiency anemia. Findings associated with iron deficiency include koilonychia (spoon-shaped nails) and a shiny red tongue. Most symptoms resolve following iron supplementation.

References

- Plummer-Vinson syndrome.

Pathology	Hematology & Oncology	Iron deficiency anemia
Subject	System	Topic

Copyright © UWorld. All rights reserved.

A 54-year-old previously healthy man comes to the clinic after 2 months of progressive, generalized weakness and easy fatigability. He also has abdominal discomfort and early satiety. The patient works as a security advisor and has not traveled recently. He is afebrile and other vitals signs are normal. On examination, he has pallor, abdominal distension, and massive splenomegaly with the spleen tip crossing the midline. No peripheral lymphadenopathy is present. Peripheral blood cell count shows pancytopenia. Bone marrow aspiration is attempted, but no marrow can be aspirated. Which of the following findings is most likely to be seen in this patient?

A. Intraerythrocytic ring forms

B. Lymphocytes with cytoplasmic projections

C. Myeloid cells with azurophilic rodlike granules

D. Positive heterophile antibodies

E. Ringed sideroblasts

Submit

1
2
3
4
5
6
7
8
9
10
11
12
13
14
15
16
17
18
19
20
21
22
23
24
25
26
27
28
29
30

A 54-year-old previously healthy man comes to the clinic after 2 months of progressive, generalized weakness and easy fatigability. He also has abdominal discomfort and early satiety. The patient works as a security advisor and has not traveled recently. He is afebrile and other vitals signs are normal. On examination, he has pallor, abdominal distension, and massive splenomegaly with the spleen tip crossing the midline. No peripheral lymphadenopathy is present. Peripheral blood cell count shows pancytopenia. Bone marrow aspiration is attempted, but no marrow can be aspirated. Which of the following findings is most likely to be seen in this patient?

A. Intraerythrocytic ring forms (6%)
✓ B. Lymphocytes with cytoplasmic projections (46%)
C. Myeloid cells with azurophilic rodlike granules (25%)
D. Positive heterophile antibodies (10%)
E. Ringed sideroblasts (10%)

Omitted
Correct answer
B

46%
Answered correctly

02 secs
Time Spent

04/25/2020
Last Updated

Explanation

Lymphocytes with cytoplasmic projections are seen in **hairy cell leukemia**, an indolent B-cell neoplasm (predominantly diagnosed in **middle-aged men**) that infiltrates the bone marrow and reticuloendothelial system. Bone marrow infiltration and cytokine production cause **fibrosis** and bone marrow failure, resulting in **pancytopenia**. A bone marrow aspirate is usually unsuccessful ("**dry tap**"). Splenic red pulp infiltration can result in **massive splenomegaly** (ie, crossing midline or extending into left lower quadrant). Common manifestations include left upper quadrant pain,

Lymphocytes with cytoplasmic projections are seen in **hairy cell leukemia**, an indolent B-cell neoplasm (predominantly diagnosed in **middle-aged men**) that infiltrates the bone marrow and reticuloendothelial system. Bone marrow infiltration and cytokine production cause **fibrosis** and bone marrow failure, resulting in **pancytopenia**. A bone marrow aspirate is usually unsuccessful ("**dry tap**"). Splenic red pulp infiltration can result in **massive splenomegaly** (ie, crossing midline or extending into left lower quadrant). Common manifestations include left upper quadrant pain, fatigue, weakness, fever, and recurrent infections. The diagnosis is made by bone marrow biopsy and **flow cytometry**, which has replaced tartrate-resistant acid phosphatase (**TRAP**) activity testing.

(Choice A) Intraerythrocyte ring forms are seen in malaria. This patient has no travel history and no fevers to suggest malaria.

(Choice C) Myeloid cells with azurophilic rodlike granules (Auer rods) can be found in acute myeloid leukemias, which do not typically cause hepatosplenomegaly.

(Choice D) Heterophile antibodies are found in most patients with Epstein-Barr virus-induced infectious mononucleosis, which commonly presents in young adults with low-grade fever, pharyngitis, and cervical lymphadenopathy. Mild hepatosplenomegaly may be present.

(Choice E) Ringed sideroblasts are abnormal erythrocyte precursors found in myelodysplastic syndrome (MDS) and characterized by mitochondrial iron accumulation surrounding the nucleus. Patients with MDS typically have petechiae, weakness, and recurrent infections; splenomegaly is uncommon.

Educational objective:
Hairy cell leukemia is an indolent B-cell neoplasm predominantly found in middle-aged men and characterized by bone marrow failure and infiltration into the reticuloendothelial system, causing massive splenomegaly. Other typical features include a "dry tap" (unsuccessful bone marrow aspiration) and the presence of lymphocytes with cytoplasmic projections.

References

- How I treat hairy cell leukemia.
- Hairy cell leukemia: short review, today's recommendations and outlook.

Pathology	Hematology & Oncology	Hairy cell leukemia
Subject	System	Topic

Lymphocytes with cytoplasmic projections are seen in **hairy cell leukemia**, an indolent B-cell neoplasm (predominantly diagnosed in **middle-aged**

Exhibit Display

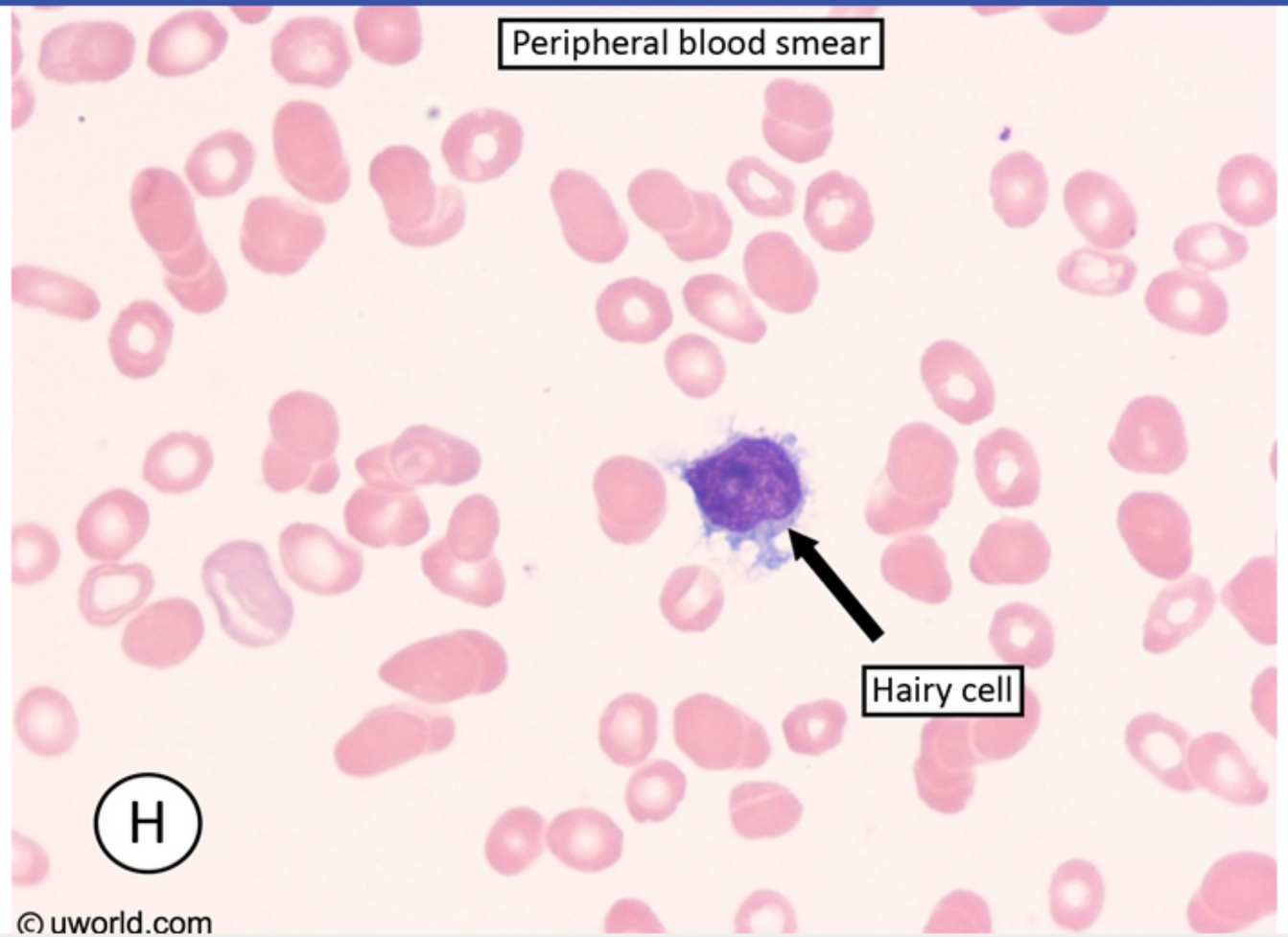

Zoom In | Zoom Out | Reset | Add To New Card | Existing Card

Lymphocytes with cytoplasmic projections are seen in **hairy cell leukemia**, an indolent B-cell neoplasm (predominantly diagnosed in **middle-aged**

Exhibit Display

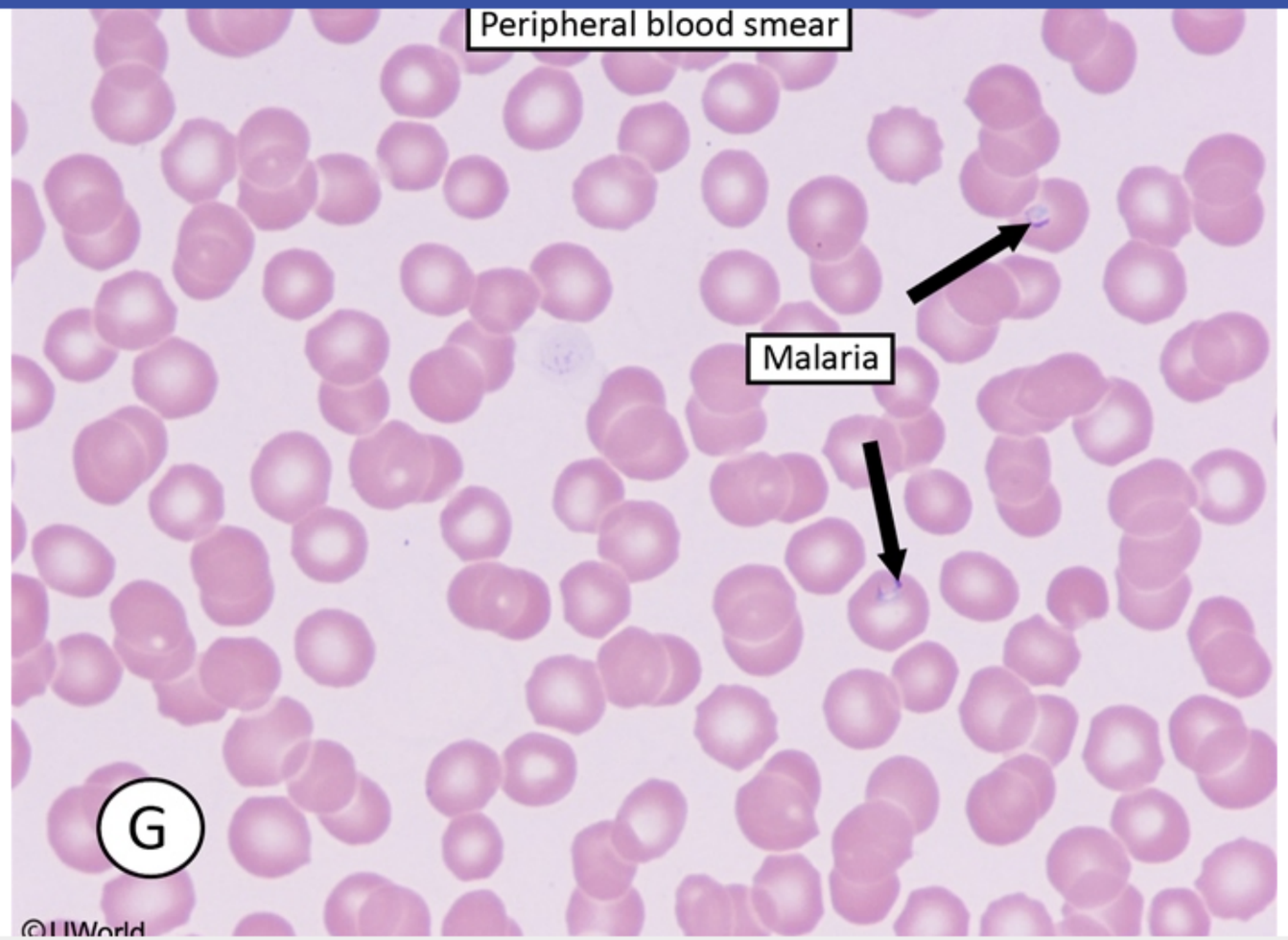

Zoom In | Zoom Out | Reset | Add To New Card | Existing Card

Lymphocytes with cytoplasmic projections are seen in **hairy cell leukemia**, an indolent B-cell neoplasm (predominantly diagnosed in **middle-aged**

Exhibit Display

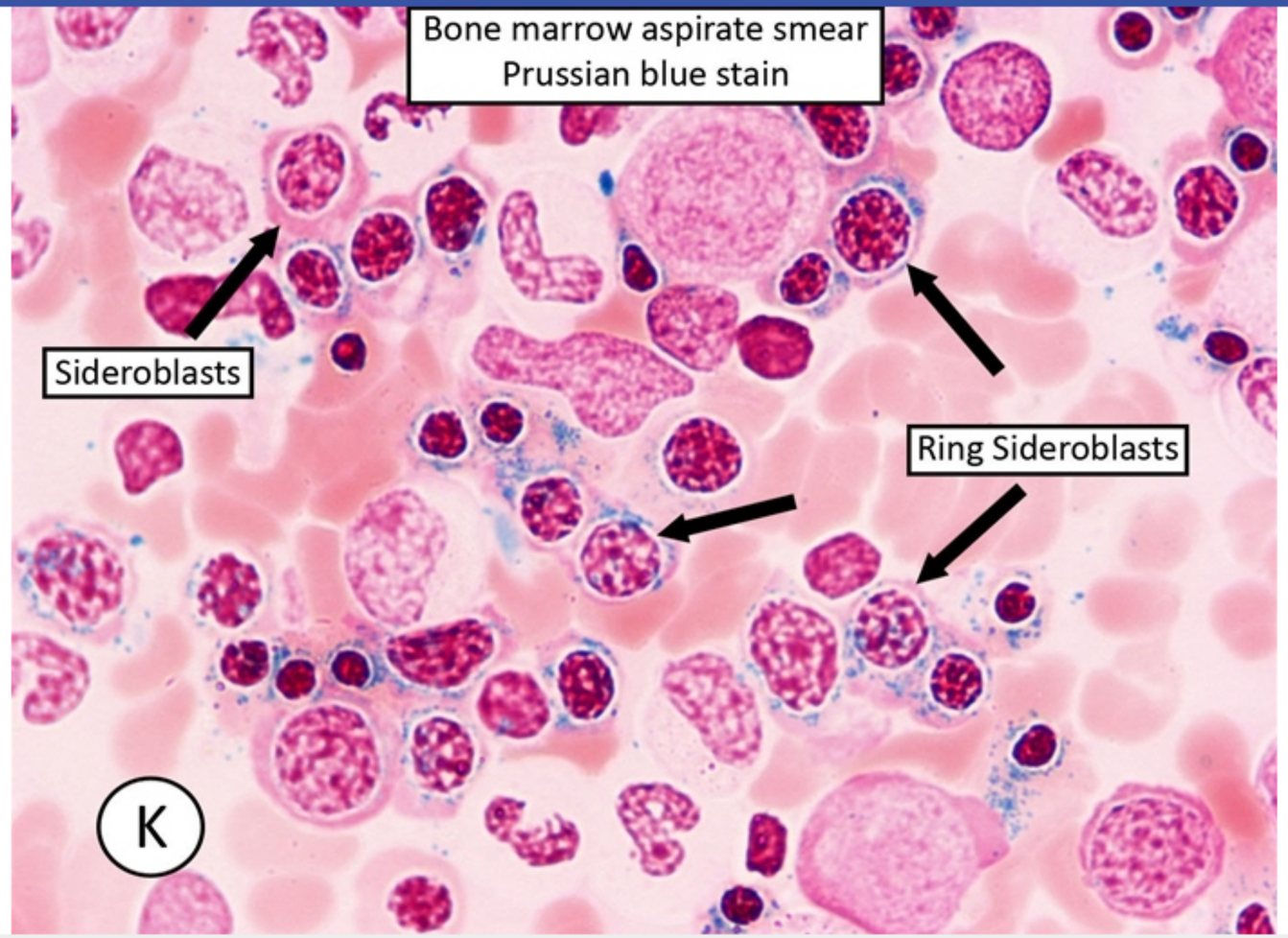

Zoom In | Zoom Out | Reset | Add To New Card | Existing Card

Platelets	198,000/mm^3
Leukocytes	6500/mm^3
Lactate dehydrogenase	Increased
Total bilirubin	3.4 mg/dL
Direct bilirubin	0.2 mg/dL
Aspartate aminotransferase (AST)	25 U/L
Alanine aminotransferase (ALT)	30 U/L
Direct Coombs test	Negative

When the patient's red blood cells are incubated in a hypotonic solution with glycerol, hemoglobin is released. The control sample does not release hemoglobin. This patient is at greatest risk of developing which of the following?

A. Autoimmune disease
B. Autoinfarction of the spleen
C. Avascular necrosis of the femur
D. Hemolysis from consumption of fava beans
E. Pigmented gallstones

Submit

A 20-year-old man is evaluated for recurrent episodes of jaundice. He was separated from his parents at a young age and is unaware of any family medical history. The patient resided in several foster homes throughout his childhood but currently lives alone. His temperature is 36.7 C (98 F), blood pressure is 120/80 mm Hg, and pulse is 72/min. Physical examination shows pallor, icterus, and mild splenomegaly. There is no lymphadenopathy or hepatomegaly. The remainder of the physical examination is normal. Laboratory test results are as follows:

Hemoglobin	9 g/L
Platelets	198,000/mm^3
Leukocytes	6500/mm^3
Lactate dehydrogenase	Increased
Total bilirubin	3.4 mg/dL
Direct bilirubin	0.2 mg/dL
Aspartate aminotransferase (AST)	25 U/L
Alanine aminotransferase (ALT)	30 U/L
Direct Coombs test	Negative

When the patient's red blood cells are incubated in a hypotonic solution with glycerol, hemoglobin is released. The control sample does not release hemoglobin. This patient is at greatest risk of developing which of the following?

A. Autoimmune disease
B. Autoinfarction of the spleen
C. Avascular necrosis of the femur
D. Hemolysis from consumption of fava beans

Platelets	198,000/mm^3
Leukocytes	6500/mm^3
Lactate dehydrogenase	Increased
Total bilirubin	3.4 mg/dL
Direct bilirubin	0.2 mg/dL
Aspartate aminotransferase (AST)	25 U/L
Alanine aminotransferase (ALT)	30 U/L
Direct Coombs test	Negative

When the patient's red blood cells are incubated in a hypotonic solution with glycerol, hemoglobin is released. The control sample does not release hemoglobin. This patient is at greatest risk of developing which of the following?

A. Autoimmune disease
B. Autoinfarction of the spleen
C. Avascular necrosis of the femur
D. Hemolysis from consumption of fava beans
E. Pigmented gallstones

Submit

Platelets	198,000/mm^3
Leukocytes	6500/mm^3
Lactate dehydrogenase	Increased
Total bilirubin	3.4 mg/dL
Direct bilirubin	0.2 mg/dL
Aspartate aminotransferase (AST)	25 U/L
Alanine aminotransferase (ALT)	30 U/L
Direct Coombs test	Negative

When the patient's red blood cells are incubated in a hypotonic solution with glycerol, hemoglobin is released. The control sample does not release hemoglobin. This patient is at greatest risk of developing which of the following?

A. Autoimmune disease (3%)
B. Autoinfarction of the spleen (18%)
C. Avascular necrosis of the femur (2%)
D. Hemolysis from consumption of fava beans (20%)
✓ E. Pigmented gallstones (56%)

Omitted
Correct answer

56%
Answered correctly

05 secs
Time Spent

02/18/2020
Last Updated

Hereditary spherocytosis	
Epidemiology	• Autosomal dominant inheritance (~75%) • Northern European descent
Clinical presentation	• Hemolytic anemia • Jaundice • Splenomegaly
Laboratory findings	• ↑ **Mean corpuscular hemoglobin concentration** • **Spherocytes** on peripheral smear • Negative Coombs test • ↑ Osmotic fragility on **acidified glycerol lysis test**
Treatment	• Splenectomy
Complications	• Pigmented gallstones • Aplastic crises from parvovirus B19 infection

©UWorld

This patient's presentation with anemia, elevated lactate dehydrogenase, and indirect hyperbilirubinemia suggests hemolytic anemia. The lysing of blood cells when incubated in hypotonic saline with glycerol describes a positive acidified glycerol lysis test, the diagnostic test for **hereditary spherocytosis (HS)**. Spherocytes demonstrate **increased osmotic fragility** in this test due to their decreased surface area to volume ratio.

HS is the most common hemolytic anemia due to a **red blood cell (RBC) membrane defect**. The mutation in HS most often affects **spectrin** and **ankyrin**, the plasma-membrane scaffolding proteins. Patients with HS present with **hemolytic anemia, jaundice**, and **splenomegaly**. **Pigmented gallstones** are a complication of any hemolytic anemia. In chronic hemolysis, the increased bilirubin from lysed RBCs precipitates as calcium bilirubinate, forming pigmented stones in the gallbladder. Patients with HS may also present with aplastic crises due to parvovirus B19

Explanation

Hereditary spherocytosis	
Epidemiology	• Autosomal dominant inheritance (~75%) • Northern European descent
Clinical presentation	• Hemolytic anemia • Jaundice • Splenomegaly
Laboratory findings	• ↑ **Mean corpuscular hemoglobin concentration** • **Spherocytes** on peripheral smear • Negative Coombs test • ↑ Osmotic fragility on **acidified glycerol lysis test**
Treatment	• Splenectomy
Complications	• Pigmented gallstones • Aplastic crises from parvovirus B19 infection

©UWorld

This patient's presentation with anemia, elevated lactate dehydrogenase, and indirect hyperbilirubinemia suggests hemolytic anemia. The lysing of blood cells when incubated in hypotonic saline with glycerol describes a positive acidified glycerol lysis test, the diagnostic test for **hereditary spherocytosis (HS)**. Spherocytes demonstrate **increased osmotic fragility** in this test due to their decreased surface area to volume ratio.

HS is the most common hemolytic anemia due to a **red blood cell (RBC) membrane defect**. The mutation in HS most often affects **spectrin** and **ankyrin**, the plasma-membrane scaffolding proteins. Patients with HS present with **hemolytic anemia, jaundice**, and **splenomegaly**.

©UWorld

This patient's presentation with anemia, elevated lactate dehydrogenase, and indirect hyperbilirubinemia suggests hemolytic anemia. The lysing of blood cells when incubated in hypotonic saline with glycerol describes a positive acidified glycerol lysis test, the diagnostic test for **hereditary spherocytosis (HS)**. Spherocytes demonstrate **increased osmotic fragility** in this test due to their decreased surface area to volume ratio.

HS is the most common hemolytic anemia due to a **red blood cell (RBC) membrane defect**. The mutation in HS most often affects **spectrin** and **ankyrin**, the plasma-membrane scaffolding proteins. Patients with HS present with **hemolytic anemia, jaundice**, and **splenomegaly**. **Pigmented gallstones** are a complication of any hemolytic anemia. In chronic hemolysis, the increased bilirubin from lysed RBCs precipitates as calcium bilirubinate, forming pigmented stones in the gallbladder. Patients with HS may also present with aplastic crises due to parvovirus B19 infection.

(Choice A) Autoimmune hemolytic anemia (AIHA) results in findings similar to those seen in HS (eg, indirect hyperbilirubinemia, elevated lactate dehydrogenase, spherocytes on peripheral blood smear). In contrast to HS, AIHA is not heritable, and patients have a positive direct antiglobulin (Coombs) test along with a propensity to develop autoimmune disease (eg, systemic lupus erythematosus).

(Choices B and C) The abnormal adhesion of sickle cell RBCs to the endothelium and the subsequent obstruction of small blood vessels lead to various injuries, which include splenic autoinfarction and femoral avascular necrosis. A positive acidified glycerol lysis test classically describes HS, not sickle cell anemia.

(Choice D) Glucose-6-phosphate dehydrogenase (G6PD) deficiency presents with hemolytic anemia and indirect hyperbilirubinemia usually following oxidative stress. Common triggers include drugs (sulfonamide or antimalarial agents), fava beans, and infections (viral hepatitis, pneumonia, or typhoid). Peripheral smears of G6PD deficiency anemia show bite cells and Heinz bodies, not spherocytes.

Educational objective:
Hereditary spherocytosis results from red cell cytoskeleton abnormalities, most commonly in the proteins spectrin and ankyrin. Increased osmotic fragility on acidified glycerol lysis testing confirms the diagnosis. Hemolytic anemia, jaundice, and splenomegaly are classic manifestations. Complications include pigmented gallstones and aplastic crises from parvovirus B19 infection.

References

- Hereditary spherocytosis.

©UWorld

Exhibit Display

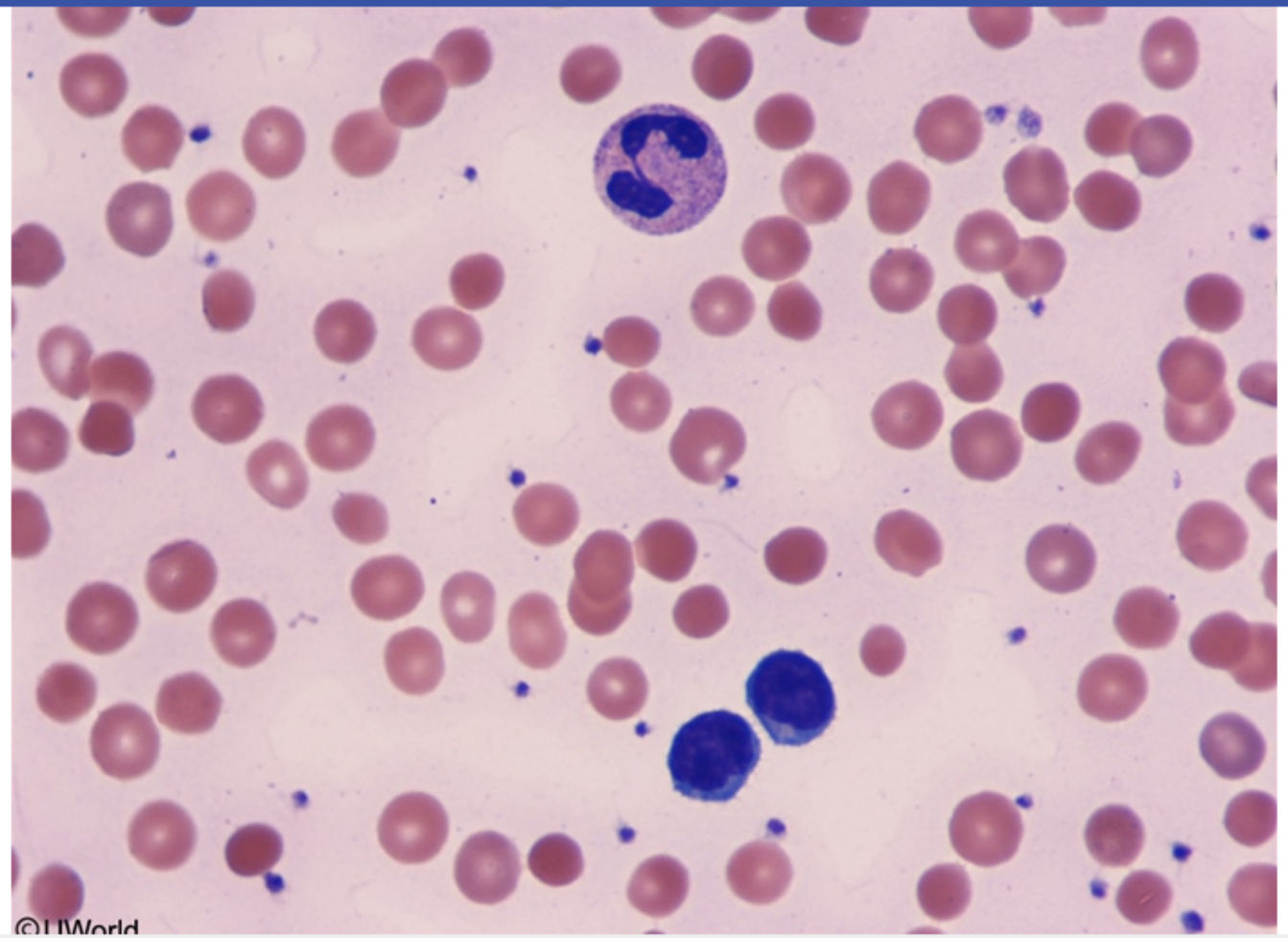

Zoom In | Zoom Out | Reset | Add To New Card | Existing Card

calcium bilirubinate, forming pigmented stones in the gallbladder. Patients with HS may also present with aplastic crises due to parvovirus B19

Exhibit Display

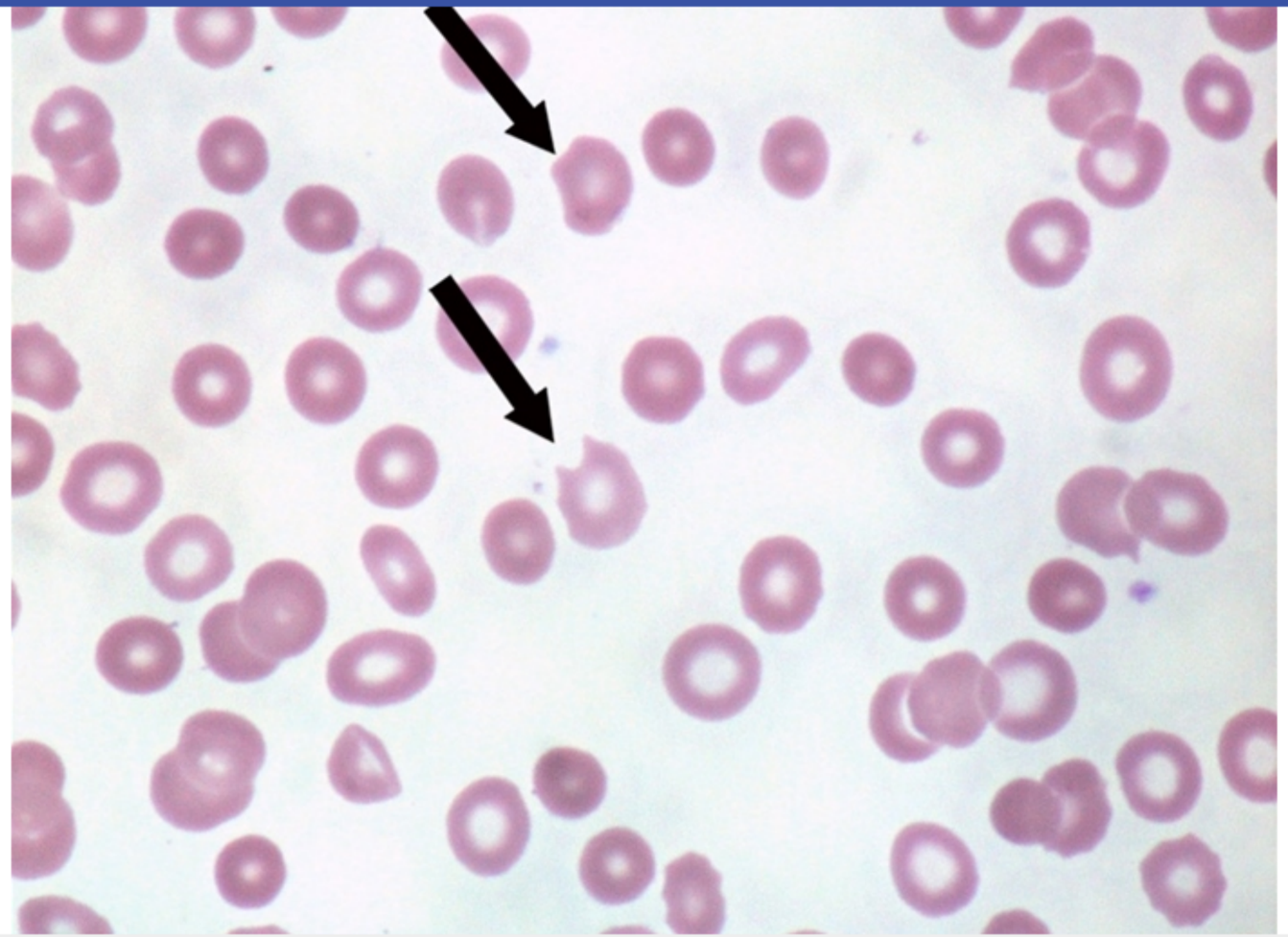

Zoom In | Zoom Out | Reset | Add To New Card | Existing Card

8
9
10
11
12
13
14
15
16
17
18
19
20
21
22
23
24
25
26
27
28
29
30
31
32
33
34
35
36
37

A 32-year-old woman comes to the office for evaluation of a breast lump. She noticed the lump a few months ago but thinks it might be getting larger. The patient has a history of right lower limb amputation at age 17 due to osteosarcoma. The patient's mother died of an adrenal tumor, and her younger sister died of leukemia. Examination of the left breast shows a 5-cm, firm immobile mass with irregular borders. Which of the following gene mutations is the most likely etiology for this patient's condition?

A. *APC*

B. *BRCA1*

C. *NF2*

D. *TP53*

E. *RB1*

Submit

A 32-year-old woman comes to the office for evaluation of a breast lump. She noticed the lump a few months ago but thinks it might be getting larger. The patient has a history of right lower limb amputation at age 17 due to osteosarcoma. The patient's mother died of an adrenal tumor, and her younger sister died of leukemia. Examination of the left breast shows a 5-cm, firm immobile mass with irregular borders. Which of the following gene mutations is the most likely etiology for this patient's condition?

A. *APC* (2%)

B. *BRCA1* (20%)

C. *NF2* (1%)

✓ D. *TP53* (58%)

E. *RB1* (16%)

Omitted
Correct answer
D

58%
Answered correctly

02 secs
Time Spent

07/08/2020
Last Updated

Explanation

Common hereditary cancer syndromes			
Syndrome	**Gene**	**Associated neoplasms**	**Pathogenesis**
	MSH2, MLH1	• Colorectal cancer	

Common hereditary cancer syndromes

Syndrome	Gene	Associated neoplasms	Pathogenesis
Lynch syndrome	*MSH2, MLH1, MSH6, PMS2*	• Colorectal cancer • Endometrial cancer • Ovarian cancer	• **Autosomal dominant** • Caused by **inactivating** mutation in corresponding **tumor suppressor gene** • Deletion of remaining normal allele (**second hit**) leads to loss of heterozygosity & **malignant transformation**
Familial adenomatous polyposis	*APC*	• Colorectal cancer • Desmoids & osteomas • Brain tumors	
von Hippel-Lindau syndrome	*VHL*	• Hemangioblastomas • Clear cell renal carcinoma • Pheochromocytoma	
Li-Fraumeni syndrome	*TP53*	• Sarcomas • Breast cancer • Brain tumors • Adrenocortical carcinoma • Leukemia	
Multiple endocrine neoplasia type 1	*MEN1*	• Parathyroid adenomas • Pituitary adenomas	

8
9
10
11
12
13
14
15
16
17
18
19
20
21
22
23
24
25
26
27
28
29
30
31
32
33
34
35
36
37

Li-Fraumeni syndrome	*TP53*	• Sarcomas • Breast cancer • Brain tumors • Adrenocortical carcinoma • Leukemia	**suppressor gene** • Deletion of remaining normal allele (**second hit**) leads to loss of heterozygosity & **malignant transformation**
Multiple endocrine neoplasia type 1	*MEN1*	• Parathyroid adenomas • Pituitary adenomas • Pancreatic adenomas	
Multiple endocrine neoplasia type 2	*RET*	• Medullary thyroid cancer • Pheochromocytoma • Parathyroid hyperplasia (*MEN2A*)	• **Autosomal dominant** • **Activating** (gain-of-function) mutation in proto-oncogene • **Continuous stimulation** of cell division predisposes to tumor growth

A history of **sarcoma, leukemia, adrenal,** and **breast cancer** is suggestive of **Li-Fraumeni syndrome**. Cancers of the **brain** are also common. The syndrome is the result of an **autosomal dominant** mutation in *TP53*, a gene that codes for the tumor suppressor protein **p53**. Patients with this disorder are genetically predisposed to cancer development at a **young** age. Patients with Li-Fraumeni syndrome inherit one mutated allele of *TP53*, but somatic mutation of the second allele is needed for tumor development (2-hit hypothesis).

p53 plays an essential role in maintaining the integrity of the human genome by causing cells with mutant DNA to arrest in the G1/S stage of the cell cycle until the damage is repaired. Normally, cells with irreversible DNA damage are not allowed to divide and proceed to apoptosis. Without a functioning p53 protein, the defective cells divide unchecked and become cancerous.

A history of **sarcoma, leukemia, adrenal,** and **breast cancer** is suggestive of **Li-Fraumeni syndrome**. Cancers of the **brain** are also common. The syndrome is the result of an **autosomal dominant** mutation in *TP53*, a gene that codes for the tumor suppressor protein **p53**. Patients with this disorder are genetically predisposed to cancer development at a **young** age. Patients with Li-Fraumeni syndrome inherit one mutated allele of *TP53*, but somatic mutation of the second allele is needed for tumor development (2-hit hypothesis).

p53 plays an essential role in maintaining the integrity of the human genome by causing cells with mutant DNA to arrest in the G1/S stage of the cell cycle until the damage is repaired. Normally, cells with irreversible DNA damage are not allowed to divide and proceed to apoptosis. Without a functioning p53 protein, the defective cells divide unchecked and become cancerous.

(Choice A) The adenomatous polyposis coli (*APC*) gene mutation is found in patients with familial polyposis syndromes, sporadic colon cancer, and melanomas. *APC* is responsible for maintaining low levels of β-catenin (oncogenic protein) and for intercellular adhesion.

(Choice B) Mutation of the *BRCA1* tumor suppressor gene increases the risk for breast and ovarian cancers, and it is the most common hereditary breast cancer. This mutation is not associated with sarcomas, leukemia, or brain tumors.

(Choice C) *NF2* is a tumor suppressor gene. Mutation of *NF2* increases the risk for developing neurofibromatosis type 2. Patients present with bilateral acoustic neuromas (schwannomas of the cerebellopontine angle). Symptoms include bilateral hearing loss, vertigo, and tinnitus.

(Choice E) *RB1* is a tumor suppressor gene that codes for the Rb protein, which regulates the G1-S checkpoint of the cell cycle. Mutation of *RB1* predisposes to the development of retinoblastomas and osteosarcomas, but not breast cancer or leukemia. The 2-hit hypothesis has been proposed to account for hereditary retinoblastoma.

Educational objective:
Li-Fraumeni syndrome is caused by an autosomal dominant mutation in the tumor suppressor gene *TP53*. Leukemia, sarcomas, and tumors of the breast, brain, and adrenal cortex are most common.

References

- Revisiting Li-Fraumeni Syndrome From TP53 Mutation Carriers.

Pathology	Hematology & Oncology	Li-fraumeni syndrome
Subject	System	Topic

A history of **sarcoma, leukemia, adrenal,** and **breast cancer** is suggestive of **Li-Fraumeni syndrome**. Cancers of the **brain** are also common.

Exhibit Display

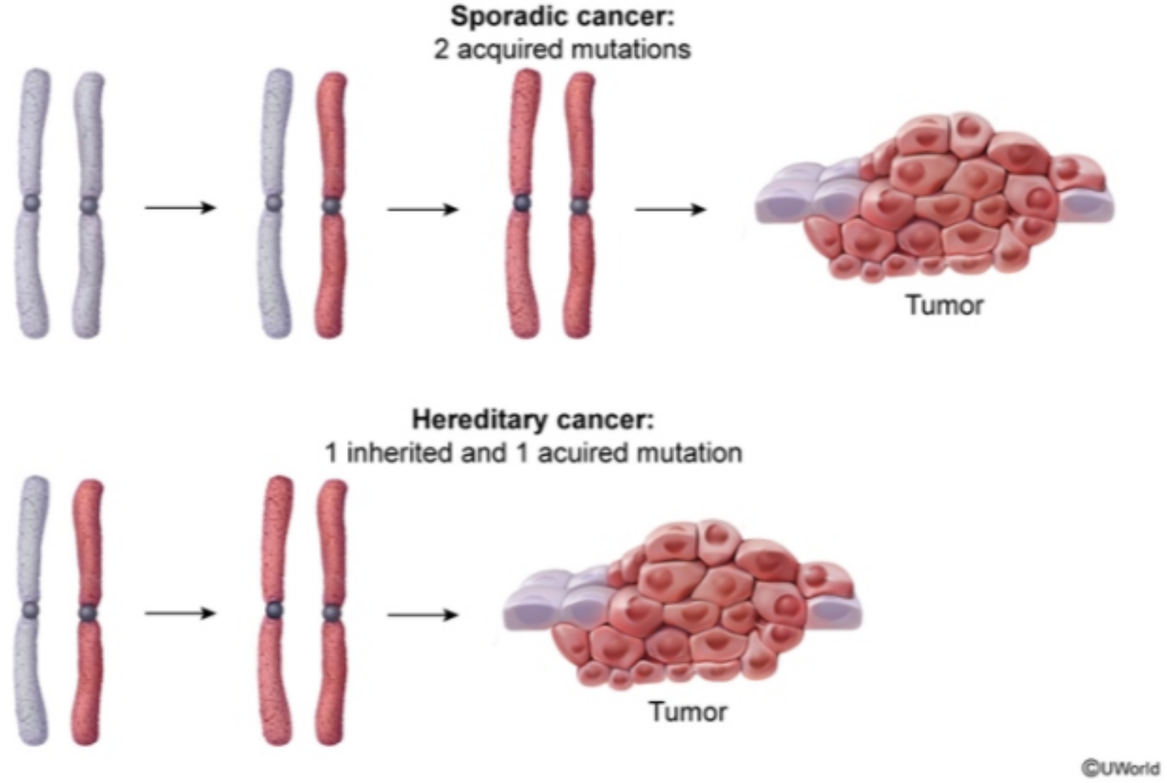

Zoom In | Zoom Out | Reset | Add To New Card | Existing Card

Subject System Topic

A history of **sarcoma, leukemia, adrenal,** and **breast cancer** is suggestive of **Li-Fraumeni syndrome**. Cancers of the **brain** are also common.

Exhibit Display

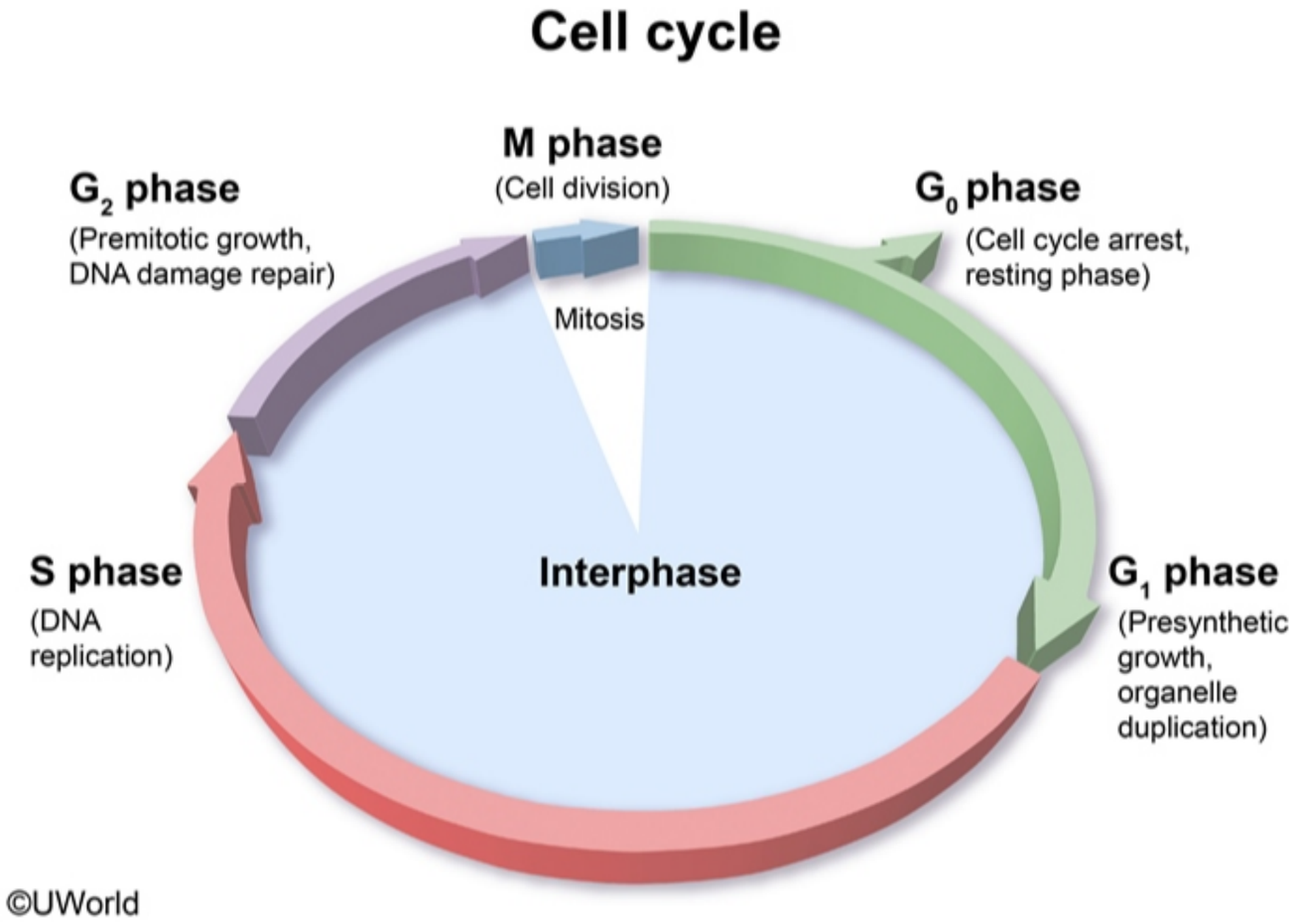

Zoom In | Zoom Out | Reset | Add To New Card | Existing Card

Subject System Topic

A history of **sarcoma, leukemia, adrenal,** and **breast cancer** is suggestive of **Li-Fraumeni syndrome**. Cancers of the **brain** are also common.

Exhibit Display

Retinoblastoma white reflex

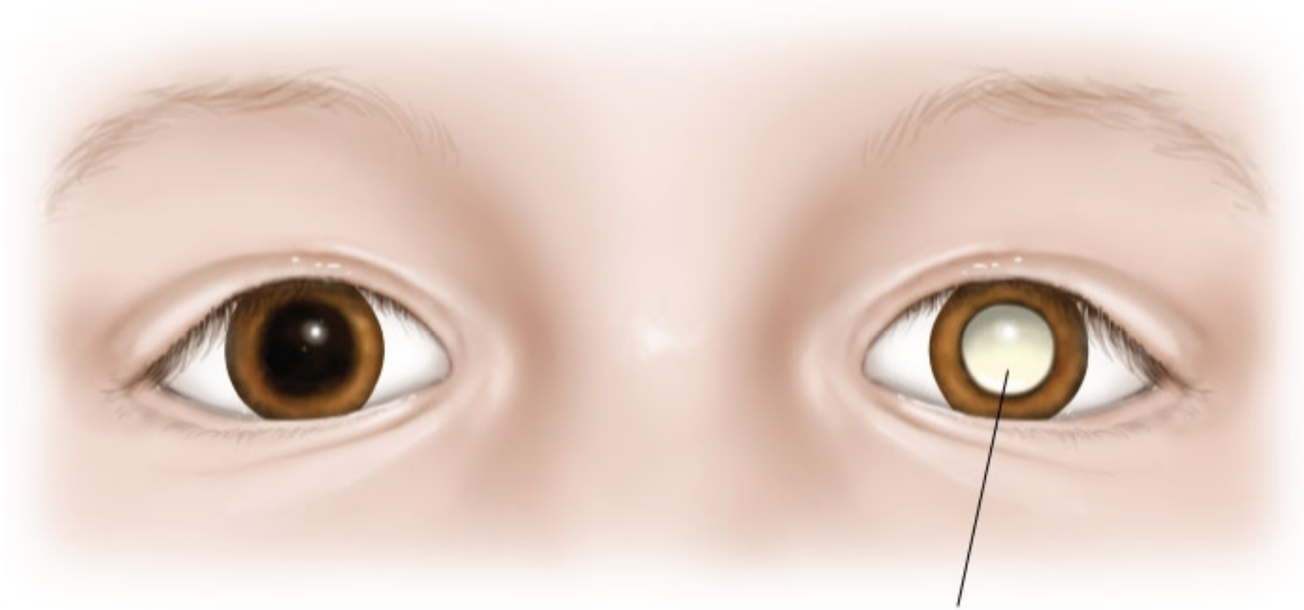

Retinoblastoma of the left eye with white reflex

©USMLEWorld, LLC

Zoom In | Zoom Out | Reset | Add To New Card | Existing Card

Subject System Topic

8
9
10
11
12
13
14
15
16
17
18
19
20
21
22
23
24
25
26
27
28
29
30
31
32
33
34
35
36
37

8
9
10
11
12
13
14
15
16
17
18
19
20
21
22
23
24
25
26
27
28
29
30
31
32
33
34
35
36
37

A 56-year-old man comes to the office due to several months of progressive neck swelling. He has also had intermittent epistaxis and headaches. The patient has no chronic medical conditions and takes no medications. He does not use tobacco, alcohol, or illicit drugs, and he emigrated to the United States from rural China 12 years ago. Physical examination shows several enlarged, firm, and nontender cervical lymph nodes. Nasopharyngeal evaluation reveals a mass arising from the pharyngeal recess. Histopathological examination of the mass shows undifferentiated malignant cells of epithelial origin. Further analysis of these cells is most likely to reveal the presence of nucleic acid sequences from which of the following viruses?

A. Adenovirus
B. Coronavirus
C. Cytomegalovirus
D. Epstein-Barr virus
E. Human herpes virus 8
F. Polyomavirus

Submit

8
9
10
11
12
13
14
15
16
17
18
19
20
21
22
23
24
25
26
27
28
29
30
31
32
33
34
35
36
37

A 56-year-old man comes to the office due to several months of progressive neck swelling. He has also had intermittent epistaxis and headaches. The patient has no chronic medical conditions and takes no medications. He does not use tobacco, alcohol, or illicit drugs, and he emigrated to the United States from rural China 12 years ago. Physical examination shows several enlarged, firm, and nontender cervical lymph nodes. Nasopharyngeal evaluation reveals a mass arising from the pharyngeal recess. Histopathological examination of the mass shows undifferentiated malignant cells of epithelial origin. Further analysis of these cells is most likely to reveal the presence of nucleic acid sequences from which of the following viruses?

A. Adenovirus (1%)
B. Coronavirus (0%)
C. Cytomegalovirus (2%)
✓ D. Epstein-Barr virus (90%)
E. Human herpes virus 8 (3%)
F. Polyomavirus (1%)

Omitted
Correct answer
D

90%
Answered correctly

02 secs
Time Spent

06/01/2020
Last Updated

Explanation

Nasopharyngeal carcinoma is an epithelial tumor that usually originates in the pharyngeal recess. Local tumor growth often leads to epistaxis and headaches, and metastatic spread to cervical lymph nodes frequently causes firm, fixed neck swelling. NPC is relatively uncommon in the

Nasopharyngeal carcinoma is an epithelial tumor that usually originates in the pharyngeal recess. Local tumor growth often leads to epistaxis and headaches, and metastatic spread to cervical lymph nodes frequently causes firm, fixed neck swelling. NPC is relatively uncommon in the United States but is endemic to **southern China**, where genetic and dietary factors (eg, consumption of salted fish) predispose to premalignant nasopharyngeal epithelial lesions. Subsequent **malignant transformation** is then induced by **Epstein-Barr virus** (EBV).

EBV is a ubiquitous human herpes virus that causes infectious mononucleosis in a minority of patients (primary infection is usually asymptomatic). Initial infection is followed by life-long **latent infection** in memory B cells. While latent, the EBV genome exists as an episome in the nucleus of infected cells and expresses a restricted subset of EBV genes (**latency genes**) which do the following:

- Promote periodic viral reactivation from memory B-cells, leading to recurrent (asymptomatic) mucosal infections.
- Promote survival of infected memory B cells by encoding for proteins (eg, EBNA-1, LMP1) that prevent apoptosis. In a minority of patients, these proteins are oncogenic and lead to **malignant transformation** of infected B cells (eg, Burkitt lymphoma, Hodgkin lymphoma) or premalignant epithelial cells (eg, nasopharyngeal carcinoma, salivary cancer).

Individuals who do not have premalignant epithelial lesions are at very low risk of EBV-associated epithelial cancers like NPC.

(Choice A) Adenovirus causes acute upper respiratory infection with pharyngitis, coryza, otitis media, bronchitis, and/or pneumonia. It is not associated with nasopharyngeal carcinoma.

(Choice B) Coronavirus is one of the most common causes of upper respiratory tract infection (eg, common cold) but has no association with nasopharyngeal or other cancers.

(Choices C and E) Cytomegalovirus (CMV) and human herpes virus 8 (HHV-8) are also herpes viruses; as such, they cause acute infection followed by latent disease. Although CMV can reactivate in immunocompromised individuals (eg, HIV, post-transplantation) and cause severe end-organ disease (eg, retinitis, gastroenteritis), it is not an oncogenic virus. HHV-8 reactivation also primarily occurs in immunocompromised individuals and is associated with Kaposi sarcoma.

(Choice F) The BK and JC viruses are members of Polyomaviridae and cause life-long latent infections in the kidney. BK reactivation can cause nephropathy in renal transplant recipients, and JC virus causes progressive multifocal leukoencephalopathy (primarily in patients with advanced HIV).

8 9 10 11 12 13 14 15 16 17 18 19 20 21 22 23 24 25 26 27 28 29 30 31 32 33 34 35 36 37

premalignant epithelial cells (eg, nasopharyngeal carcinoma, salivary cancer).

Individuals who do not have premalignant epithelial lesions are at very low risk of EBV-associated epithelial cancers like NPC.

(Choice A) Adenovirus causes acute upper respiratory infection with pharyngitis, coryza, otitis media, bronchitis, and/or pneumonia. It is not associated with nasopharyngeal carcinoma.

(Choice B) Coronavirus is one of the most common causes of upper respiratory tract infection (eg, common cold) but has no association with nasopharyngeal or other cancers.

(Choices C and E) Cytomegalovirus (CMV) and human herpes virus 8 (HHV-8) are also herpes viruses; as such, they cause acute infection followed by latent disease. Although CMV can reactivate in immunocompromised individuals (eg, HIV, post-transplantation) and cause severe end-organ disease (eg, retinitis, gastroenteritis), it is not an oncogenic virus. HHV-8 reactivation also primarily occurs in immunocompromised individuals and is associated with Kaposi sarcoma.

(Choice F) The BK and JC viruses are members of Polyomaviridae and cause life-long latent infections in the kidney. BK reactivation can cause nephropathy in renal transplant recipients, and JC virus causes progressive multifocal leukoencephalopathy (primarily in patients with advanced HIV).

Educational objective:
Nasopharyngeal cancer is endemic in southern China due to genetic and dietary factors that promote nasopharyngeal epithelial pre-malignant lesions. In almost all cases, malignant transformation occurs due to infection of premalignant cells with Epstein-Barr virus and the subsequent expression of oncogenic viral proteins.

References

- Epstein-Barr virus and nasopharyngeal carcinoma.

Pathology	Hematology & Oncology	Nasopharyngeal carcinoma
Subject	System	Topic

Copyright © UWorld. All rights reserved.

8
9
10
11
12
13
14
15
16
17
18
19
20
21
22
23
24
25
26
27
28
29
30
31
32
33
34
35
36
37

A 26-year-old woman, gravida 2 para 1, at 8 weeks gestation comes to the office due to pain and swelling of her left leg for the past day. The patient had a pulmonary embolism during her previous pregnancy, and prophylactic low-molecular-weight heparin therapy was initiated 6 days ago. She has no other medical conditions and takes prenatal vitamins. Physical examination shows left lower extremity edema and calf tenderness but no other abnormalities. Venous duplex ultrasonography reveals acute left femoral vein thrombosis. Platelet count, which was normal prior to anticoagulant therapy initiation, is 84,000/mm^3. Other blood cell counts and renal and liver function studies are within normal limits. Which of the following most likely predisposed this patient to her current condition?

A. Acquired protein C deficiency

B. Anti-platelet factor 4/heparin antibodies

C. Anti-platelet glycoprotein IIb/IIIa antibodies

D. Cold-precipitable immunoglobulins

E. Decreased ADAMTS13 level

Submit

A 26-year-old woman, gravida 2 para 1, at 8 weeks gestation comes to the office due to pain and swelling of her left leg for the past day. The patient had a pulmonary embolism during her previous pregnancy, and prophylactic low-molecular-weight heparin therapy was initiated 6 days ago. She has no other medical conditions and takes prenatal vitamins. Physical examination shows left lower extremity edema and calf tenderness but no other abnormalities. Venous duplex ultrasonography reveals acute left femoral vein thrombosis. Platelet count, which was normal prior to anticoagulant therapy initiation, is 84,000/mm^3. Other blood cell counts and renal and liver function studies are within normal limits. Which of the following most likely predisposed this patient to her current condition?

- A. Acquired protein C deficiency (12%)
- ✓ B. Anti-platelet factor 4/heparin antibodies (71%)
- C. Anti-platelet glycoprotein IIb/IIIa antibodies (4%)
- D. Cold-precipitable immunoglobulins (1%)
- E. Decreased ADAMTS13 level (9%)

Omitted
Correct answer
B

71%
Answered correctly

02 secs
Time Spent

03/04/2020
Last Updated

Explanation

Heparin-induced thrombocytopenia & thrombosis

8
9
10
11
12
13
14
15
16
17
18
19
20
21
22
23
24
25
26
27
28
29
30
31
32
33
34
35
36
37

Heparin-induced thrombocytopenia & thrombosis

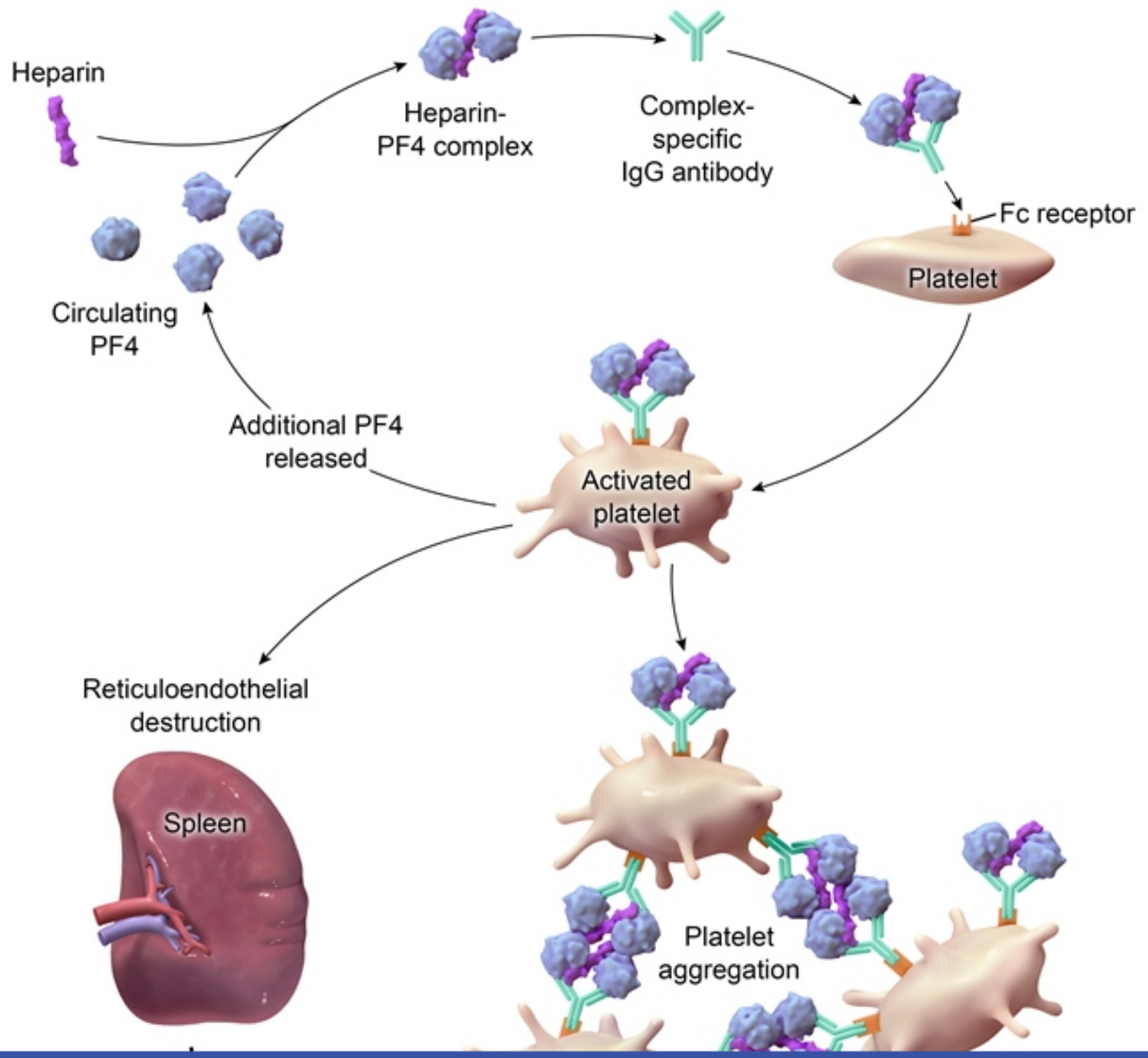

8
9
10
11
12
13
14
15
16
17
18
19
20
21
22
23
24
25
26
27
28
29
30
31
32
33
34
35
36
37

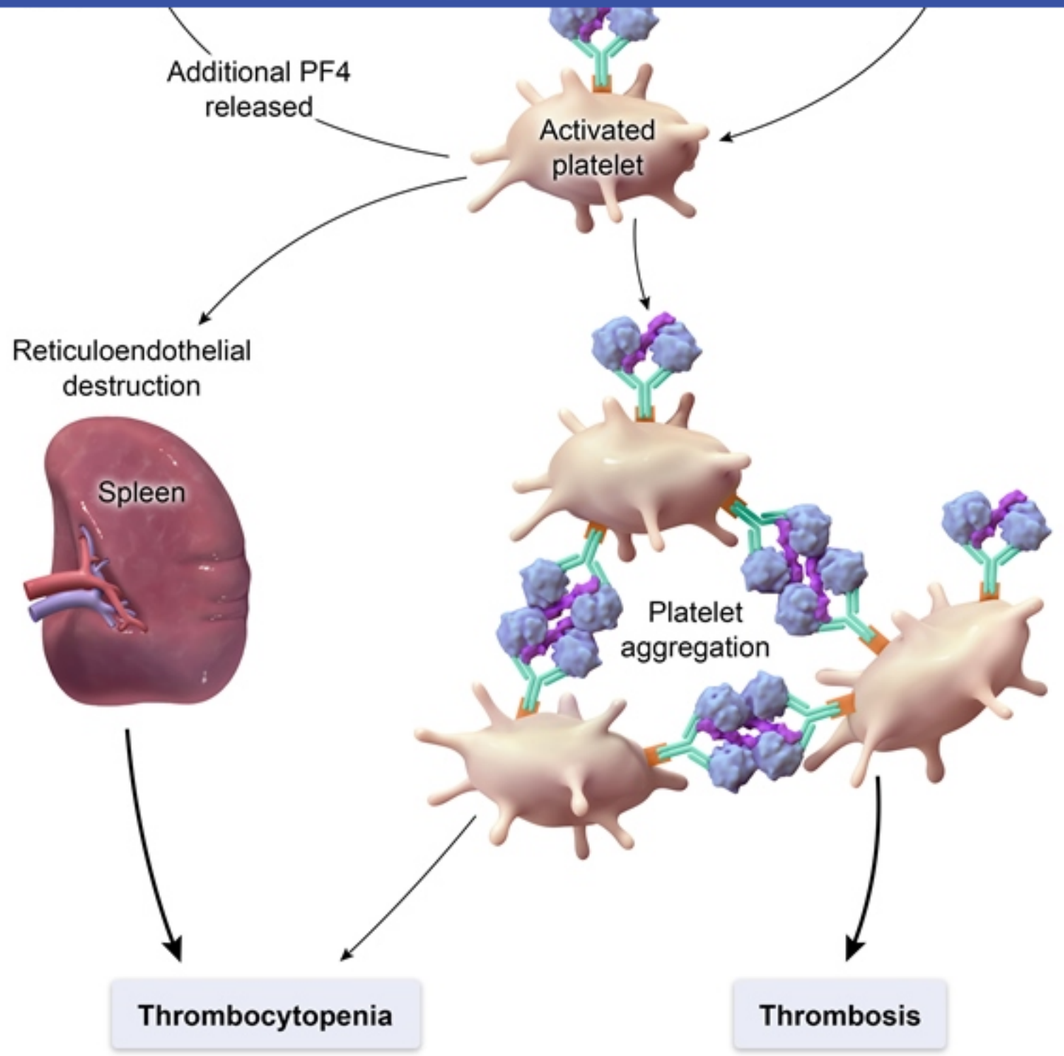

PF4 = platelet factor 4.

©UWorld

This patient with a significant drop in platelet count and acute venous thromboembolism following recent exposure to low molecular weight heparin

8 9 10 11 12 13 14 15 16 17 18 19 20 21 22 23 24 25 26 27 28 29 30 31 32 33 34 35 36 37

This patient with a significant drop in platelet count and acute venous thromboembolism following recent exposure to low molecular weight heparin likely has **heparin-induced thrombocytopenia and thrombosis** (HITT), also known as heparin-induced thrombocytopenia type 2. HITT typically occurs 5-10 days following exposure to heparin products and is characterized by a large drop in platelet count. It is more common following exposure to unfractionated heparin but can occur following exposure to low-molecular weight heparin as well.

Platelet factor 4 (PF4) is a protein released from the alpha granules of platelets that plays a role in platelet aggregation. It also binds heparin and helps inactivate the molecule. The mechanism of HITT involves the generation of **IgG antibodies** to these complexes of heparin and PF4. The Fc component of the activated IgG antibodies then binds to additional platelets, resulting in further PF4 release and **widespread platelet activation**. This leads to a **prothrombotic state** that places patients at high risk for both arterial and venous thrombosis.

(Choice A) Acquired protein C deficiency occurs early in the course of warfarin therapy, as the inhibition of protein C by warfarin occurs more rapidly than the inhibition of other factors (ie, factors II, VII, IX, X). If not bridged with heparin when starting therapy, patients may develop warfarin-induced skin necrosis due to localized cutaneous thrombus formation.

(Choice C) Idiopathic thrombocytopenic purpura (ITP) results from splenic destruction of platelets labeled by IgG antibodies to glycoprotein IIb/IIIa receptors. ITP often causes very low platelet levels and is associated with bleeding complications rather than thrombosis.

(Choice D) Cryoglobulinemia can occur in the setting of autoimmune disease (eg, systemic lupus erythematosus) or viral infection (eg, hepatitis C) and causes systemic vasculitis characterized by fatigue, arthralgia, and purpuric rash. Marked thrombocytopenia is not typical.

(Choice E) Thrombotic thrombocytopenic purpura (TTP) results from decreased levels of the von Willebrand factor-cleaving protease ADAMTS13. The classic presentation of TTP is the pentad of fever, thrombocytopenia, microangiopathic hemolytic anemia, renal insufficiency, and neurologic dysfunction.

Educational objective:
Heparin-induced thrombocytopenia and thrombosis results from the production of IgG antibodies against complexes of heparin and platelet factor 4. The Fc component of these antibodies binds to platelets, resulting in widespread platelet activation and a prothrombotic state.

References

- Heparin-induced thrombocytopenia.

8
9
10
11
12
13
14
15
16
17
18
19
20
21
22
23
24
25
26
27
28
29
30
31
32
33
34
35
36
37

A 57-year-old male presents to your office complaining of fatigue and low energy. He also notes experiencing intermittent back pain that responds to ibuprofen. He has no significant past medical history. His family history is significant for his father dying of a heart attack at age 60. Fecal occult blood testing is negative. Laboratory studies reveal:

Hematocrit	36%
MCV	86 fl
WBC	7,000/mm^3
Platelets	170,000/mm^3
Sodium	136 mEq/L
Potassium	4.5 mEq/L
AST	34 U/L
ALT	18 U/L
Bilirubin	0.8 mg/dL
Creatinine	2.0 mg/dL

Plasma protein electrophoresis reveals a high peak corresponding to gamma-globulins. The most likely diagnosis is:

A. Iron deficiency
B. Cobalamin deficiency
C. Chronic lymphocytic leukemia
D. Aplastic anemia

Platelets	170,000/mm^3
Sodium	136 mEq/L
Potassium	4.5 mEq/L
AST	34 U/L
ALT	18 U/L
Bilirubin	0.8 mg/dL
Creatinine	2.0 mg/dL

Plasma protein electrophoresis reveals a high peak corresponding to gamma-globulins. The most likely diagnosis is:

- A. Iron deficiency
- B. Cobalamin deficiency
- C. Chronic lymphocytic leukemia
- D. Aplastic anemia
- E. Plasma cell neoplasm
- F. Hodgkin lymphoma
- G. Hypothyroidism

Submit

Platelets	170,000/mm^3
Sodium	136 mEq/L
Potassium	4.5 mEq/L
AST	34 U/L
ALT	18 U/L
Bilirubin	0.8 mg/dL
Creatinine	2.0 mg/dL

Plasma protein electrophoresis reveals a high peak corresponding to gamma-globulins. The most likely diagnosis is:

- A. Iron deficiency (3%)
- B. Cobalamin deficiency (1%)
- C. Chronic lymphocytic leukemia (5%)
- D. Aplastic anemia (3%)
- ✓ E. Plasma cell neoplasm (81%)
- F. Hodgkin lymphoma (2%)
- G. Hypothyroidism (1%)

Omitted
Correct answer

81%
Answered correctly

04 secs
Time Spent

02/21/2020
Last Updated

8
9
10
11
12
13
14
15
16
17
18
19
20
21
22
23
24
25
26
27
28
29
30
31
32
33
34
35
36
37

In multiple myeloma, neoplastic B-lymphocytes mature into plasma cells that synthesize abnormal (typically large) amounts of monoclonal immunoglobulin or immunoglobulin fragments (e.g. light chains). Clinical manifestations of multiple myeloma include impaired hematopoiesis leading to a normochromic, normocytic anemia and weakness; lytic bone lesions classically affecting the vertebral column and causing back pain and pathologic fractures; and hypercalcemia and AL amyloidosis, which contribute to renal dysfunction. Severe amyloidosis can also cause cardiac and cutaneous findings.

The classic laboratory abnormalities in multiple myeloma include erythrocyte rouleaux formation on peripheral blood smear and Bence-Jones proteins in the urine. Serum protein electrophoresis (SPEP) is a more specific laboratory test used to determine if excessive monoclonal immunoglobulins are present in the serum. An "M peak" on SPEP indicates the presence of such an immunoglobulin. (An M peak may also be found in Waldenstrom macroglobulinemia and some lymphomas.)

(Choices A and B) Iron deficiency can cause weakness due to a hypochromic, microcytic anemia and vitamin B12 (cobalamin) deficiency can cause weakness due to a macrocytic anemia. Vitamin B12 deficiency can also cause neurologic signs.

(Choice C) CLL is a lymphocytic malignancy that may cause a normochromic, normocytic anemia, but immunoglobulin production is classically depressed, not increased, in CLL.

(Choice D) Aplastic anemia would cause a uniform depression of all hematologic cell lines, including leukocytes and platelets.

(Choice F) Hodgkin lymphoma is a B-cell malignancy characterized by the presence of Reed-Sternberg cells on lymph node histology. There may be anemia of chronic disease in patients with this condition, but a monoclonal gammopathy would not be expected.

(Choice G) Patients with hypothyroidism may be anemic due to associated iron deficiency or pernicious anemia. However, monoclonal gammopathy would not be expected.

Educational Objective:
The finding of a high peak in the gamma-globulin region on serum protein electrophoresis (SPEP) usually represents an M protein consisting of an overproduced monoclonal immunoglobulin. Multiple myeloma causes an M protein peak on SPEP as well as anemia (weakness), lytic bone lesions (back pain, pathologic fractures), and renal insufficiency (related to amyloid deposition and hypercalcemia).

Pathology Hematology & Oncology Multiple myeloma

and pathologic fractures; and hypercalcemia and AL amyloidosis, which contribute to renal dysfunction. Severe amyloidosis can also cause cardiac and cutaneous findings.

The classic laboratory abnormalities in multiple myeloma include erythrocyte rouleaux formation on peripheral blood smear and Bence-Jones proteins in the urine. Serum protein electrophoresis (SPEP) is a more specific laboratory test used to determine if excessive monoclonal immunoglobulins are present in the serum. An "M peak" on SPEP indicates the presence of such an immunoglobulin. (An M peak may also be found in Waldenstrom macroglobulinemia and some lymphomas.)

(Choices A and B) Iron deficiency can cause weakness due to a hypochromic, microcytic anemia and vitamin B12 (cobalamin) deficiency can cause weakness due to a macrocytic anemia. Vitamin B12 deficiency can also cause neurologic signs.

(Choice C) CLL is a lymphocytic malignancy that may cause a normochromic, normocytic anemia, but immunoglobulin production is classically depressed, not increased, in CLL.

(Choice D) Aplastic anemia would cause a uniform depression of all hematologic cell lines, including leukocytes and platelets.

(Choice F) Hodgkin lymphoma is a B-cell malignancy characterized by the presence of Reed-Sternberg cells on lymph node histology. There may be anemia of chronic disease in patients with this condition, but a monoclonal gammopathy would not be expected.

(Choice G) Patients with hypothyroidism may be anemic due to associated iron deficiency or pernicious anemia. However, monoclonal gammopathy would not be expected.

Educational Objective:
The finding of a high peak in the gamma-globulin region on serum protein electrophoresis (SPEP) usually represents an M protein consisting of an overproduced monoclonal immunoglobulin. Multiple myeloma causes an M protein peak on SPEP as well as anemia (weakness), lytic bone lesions (back pain, pathologic fractures), and renal insufficiency (related to amyloid deposition and hypercalcemia).

Pathology	Hematology & Oncology	Multiple myeloma
Subject	System	Topic

Copyright © UWorld. All rights reserved.

8 9 10 11 12 13 14 15 16 17 18 19 20 21 22 23 24 25 26 27 28 29 30 31 32 33 34 35 36 37

8
9
10
11
12
13
14
15
16
17
18
19
20
21
22
23
24
25
26
27
28
29
30
31
32
33
34
35
36
37

Rats subjected to chronic inhalation exposure of formaldehyde develop nasal squamous cell carcinomas. Decreased activity of which of the following genes is likely to be found on cytogenetic studies of the tumor cells?

A. *bcr-abl*

B. *Ras*

C. *Erb-B2*

D. p53

E. N-*myc*

Submit

8
9
10
11
12
13
14
15
16
17
18
19
20
21
22
23
24
25
26
27
28
29
30
31
32
33
34
35
36
37

Rats subjected to chronic inhalation exposure of formaldehyde develop nasal squamous cell carcinomas. Decreased activity of which of the following genes is likely to be found on cytogenetic studies of the tumor cells?

A. *bcr-abl* (2%)

B. *Ras* (8%)

C. *Erb-B2* (3%)

✓ D. p53 (78%)

E. N-*myc* (6%)

Omitted
Correct answer
D

78%
Answered correctly

02 secs
Time Spent

02/03/2020
Last Updated

Explanation

Decreased activity of a tumor suppressor gene would predispose to neoplasms. Of the choices listed, p53 is the only tumor suppressor gene. In normal individuals, p53 regulates cell proliferation. It acts during phase G1 of the cell cycle to detect abnormalities of the cellular genome. If there is damaged DNA, p53 will prevent the cell from progressing to mitosis, causing the cell to be arrested in the G1 phase. If the DNA can be repaired, the cell will subsequently be allowed to divide, but if the damage is so severe that repair is impossible, the cell will proceed instead to apoptosis. p53 is nicknamed "the molecular policeman" because of its important role in guarding the integrity of genetic material.

(Choice A) The *bcr-abl* fusion gene is a product of translocation of genetic material from chromosome 9 to chromosome 22 [t(9;22)]. It codes for

Correct answer
D

Answered correctly

Time Spent

Last Updated

Explanation

Decreased activity of a tumor suppressor gene would predispose to neoplasms. Of the choices listed, p53 is the only tumor suppressor gene. In normal individuals, p53 regulates cell proliferation. It acts during phase G1 of the cell cycle to detect abnormalities of the cellular genome. If there is damaged DNA, p53 will prevent the cell from progressing to mitosis, causing the cell to be arrested in the G1 phase. If the DNA can be repaired, the cell will subsequently be allowed to divide, but if the damage is so severe that repair is impossible, the cell will proceed instead to apoptosis. p53 is nicknamed "the molecular policeman" because of its important role in guarding the integrity of genetic material.

(Choice A) The *bcr-abl* fusion gene is a product of translocation of genetic material from chromosome 9 to chromosome 22 [t(9;22)]. It codes for a protein with tyrosine kinase activity. The *bcr-abl* translocation is the Philadelphia chromosome found in chronic myelogenous leukemia.

(Choice B) The *ras* proto-oncogene codes a protein that participates in signal transduction (MAP-kinase associated pathway). Over-expression of this gene leads to increased sensitivity of cells to mitogenic stimuli. This mutation occurs in a large number of cancers.

(Choice C) The *Erb-B2* gene encodes a protein with tyrosine kinase activity related to the epidermal growth factor receptor. Over-expression of this proto-oncogene is associated with breast and ovarian cancers.

(Choice E) Expression of the N-*myc* proto-oncogene is amplified in neuroblastoma.

Educational Objective:
p53 is a tumor suppressor gene that controls cell division and apoptosis. It is inactivated in many tumors.

Pathology	Hematology & Oncology	Oncogenes and tumor suppressor genes
Subject	System	Topic

Copyright © UWorld. All rights reserved.

8
9
10
11
12
13
14
15
16
17
18
19
20
21
22
23
24
25
26
27
28
29
30
31
32
33
34
35
36
37

11
12
13
14
15
16
17
18
19
20
21
22
23
24
25
26
27
28
29
30
31
32
33
34
35
36
37
38
39
40

A 28-year-old woman comes to the physician after finding a lump in her right breast. Her mother died from ovarian cancer at age 34 and her aunt died from breast cancer at age 32. After the appropriate workup, she is diagnosed with breast cancer. This patient most likely inherited a mutation in a gene normally responsible for which of the following processes?

A. Angiogenesis
B. DNA repair
C. Intercellular adhesion
D. Protein degradation
E. Signal transduction

Submit

11
12
13
14
15
16
17
18
19
20
21
22
23
24
25
26
27
28
29
30
31
32
33
34
35
36
37
38
39
40

A 28-year-old woman comes to the physician after finding a lump in her right breast. Her mother died from ovarian cancer at age 34 and her aunt died from breast cancer at age 32. After the appropriate workup, she is diagnosed with breast cancer. This patient most likely inherited a mutation in a gene normally responsible for which of the following processes?

- A. Angiogenesis (1%)
- ✓ B. DNA repair (65%)
- C. Intercellular adhesion (2%)
- D. Protein degradation (2%)
- E. Signal transduction (27%)

Omitted
Correct answer
B

65%
Answered correctly

02 secs
Time Spent

06/20/2020
Last Updated

Explanation

Proto-oncogenes 1-hit GAIN of function		Tumor suppressor genes 2-hit LOSS of function	
RAS (GTP-binding protein)	• Cholangiocarcinoma • Pancreatic adenocarcinoma	***BRCA1/2*** (DNA repair genes)	• Breast & ovarian cancer

11
12
13
14
15
16
17
18
19
20
21
22
23
24
25
26
27
28
29
30
31
32
33
34
35
36
37
38
39
40

Proto-oncogenes 1-hit GAIN of function		Tumor suppressor genes 2-hit LOSS of function	
RAS (GTP-binding protein)	• Cholangiocarcinoma • Pancreatic adenocarcinoma	***BRCA1/2*** (DNA repair genes)	• Breast & ovarian cancer
MYC (Transcription factor)	• Burkitt lymphoma	***APC/β-catenin*** (Wnt signaling pathway)	• Colon, gastric & pancreatic cancer • Familial adenomatous polyposis
ERBB1 (EGFR) (Receptor tyrosine kinase)	• Lung adenocarcinoma	***TP53*** (Genomic stability)	• Most cancers • Li-Fraumeni syndrome
ERBB2 (HER2) (Receptor tyrosine kinase)	• Breast cancer	***RB*** (G_1/S transition inhibitor)	• Retinoblastoma • Osteosarcoma
ABL		***WT1***	

11
12
13
14
15
16
17
18
19
20
21
22
23
24
25
26
27
28
29
30
31
32
33
34
35
36
37
38
39
40

ERBB1 (EGFR) (Receptor tyrosine kinase)	• Lung adenocarcinoma	***TP53*** (Genomic stability)	• Most cancers • Li-Fraumeni syndrome
ERBB2 (HER2) (Receptor tyrosine kinase)	• Breast cancer	***RB*** (G_1/S transition inhibitor)	• Retinoblastoma • Osteosarcoma
ABL (Nonreceptor tyrosine kinase)	• Chronic myelogenous leukemia	***WT1*** (Urogenital differentiation)	• Wilms tumor
BRAF (Ras signal transduction)	• Hairy cell leukemia • Melanoma	***VHL*** (Ubiquitin ligase component)	• Renal cell carcinoma • Von Hippel-Lindau syndrome

©UWorld

The majority of breast cancer cases occur sporadically in women age >50. **Hereditary breast cancer** should be suspected in patients diagnosed at a young age, patients with 2 or more primary breast and/or ovarian cancers, and individuals with multiple family members affected by early-onset breast or ovarian cancer. Most cases of hereditary breast and ovarian cancer are associated with mutations in the tumor suppressor genes ***BRCA1*** and ***BRCA2***. Tumor suppressor genes are involved in multiple processes, including:

11
12
13
14
15
16
17
18
19
20
21
22
23
24
25
26
27
28
29
30
31
32
33
34
35
36
37
38
39
40

The majority of breast cancer cases occur sporadically in women age >50. **Hereditary breast cancer** should be suspected in patients diagnosed at a young age, patients with 2 or more primary breast and/or ovarian cancers, and individuals with multiple family members affected by early-onset breast or ovarian cancer. Most cases of hereditary breast and ovarian cancer are associated with mutations in the tumor suppressor genes ***BRCA1*** and ***BRCA2***. Tumor suppressor genes are involved in multiple processes, including:

1. DNA repair
2. Cellular differentiation
3. Checkpoint control of the cell cycle
4. Transcription factor regulation

BRCA1 and BRCA2 in particular are involved in repair of **double-stranded DNA breaks**. Mutations in *BRCA1* and *BRCA2* result in genetic instability, predisposing cells to an increased risk of malignant transformation. Both *BRCA* mutations are inherited in an **autosomal dominant** manner with variable penetrance. Affected women have a **70%-80% lifetime risk** for developing breast cancer. Moreover, their lifetime risk of developing ovarian cancer is also increased by up to 40%, although the *BRCA2* gene is less likely to lead to ovarian cancer.

(Choice A) Angiogenesis is an essential factor in the growth of tumors due to their rapid rate of division and high metabolic demands. Although they stimulate angiogenesis by increasing production of substances such as vascular endothelial growth factor, tumors frequently outgrow their blood supply and become necrotic in the center.

(Choice C) Intercellular adhesion is impaired in the majority of malignant tumors, which allows portions of the tumor to break off and metastasize. Adhesion molecules such as E-cadherin are also responsible for transduction of growth signals important for normal tissue growth and regeneration; disruption of intercellular adhesion signaling can promote unchecked cellular proliferation.

(Choice D) Protein degradation is essential for regulation of cellular functions and is performed by the proteasome as well as cytosolic proteinases. Increased degradation of protective proteins such as p53 or decreased breakdown of proteins that favor cell division can lead to malignancy.

(Choice E) A large number of malignancies are associated with aberrant signal transduction. For example, overexpression of HER2 (a receptor tyrosine kinase involved in growth signal transduction) causes the development of certain types of aggressive breast cancer. Unlike *BRCA1* and *BRCA2*, *HER2* mutations are acquired, not inherited.

11 12 13 14 15 16 17 18 19 20 21 22 23 24 25 26 27 28 29 30 31 32 33 34 35 36 37 38 39 40

instability, predisposing cells to an increased risk of malignant transformation. Both *BRCA* mutations are inherited in an **autosomal dominant** manner with variable penetrance. Affected women have a **70%-80% lifetime risk** for developing breast cancer. Moreover, their lifetime risk of developing ovarian cancer is also increased by up to 40%, although the *BRCA2* gene is less likely to lead to ovarian cancer.

(Choice A) Angiogenesis is an essential factor in the growth of tumors due to their rapid rate of division and high metabolic demands. Although they stimulate angiogenesis by increasing production of substances such as vascular endothelial growth factor, tumors frequently outgrow their blood supply and become necrotic in the center.

(Choice C) Intercellular adhesion is impaired in the majority of malignant tumors, which allows portions of the tumor to break off and metastasize. Adhesion molecules such as E-cadherin are also responsible for transduction of growth signals important for normal tissue growth and regeneration; disruption of intercellular adhesion signaling can promote unchecked cellular proliferation.

(Choice D) Protein degradation is essential for regulation of cellular functions and is performed by the proteasome as well as cytosolic proteinases. Increased degradation of protective proteins such as p53 or decreased breakdown of proteins that favor cell division can lead to malignancy.

(Choice E) A large number of malignancies are associated with aberrant signal transduction. For example, overexpression of HER2 (a receptor tyrosine kinase involved in growth signal transduction) causes the development of certain types of aggressive breast cancer. Unlike *BRCA1* and *BRCA2*, *HER2* mutations are acquired, not inherited.

Educational objective:
Hereditary breast cancer is most commonly associated with mutations in *BRCA1* and *BRCA2*. These tumor suppressor genes are involved in DNA repair, and their mutation increases the risk of developing breast and ovarian cancer.

References

- Cancer risks for BRCA1 and BRCA2 mutation carriers: results from prospective analysis of EMBRACE.

Pathology	Hematology & Oncology	Breast cancer
Subject	System	Topic

Copyright © UWorld. All rights reserved.

11
12
13
14
15
16
17
18
19
20
21
22
23
24
25
26
27
28
29
30
31
32
33
34
35
36
37
38
39
40

A 30-year-old man with a history of intravenous drug abuse and known HIV infection comes to the emergency department because of increasing abdominal distention and anorexia. A CT scan of the abdomen shows ascites and a large mass surrounding the small intestine. Biopsy of the mass reveals uniform, round, medium-sized tumor cells with basophilic cytoplasm and a proliferation fraction (Ki-67 fraction) of > 99%. Which of the following infectious agents is most closely associated with the development of his current condition?

A. Epstein-Barr virus

B. Human papillomavirus serotype 31 or 33

C. *Helicobacter pylori*

D. Human herpesvirus 8

E. Hepatitis B

Submit

11
12
13
14
15
16
17
18
19
20
21
22
23
24
25
26
27
28
29
30
31
32
33
34
35
36
37
38
39
40

A 30-year-old man with a history of intravenous drug abuse and known HIV infection comes to the emergency department because of increasing abdominal distention and anorexia. A CT scan of the abdomen shows ascites and a large mass surrounding the small intestine. Biopsy of the mass reveals uniform, round, medium-sized tumor cells with basophilic cytoplasm and a proliferation fraction (Ki-67 fraction) of > 99%. Which of the following infectious agents is most closely associated with the development of his current condition?

- ✓ A. Epstein-Barr virus (45%)
- B. Human papillomavirus serotype 31 or 33 (3%)
- C. *Helicobacter pylori* (12%)
- D. Human herpesvirus 8 (21%)
- E. Hepatitis B (17%)

Omitted
Correct answer
A

45%
Answered correctly

02 secs
Time Spent

04/18/2020
Last Updated

Explanation

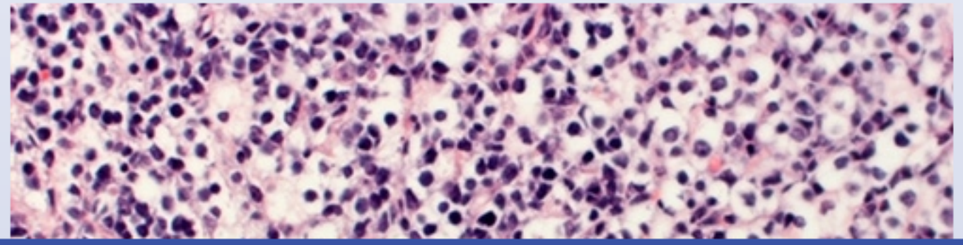

11
12
13
14
15
16
17
18
19
20
21
22
23
24
25
26
27
28
29
30
31
32
33
34
35
36
37
38
39
40

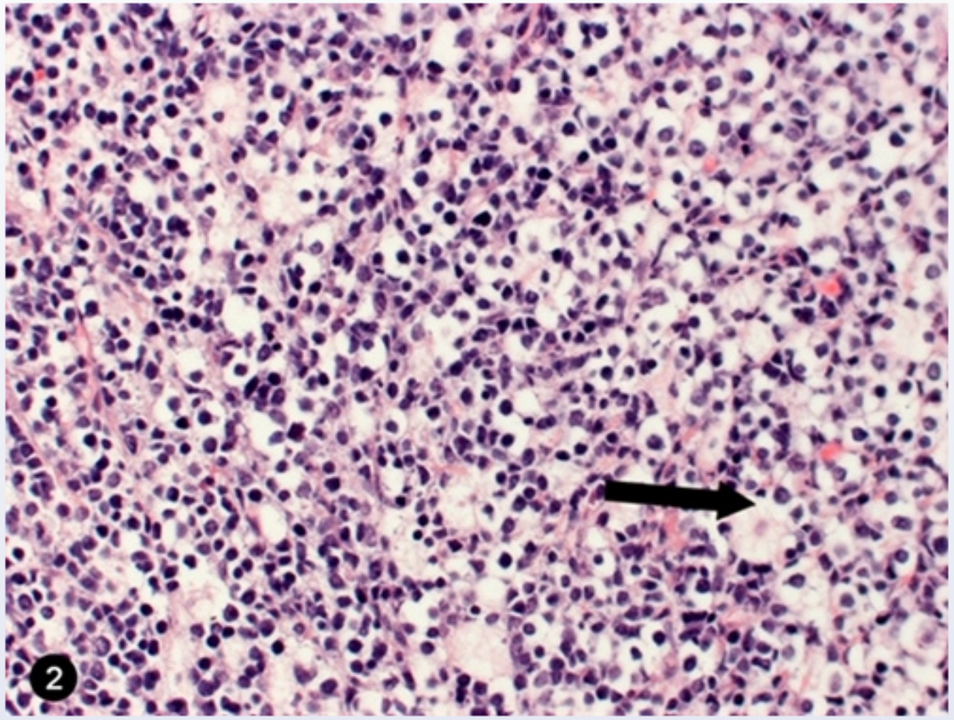

Epstein-Barr virus (EBV) is the etiologic agent most strongly associated with Burkitt lymphoma, with infection being present in 40% of immunodeficiency-associated Burkitt lymphoma and nearly all cases of endemic Burkitt lymphoma. A crucial step in the transformation of infected cells is the balanced t(8;14) translocation, which causes overexpression of c-MYC, a transcriptional regulator that controls cell proliferation. Chronic EBV infection increases B-cell proliferation and is thought to increase the risk of a c-MYC translocation. Pre-existing immunodeficiency secondary to HIV infection can potentiate EBV antigen-induced B-cell proliferation. The histology described is classic for Burkitt lymphoma: diffuse medium-sized lymphocytes and a high proliferation index represented by the high Ki-67 fraction (approaching 100%). The classic "starry sky" appearance is usually seen, and is due to the presence of benign macrophages (arrow in above image).

(Choice B) Human papillomavirus (HPV) types 31, 33, 35, and 51 have been identified in invasive squamous cancers of the cervix, although HPV 16 and 18 are most commonly associated. The viral DNA is usually integrated into the hostcell genome.

11 12 13 14 15 16 17 18 19 20 21 22 23 24 25 26 27 28 29 30 31 32 33 34 35 36 37 38 39 40

Epstein-Barr virus (EBV) is the etiologic agent most strongly associated with Burkitt lymphoma, with infection being present in 40% of immunodeficiency-associated Burkitt lymphoma and nearly all cases of endemic Burkitt lymphoma. A crucial step in the transformation of infected cells is the balanced t(8;14) translocation, which causes overexpression of c-MYC, a transcriptional regulator that controls cell proliferation. Chronic EBV infection increases B-cell proliferation and is thought to increase the risk of a c-MYC translocation. Pre-existing immunodeficiency secondary to HIV infection can potentiate EBV antigen-induced B-cell proliferation. The histology described is classic for Burkitt lymphoma: diffuse medium-sized lymphocytes and a high proliferation index represented by the high Ki-67 fraction (approaching 100%). The classic "starry sky" appearance is usually seen, and is due to the presence of benign macrophages (arrow in above image).

(Choice B) Human papillomavirus (HPV) types 31, 33, 35, and 51 have been identified in invasive squamous cancers of the cervix, although HPV 16 and 18 are most commonly associated. The viral DNA is usually integrated into the hostcell genome.

(Choice C) Although *H. pylori* infection may play a role in the development of gastrointestinal lymphomas, it more commonly causes chronic gastritis and peptic ulcer disease. Lymphomas associated with *H. pylori* infection would be expected to have a different type and histology (usually MALT lymphomas).

(Choice D) Human herpesvirus 8 infection can cause Kaposi's sarcoma and primary effusion lymphoma (arising from B-cells), most commonly in HIV infected patients. The histology of primary effusion lymphoma is distinct from Burkitt lymphoma, with large cells, big nuclei, and prominent nucleoli.

(Choice E) Hepatitis B infection can cause hepatocellular carcinoma. A CT scan would reveal the presence of a tumor mass or masses within the liver. Hepatocellular carcinoma, being derived from hepatocytes, is histologically and cytologically distinct from B-cell lymphomas.

Educational objective:
The Epstein-Barr virus genome is identified in approximately 50% of systemic B-cell lymphomas and almost all primary CNS lymphomas occurring in the setting of HIV infection. A high mitotic index is typical of Burkitt lymphoma.

Pathology	Hematology & Oncology	Burkitt lymphoma
Subject	System	Topic

Copyright © UWorld. All rights reserved.

11
12
13
14
15
16
17
18
19
20
21
22
23
24
25
26
27
28
29
30
31
32
33
34
35
36
37
38
39
40

Rats exposed to high concentrations of carbon tetrachloride suffer rapid and extensive liver damage. Light microscopic examination of affected liver specimens shows fatty change and hepatocyte necrosis. These changes are the result of:

A. Hypoperfusion

B. Hypoxia

C. Abnormal signal transduction

D. Free radical injury

E. Mitochondrial dysfunction

Submit

11
12
13
14
15
16
17
18
19
20
21
22
23
24
25
26
27
28
29
30
31
32
33
34
35
36
37
38
39
40

Rats exposed to high concentrations of carbon tetrachloride suffer rapid and extensive liver damage. Light microscopic examination of affected liver specimens shows fatty change and hepatocyte necrosis. These changes are the result of:

A. Hypoperfusion (1%)
B. Hypoxia (3%)
C. Abnormal signal transduction (2%)
✓ D. Free radical injury (73%)
E. Mitochondrial dysfunction (19%)

Omitted
Correct answer
D

73%
Answered correctly

02 secs
Time Spent

02/03/2020
Last Updated

Explanation

Carbon tetrachloride (CCl_4) causes free radical injury. Like many other toxic substances, CCl_4 is oxidized by the P450 oxidase system in the liver. The result is the formation of the free radical CCl_3, which reacts with structural lipids of cell membranes. The result is lipid degradation and hydrogen peroxide (H_2O_2) formation. This process is called **lipid peroxidation**. The peroxides go on to form new radicals, continuing the vicious circle of lipid degradation. Carbon tetrachloride cell injury develops rapidly and leads to swelling of the endoplasmic reticulum, destruction of mitochondria, and increased permeability of cell membranes. These processes culminate in hepatocyte necrosis.

(Choices A and B) Hypoperfusion and hypoxia lead to tissue ischemia and necrosis. Carbon tetrachloride does not affect tissue oxygenation.

(Choice C) Abnormal signal transduction is a mechanism of oncogenesis, as occurs with mutations of the *Ras* proto-oncogene. This mutation

11
12
13
14
15
16
17
18
19
20
21
22
23
24
25
26
27
28
29
30
31
32
33
34
35
36
37
38
39
40

Omitted
Correct answer
D

73%
Answered correctly

02 secs
Time Spent

02/03/2020
Last Updated

Explanation

Carbon tetrachloride (CCl_4) causes free radical injury. Like many other toxic substances, CCl_4 is oxidized by the P450 oxidase system in the liver. The result is the formation of the free radical CCl_3, which reacts with structural lipids of cell membranes. The result is lipid degradation and hydrogen peroxide (H_2O_2) formation. This process is called **lipid peroxidation**. The peroxides go on to form new radicals, continuing the vicious circle of lipid degradation. Carbon tetrachloride cell injury develops rapidly and leads to swelling of the endoplasmic reticulum, destruction of mitochondria, and increased permeability of cell membranes. These processes culminate in hepatocyte necrosis.

(Choices A and B) Hypoperfusion and hypoxia lead to tissue ischemia and necrosis. Carbon tetrachloride does not affect tissue oxygenation.

(Choice C) Abnormal signal transduction is a mechanism of oncogenesis, as occurs with mutations of the *Ras* proto-oncogene. This mutation increases cell sensitivity to mitogenic influences.

(Choice E) Mitochondrial dysfunction occurs in CCl_4 intoxication as a result of free radical injury.

Educational Objective:
The P450 microsomal oxidase system plays an important role in detoxification. In carbon tetrachloride poisoning, however, it produces free radicals that start a vicious cycle of hepatic injury.

Pathology	Hematology & Oncology	Acute liver failure
Subject	System	Topic

Copyright © UWorld. All rights reserved.

A 64-year-old man is brought to the hospital by ambulance after being found unresponsive by his brother. Despite resuscitative efforts, he dies shortly thereafter. The family reports that the patient had 2 months of progressive fatigue and an unintentional weight loss prior to the episode. Autopsy examination reveals a massive pulmonary embolus, and a cross-section of the liver shows the following:

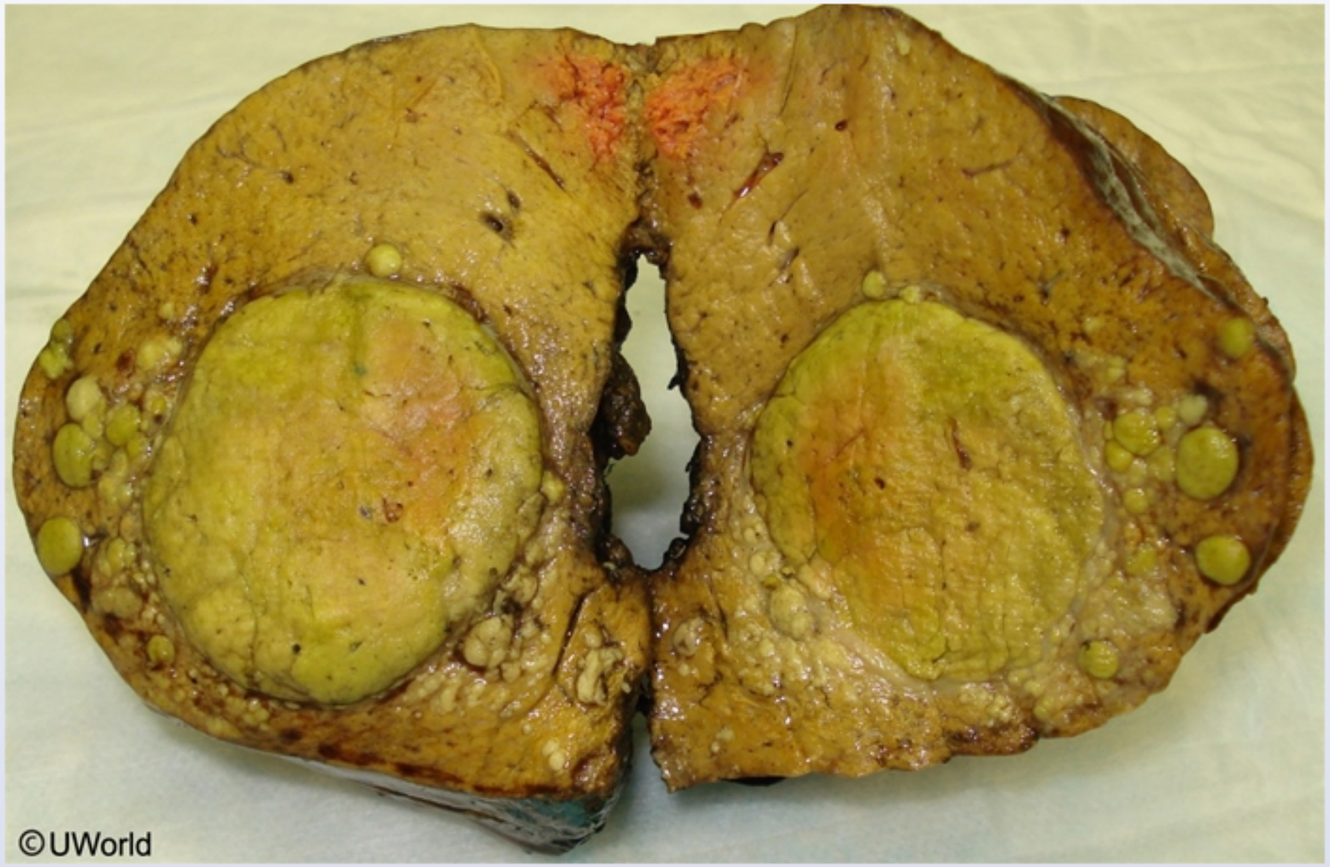

Genomic analysis of the hepatic lesions demonstrates intranuclear fragments of foreign DNA. These fragments most likely belong to which of the following pathogens?

Genomic analysis of the hepatic lesions demonstrates intranuclear fragments of foreign DNA. These fragments most likely belong to which of the following pathogens?

- A. Cytomegalovirus
- B. *Entamoeba histolytica*
- C. Epstein-Barr virus
- D. Hepatitis B virus
- E. Hepatitis C virus
- F. Human papilloma virus

Submit

Genomic analysis of the hepatic lesions demonstrates intranuclear fragments of foreign DNA. These fragments most likely belong to which of the following pathogens?

- A. Cytomegalovirus (5%)
- B. *Entamoeba histolytica* (12%)
- C. Epstein-Barr virus (5%)
- ✓ D. Hepatitis B virus (52%)
- E. Hepatitis C virus (22%)
- F. Human papilloma virus (0%)

Omitted
Correct answer

52%
Answered correctly

07 secs
Time Spent

01/24/2020
Last Updated

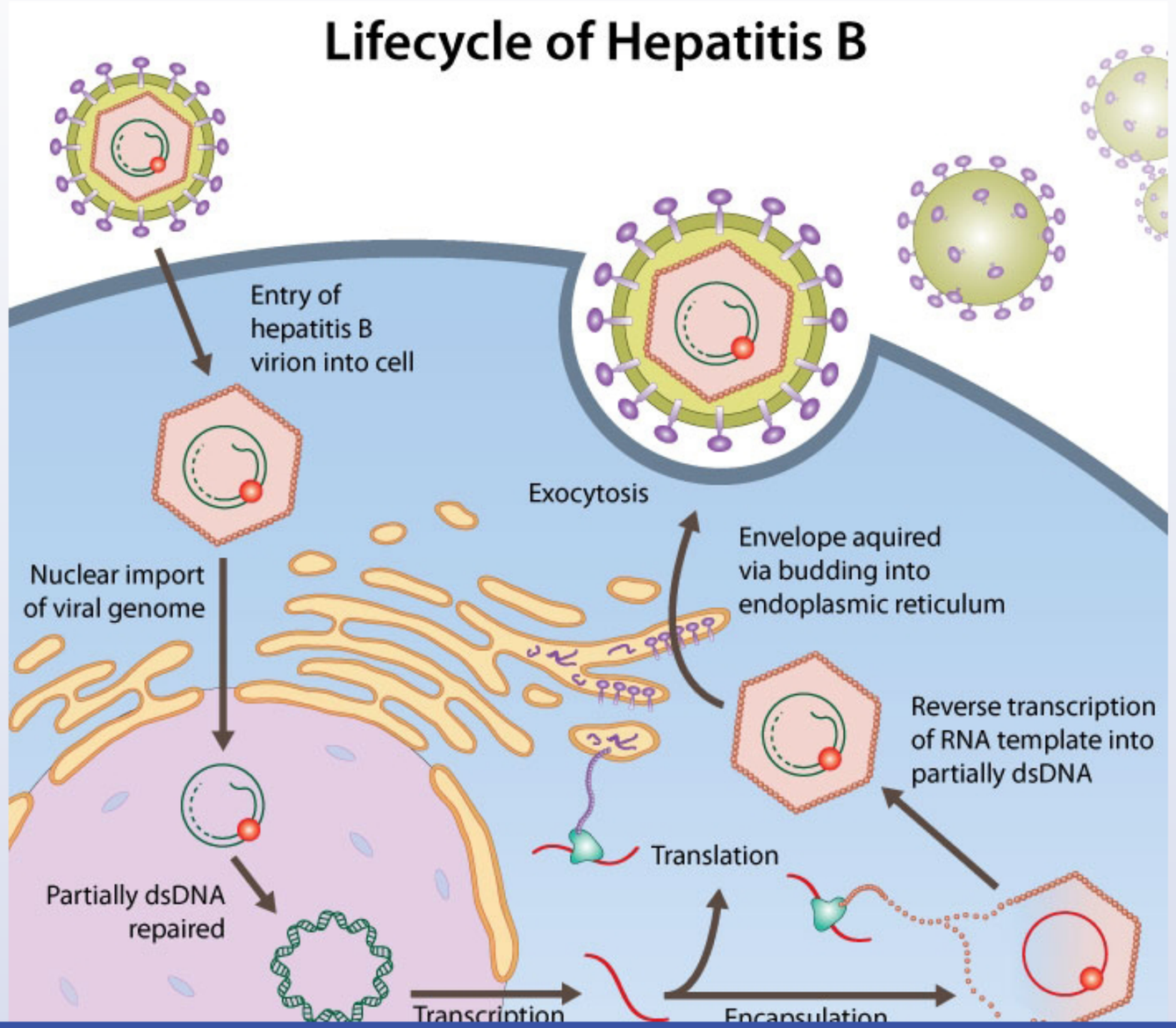
Lifecycle of Hepatitis B
Entry of hepatitis B virion into cell
Exocytosis
Envelope aquired via budding into endoplasmic reticulum
Nuclear import of viral genome
Reverse transcription of RNA template into partially dsDNA
Translation
Partially dsDNA repaired
Transcription
Encapsulation

©UWorld

Chronic hepatitis B virus (HBV) and hepatitis C virus (HCV) infections dramatically increase the risk of **hepatocellular carcinoma** (HCC). Ongoing infection with either virus leads to **increased hepatocyte turnover** and the generation of local inflammatory cytokines, which can result in genetic mutations that lead to malignant transformation. However, **HBV** has several additional mechanisms that promote HCC, including the following:

- **Integration into the host genome** – Nearly 90% of patients with chronic HBV who develop HCC have evidence of HBV DNA in the chromosome of tumor cells. HBV is a partially double-stranded DNA virus that is repaired by host cell machinery into a covalently closed circular DNA strand. Although it is not required for viral replication (unlike HIV), HBV DNA is often inserted into the cellular genome by host topoisomerase I. Integration into regions that control cell growth and differentiation can result in insertional mutagenesis.
- **Production of oncogenic viral proteins** – HBV produces a viral protein called **HBx** that is a transcriptional activator of several genes associated with cellular growth. It also interferes with the function of p53, an important tumor-suppressor protein.

(Choices A and C) Cytomegalovirus and Epstein-Barr virus are members of the *Herpesviridae* family. Both have double-stranded DNA genomes and cause acute infection followed by latent infection. Cytomegalovirus is not particularly associated with cancer, but Epstein-Barr infection is linked to nasopharyngeal carcinoma and hematologic malignancies. However, neither virus incorporates its genome into the host cell.

(Choice B) *Entamoeba histolytica* is a protozoal infection that is typically acquired by ingesting contaminated food or water in developing countries. A minority of patients develops invasive disease with liver abscess. This usually presents with fever and right-upper quadrant pain. The organism does not incorporate its genome into host cells.

(Choice E) Chronic HCV infection dramatically increases the risk of HCC. However, HCV is an RNA virus (that does not have reverse transcriptase) and is unable to integrate into the host genome.

(Choice F) Human papilloma virus is a double-stranded DNA virus of the papillomavirus family. HPV produces oncogenic proteins and is able to integrate into the host chromosome. However, HPV is not linked with liver cancer; it typically causes cervical and oropharyngeal cancer.

Educational objective:
Both hepatitis B (HBV) and hepatitis C virus infections increase the risk of hepatocellular carcinoma due to chronic hepatic inflammation and cell turnover. HBV is also carcinogenic due to the production of oncogenic proteins and the insertion of the HBV genome into the host chromosome.

circular DNA strand. Although it is not required for viral replication (unlike HIV), HBV DNA is often inserted into the cellular genome by host topoisomerase I. Integration into regions that control cell growth and differentiation can result in insertional mutagenesis.

- **Production of oncogenic viral proteins** – HBV produces a viral protein called **HBx** that is a transcriptional activator of several genes associated with cellular growth. It also interferes with the function of p53, an important tumor-suppressor protein.

(Choices A and C) Cytomegalovirus and Epstein-Barr virus are members of the *Herpesviridae* family. Both have double-stranded DNA genomes and cause acute infection followed by latent infection. Cytomegalovirus is not particularly associated with cancer, but Epstein-Barr infection is linked to nasopharyngeal carcinoma and hematologic malignancies. However, neither virus incorporates its genome into the host cell.

(Choice B) *Entamoeba histolytica* is a protozoal infection that is typically acquired by ingesting contaminated food or water in developing countries. A minority of patients develops invasive disease with liver abscess. This usually presents with fever and right-upper quadrant pain. The organism does not incorporate its genome into host cells.

(Choice E) Chronic HCV infection dramatically increases the risk of HCC. However, HCV is an RNA virus (that does not have reverse transcriptase) and is unable to integrate into the host genome.

(Choice F) Human papilloma virus is a double-stranded DNA virus of the papillomavirus family. HPV produces oncogenic proteins and is able to integrate into the host chromosome. However, HPV is not linked with liver cancer; it typically causes cervical and oropharyngeal cancer.

Educational objective:
Both hepatitis B (HBV) and hepatitis C virus infections increase the risk of hepatocellular carcinoma due to chronic hepatic inflammation and cell turnover. HBV is also carcinogenic due to the production of oncogenic proteins and the insertion of the HBV genome into the host chromosome.

References

- Role of hepatitis B virus DNA integration in human hepatocarcinogenesis.

Pathology	Hematology & Oncology	Hepatocellular cancer
Subject	System	Topic

Copyright © UWorld. All rights reserved.

A 43-year-old man comes to the hospital due to recurrent episodes of fever and sore throat despite multiple courses of antibiotic therapy. For the past several months, he has also felt "run down" and fatigued all the time. His wife adds that he bruises easily and has had bleeding gums on several occasions. His temperature is 37.8 C (100.2 F). On examination, he has mucosal pallor, pharyngeal erythema, and multiple ecchymoses on his extremities. His peripheral blood smear is shown in the image below.

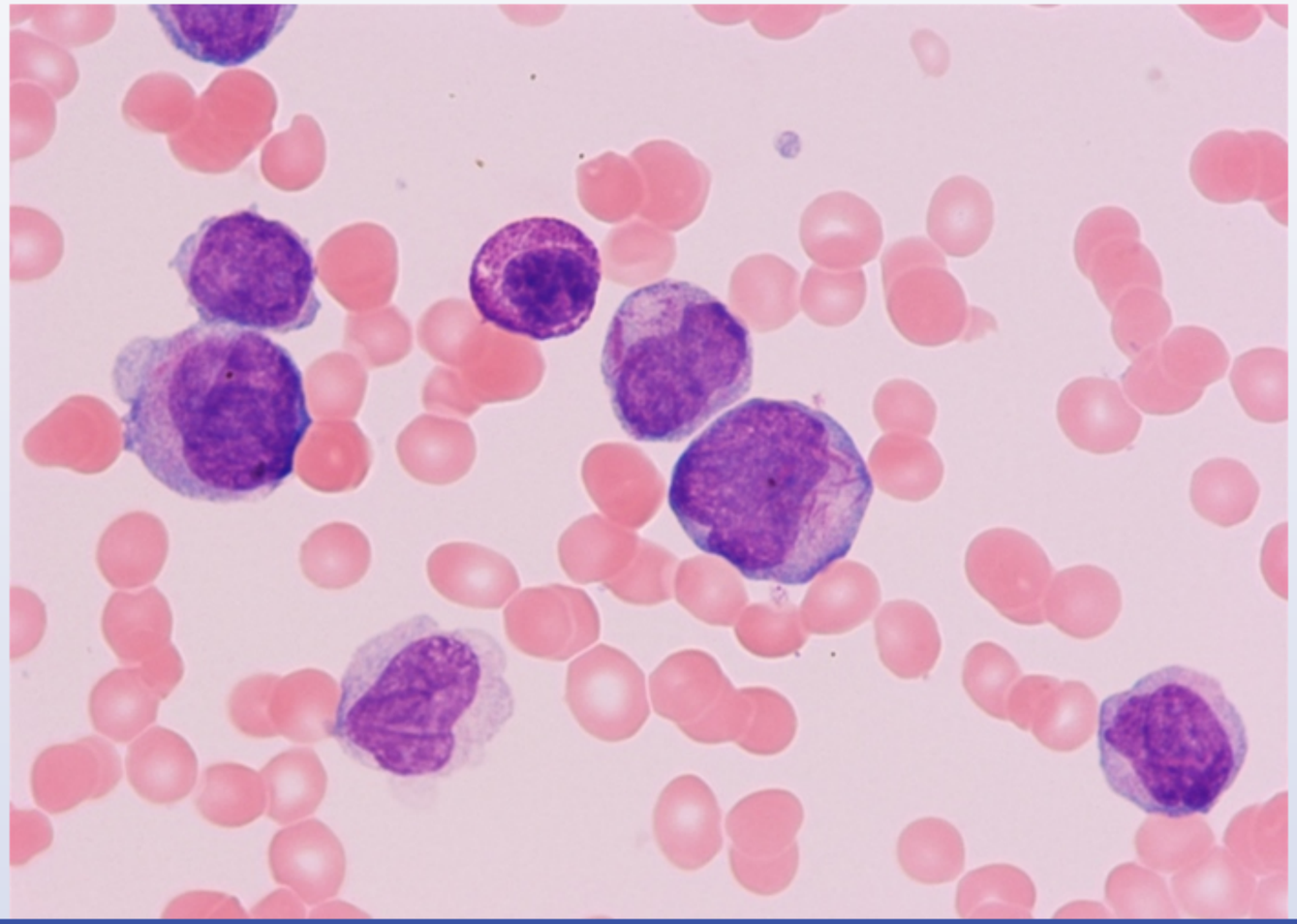

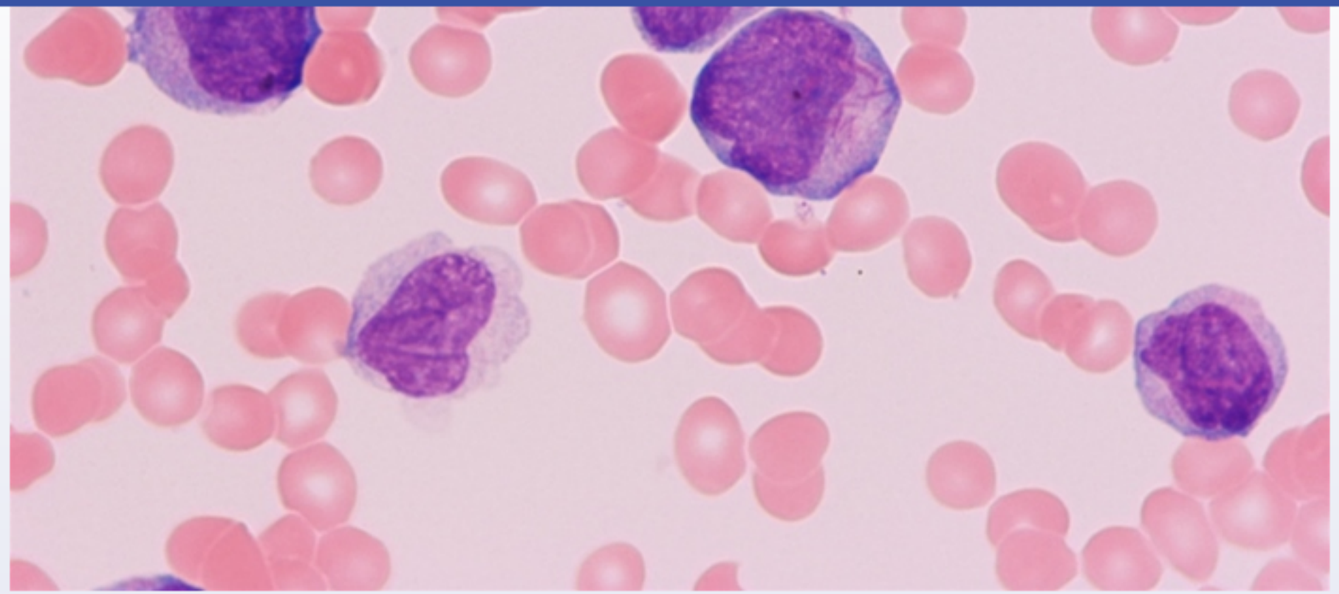

Which of the following chromosomal abnormalities is most likely present in the affected cells?

- A. t(8;14)
- B. t(9;22)
- C. t(11;14)
- D. t(15;17)
- E. 13q-

Submit

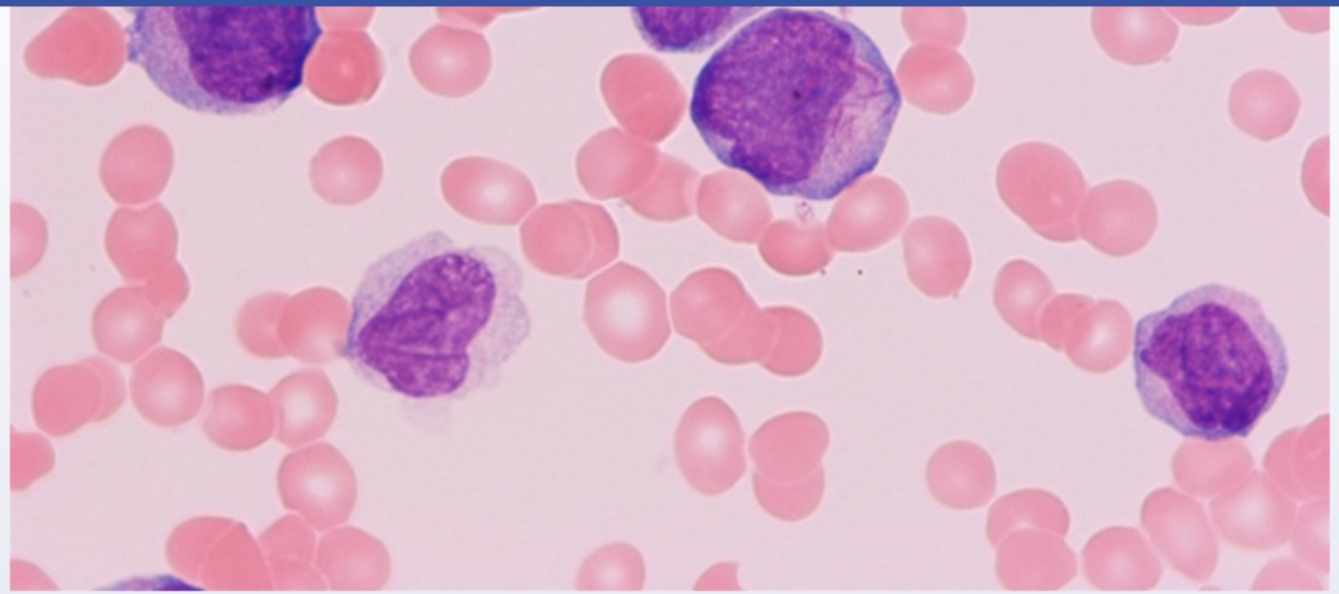

Which of the following chromosomal abnormalities is most likely present in the affected cells?

- A. t(8;14) (6%)
- B. t(9;22) (21%)
- C. t(11;14) (5%)
- ✓ D. t(15;17) (66%)
- E. 13q- (0%)

Omitted
Correct answer

66%
Answered correctly

04 secs
Time Spent

06/01/2020
Last Updated

Explanation

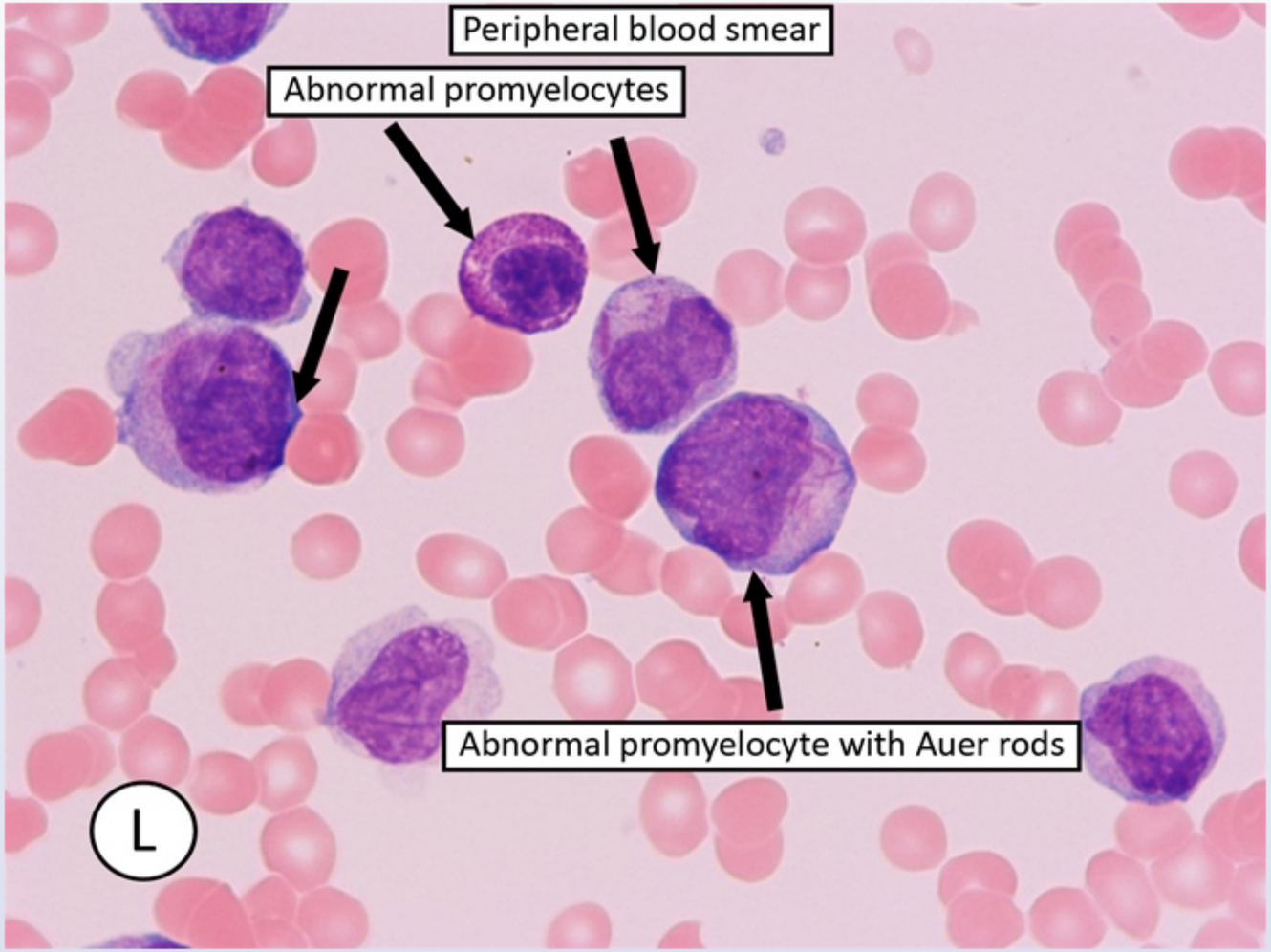

This patient has recurrent infections (possibly reflecting neutropenia), pallor (anemia), and ecchymoses (thrombocytopenia), with a peripheral blood smear that shows several abnormal myelocyte precursors containing coarse rod-shaped intracytoplasmic granules called **Auer rods**. This

This patient has recurrent infections (possibly reflecting neutropenia), pallor (anemia), and ecchymoses (thrombocytopenia), with a peripheral blood smear that shows several abnormal myelocyte precursors containing coarse rod-shaped intracytoplasmic granules called **Auer rods**. This presentation is characteristic of **acute myelogenous leukemia** (AML). The **M3** variant of AML, **acute promyelocytic leukemia** (APML), characterized by the presence of promyelocytes on smear, is associated with disseminated intravascular coagulation (bleeding, thrombocytopenia, prolonged prothrombin and activated thromboplastin time). Affected cells exhibit the cytogenetic abnormality **t(15;17)**.

This cytogenetic change represents a translocation between the retinoic acid receptor alpha (*RARα*) gene on chromosome 17 and the promyelocytic leukemia (*PML*) gene on chromosome 15. Fusion of these 2 genes produces a chimeric gene product, *PML/RARα*, which codes for an abnormal retinoic acid receptor. This abnormal fusion gene inhibits promyelocyte differentiation and triggers the development of APML. Management is with all-trans retinoic acid.

(Choice A) With t(8;14), associated with Burkitt lymphoma, there is a translocation between the c-*Myc* protooncogene on chromosome 8 and the Ig heavy chain region on chromosome 14. This leads to increased production of the oncogene due to the frequency with which the Ig gene is transcribed.

(Choice B) Translocation of the *ABL* gene from chromosome 9 to chromosome 22 is characteristic of chronic myelogenous leukemia. t(9;22) forms the "Philadelphia chromosome" and results in the formation of a new gene, *BCR-ABL*, whose product has tyrosine kinase activity.

(Choice C) Mantle cell lymphoma is a B-cell malignancy associated with t(11;14). This translocation results in activation of the cyclin D gene.

(Choice E) Deletion of 13q is one of the molecular defects seen in chronic lymphocytic leukemia.

Educational objective:
The presence of rod-shaped intracytoplasmic inclusions known as Auer rods is characteristic of many forms of acute myeloblastic leukemia (AML). The M3 variant of AML, acute promyelocytic leukemia, is associated with the cytogenetic abnormality t(15;17).

Pathology	Hematology & Oncology	Acute promyelocytic leukemia
Subject	System	Topic

Copyright © UWorld. All rights reserved.

This patient has recurrent infections (possibly reflecting neutropenia), pallor (anemia), and ecchymoses (thrombocytopenia), with a peripheral blood smear that shows several abnormal myelocyte precursors containing coarse rod-shaped intracytoplasmic granules called **Auer rods**. This presentation is characteristic of **acute myelogenous leukemia** (AML). The **M3** variant of AML, **acute promyelocytic leukemia** (APML), characterized by the presence of promyelocytes on smear, is associated with disseminated intravascular coagulation (bleeding, thrombocytopenia, prolonged prothrombin and activated thromboplastin time). Affected cells exhibit the cytogenetic abnormality **t(15;17)**.

This cytogenetic change represents a translocation between the retinoic acid receptor alpha (*RARα*) gene on chromosome 17 and the promyelocytic leukemia (*PML*) gene on chromosome 15. Fusion of these 2 genes produces a chimeric gene product, *PML/RARα*, which codes for an abnormal retinoic acid receptor. This abnormal fusion gene inhibits promyelocyte differentiation and triggers the development of APML. Management is with all-trans retinoic acid.

(Choice A) With t(8;14), associated with Burkitt lymphoma, there is a translocation between the c-*Myc* protooncogene on chromosome 8 and the Ig heavy chain region on chromosome 14. This leads to increased production of the oncogene due to the frequency with which the Ig gene is transcribed.

(Choice B) Translocation of the *ABL* gene from chromosome 9 to chromosome 22 is characteristic of chronic myelogenous leukemia. t(9;22) forms the "Philadelphia chromosome" and results in the formation of a new gene, *BCR-ABL*, whose product has tyrosine kinase activity.

(Choice C) Mantle cell lymphoma is a B-cell malignancy associated with t(11;14). This translocation results in activation of the cyclin D gene.

(Choice E) Deletion of 13q is one of the molecular defects seen in chronic lymphocytic leukemia.

Educational objective:
The presence of rod-shaped intracytoplasmic inclusions known as Auer rods is characteristic of many forms of acute myeloblastic leukemia (AML). The M3 variant of AML, acute promyelocytic leukemia, is associated with the cytogenetic abnormality t(15;17).

Pathology	Hematology & Oncology	Acute promyelocytic leukemia
Subject	System	Topic

Copyright © UWorld. All rights reserved.

A 48-year-old woman comes to the office due to a sore throat for the past 3 months. On examination, she is found to have an enlarged, ulcerated left tonsil and a firm, nontender, nonmobile left neck mass. The patient undergoes biopsy of the tonsil. Pathology is consistent with squamous cell carcinoma. Further analysis of the biopsy specimen shows expression of viral genome proteins. Which of the following most likely predisposed the patient to the development of this malignancy?

A. Decreased activity of *BRAF*-associated protein

B. Decreased activity of *RB*-associated protein

C. Decreased activity of *RET*-associated protein

D. Overexpression of *BRCA1*- or *BRCA2*-associated protein

E. Overexpression of *MEN1*-associated protein

Submit

A 48-year-old woman comes to the office due to a sore throat for the past 3 months. On examination, she is found to have an enlarged, ulcerated left tonsil and a firm, nontender, nonmobile left neck mass. The patient undergoes biopsy of the tonsil. Pathology is consistent with squamous cell carcinoma. Further analysis of the biopsy specimen shows expression of viral genome proteins. Which of the following most likely predisposed the patient to the development of this malignancy?

- A. Decreased activity of *BRAF*-associated protein (19%)
- ✓ B. Decreased activity of *RB*-associated protein (61%)
- C. Decreased activity of *RET*-associated protein (12%)
- D. Overexpression of *BRCA1*- or *BRCA2*-associated protein (1%)
- E. Overexpression of *MEN1*-associated protein (4%)

Omitted
Correct answer
B

61%
Answered correctly

02 secs
Time Spent

02/27/2020
Last Updated

Explanation

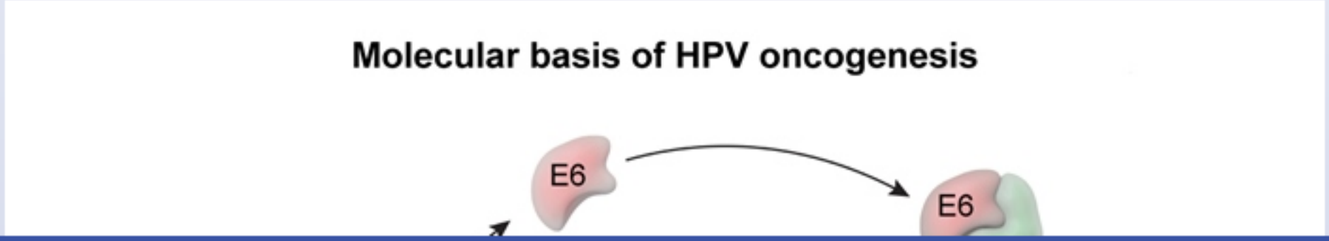

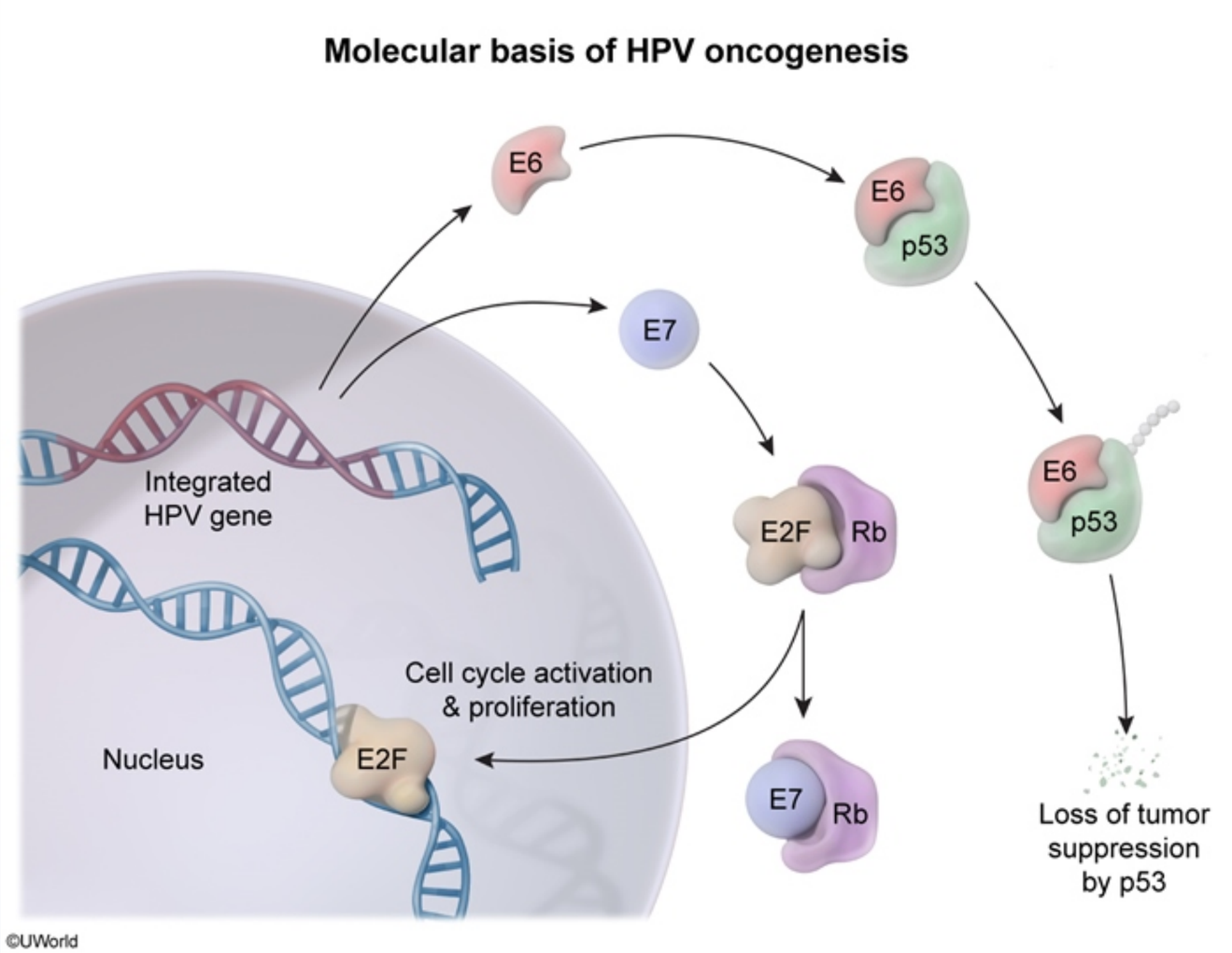

Tumor formation is driven by the accumulation of mutations that lead to **uncontrolled cell growth**. Two types of genes can be altered to increase malignant potential:

by p53

©UWorld

Tumor formation is driven by the accumulation of mutations that lead to **uncontrolled cell growth**. Two types of genes can be altered to increase malignant potential:

- **Protooncogenes** (eg, *RET*), which require **gain-of-function** mutations to convert to oncogenes. They typically encode proteins that **promote cell division** (eg, growth factors, receptors, signal transduction factors). Only one allele must be damaged to increase the risk of cancer formation.
- **Tumor suppressor** genes (eg, *TP53*, *RB*), in which **loss of function** results in unregulated growth. They typically encode proteins involved in apoptosis or inhibition of cell cycle progression; both alleles must be inactivated to increase the risk of malignancy.

Oncoviruses can induce cancer-forming mutations through the expression of proteins that activate protooncogenes or inactivate tumor suppressor genes. Human papillomavirus (HPV) is implicated in several types of cancer, including head and neck, cervical, anal, and penile cancer. HPV produces **viral oncoproteins E6 and E7**, both of which affect tumor suppressors:

- HPV viral protein E6 binds to p53, a tumor suppressor protein that normally inhibits the proliferation of cells with genetic abnormalities. Ubiquitination of the E6-p53 complex induces **degradation of p53**, leading to unregulated cellular growth.
- HPV viral protein E7 **binds to** retinoblastoma **(Rb)** protein, which results in the displacement of E2F (a transcription factor that induces cell cycle activation), promoting unregulated DNA replication and cyclin-mediated cell cycling.

(Choices A and C) *BRAF* encodes for a serine/threonine–specific protein kinase involved in regulating the mitogen-activated protein kinase signaling pathway. It is often mutated in melanoma, non-Hodgkin lymphoma, and papillary thyroid cancer. *RET* encodes for a receptor tyrosine kinase and is associated with multiple endocrine neoplasia (MEN) 2A, MEN 2B, and papillary thyroid cancer. Both *RET* and *BRAF* are protooncogenes that require gain-of-function mutations to become oncogenes. Decreased activity can protect against uncontrolled proliferation (eg, BRAF inhibitors used in melanoma).

(Choices D and E) *BRCA1* and *BRCA2* (associated with breast, ovarian, and pancreatic cancers) encode a DNA repair protein. *MEN1* (associated with MEN1) encodes for the protein menin, which has diverse functions that may be related to regulation of cell cycle kinase inhibitor and homeobox genes. Both *BRCA1/2* and *MEN1* are tumor suppressor genes, meaning that their inactivation (rather than overexpression) leads to tumor development.

by p53

Exhibit Display

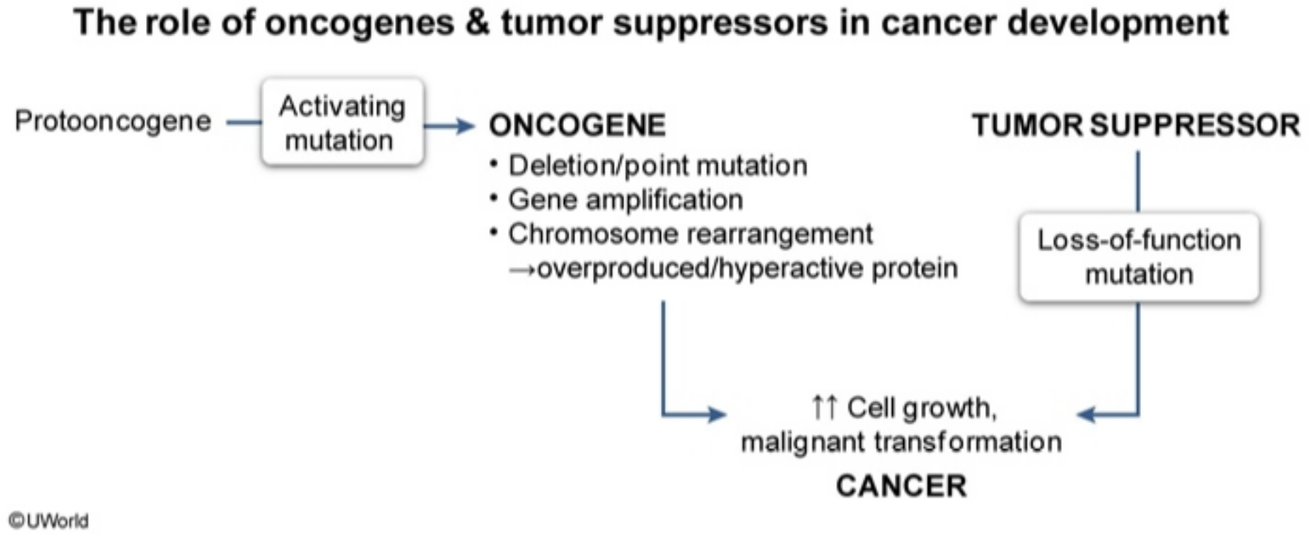

Zoom In Zoom Out Reset Add To Flash Card

to tumor development.

by p53

Exhibit Display

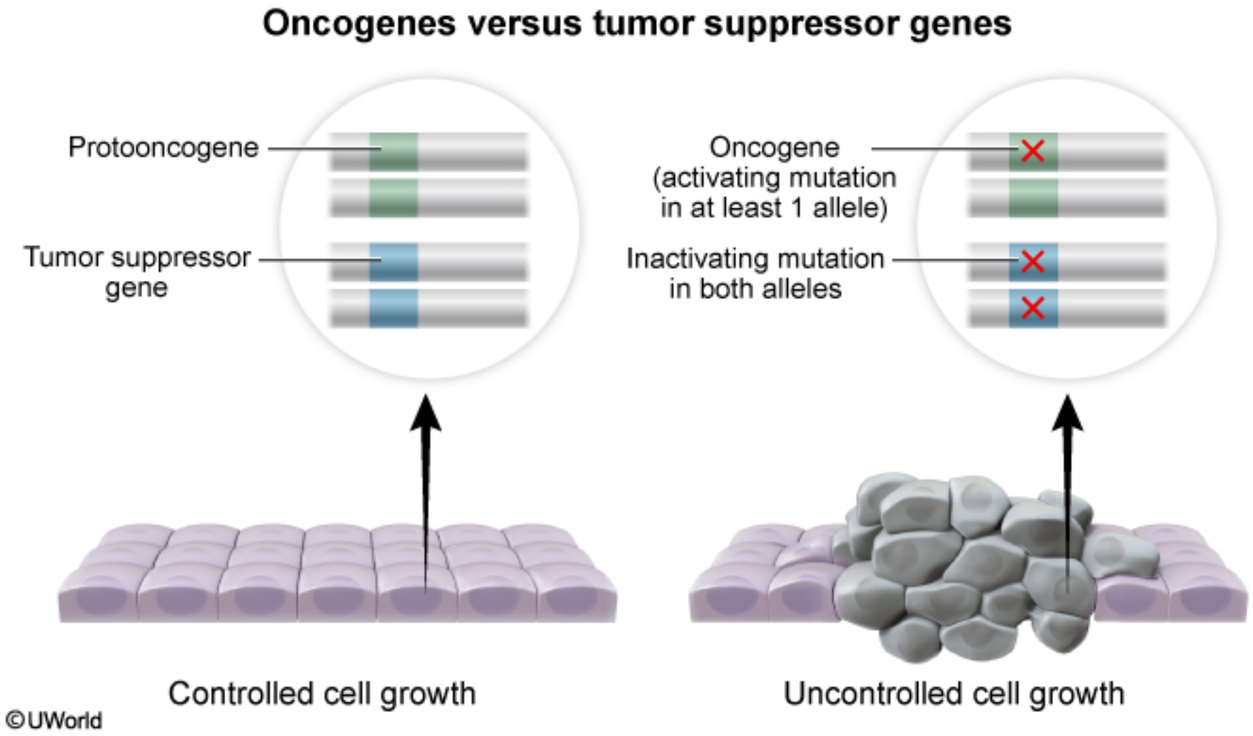

Zoom In Zoom Out Reset Add To Flash Card

to tumor development.

produces **viral oncoproteins E6 and E7**, both of which affect tumor suppressors:

- HPV viral protein E6 binds to p53, a tumor suppressor protein that normally inhibits the proliferation of cells with genetic abnormalities. Ubiquitination of the E6-p53 complex induces **degradation of p53**, leading to unregulated cellular growth.
- HPV viral protein E7 **binds to** retinoblastoma **(Rb)** protein, which results in the displacement of E2F (a transcription factor that induces cell cycle activation), promoting unregulated DNA replication and cyclin-mediated cell cycling.

(Choices A and C) *BRAF* encodes for a serine/threonine–specific protein kinase involved in regulating the mitogen-activated protein kinase signaling pathway. It is often mutated in melanoma, non-Hodgkin lymphoma, and papillary thyroid cancer. *RET* encodes for a receptor tyrosine kinase and is associated with multiple endocrine neoplasia (MEN) 2A, MEN 2B, and papillary thyroid cancer. Both *RET* and *BRAF* are protooncogenes that require gain-of-function mutations to become oncogenes. Decreased activity can protect against uncontrolled proliferation (eg, BRAF inhibitors used in melanoma).

(Choices D and E) *BRCA1* and *BRCA2* (associated with breast, ovarian, and pancreatic cancers) encode a DNA repair protein. *MEN1* (associated with MEN1) encodes for the protein menin, which has diverse functions that may be related to regulation of cell cycle kinase inhibitor and homeobox genes. Both *BRCA1/2* and *MEN1* are tumor suppressor genes, meaning that their inactivation (rather than overexpression) leads to tumor development.

Educational objective:
Inactivation of retinoblastoma protein activity by human papillomavirus can lead to the formation of head and neck squamous cell carcinoma.

References

- The role of HPV E6 and E7 oncoproteins in HPV-associated cervical carcinogenesis.
- The molecular landscape of head and neck cancer.

Pathology	Hematology & Oncology	Oncogenes and tumor suppressor genes
Subject	System	Topic

Copyright © UWorld. All rights reserved.

A 76-year-old man comes to the office with a 2-month history of progressive low back pain. The pain is relatively constant and nagging and is unrelieved by rest or position changes. It is especially bad at night and interferes with sleep. The patient has taken acetaminophen and ibuprofen without relief. Medical history is significant for hypertension and osteoarthritis affecting the knees and hands. The patient used intravenous drugs occasionally when he was younger but not for >30 years. Which of the following processes is most likely responsible for this patient's back pain?

A. Degenerative
B. Infectious
C. Inflammatory
D. Neoplastic
E. Psychogenic

Submit

A 76-year-old man comes to the office with a 2-month history of progressive low back pain. The pain is relatively constant and nagging and is unrelieved by rest or position changes. It is especially bad at night and interferes with sleep. The patient has taken acetaminophen and ibuprofen without relief. Medical history is significant for hypertension and osteoarthritis affecting the knees and hands. The patient used intravenous drugs occasionally when he was younger but not for >30 years. Which of the following processes is most likely responsible for this patient's back pain?

A. Degenerative (36%)
B. Infectious (3%)
C. Inflammatory (4%)
✓ D. Neoplastic (55%)
E. Psychogenic (0%)

Omitted
Correct answer
D

55%
Answered correctly

01 sec
Time Spent

03/27/2020
Last Updated

Explanation

Differential diagnosis of back pain	
Condition	**Clinical clues**
Degenerative (osteoarthritis)	• Positional • **Relieved with rest**

Differential diagnosis of back pain	
Condition	**Clinical clues**
Degenerative (osteoarthritis)	• Positional • **Relieved with rest**
Radiculopathy (eg, disc herniation)	• **Radiates** to leg • Sensory & motor findings • Positive **straight-leg raising test**
Spinal stenosis	• Pain with standing (spinal extension) • Relieved by spinal flexion
Spondyloarthropathy	• Young men • HLA-B27 • **Relieved with exercise** • Prolonged morning stiffness
Spinal metastasis	• Constant pain • Worse at night • Not responsive to position changes
Vertebral osteomyelitis	• Focal tenderness • Fevers & night sweats • Recent **infection**, **intravenous** drug abuse, or immune compromise

Back pain is common, and the majority of cases are due to benign skeletal (eg, osteoarthritis, spinal stenosis, disc herniation) or muscular (eg, muscle strain) conditions. The most common causes of back pain generally worsen with activity and improve with rest, postural modifications (eg, spinal stenosis worsens with back extension and is relieved with flexion), and analgesic therapy.

Back pain is common, and the majority of cases are due to benign skeletal (eg, osteoarthritis, spinal stenosis, disc herniation) or muscular (eg, muscle strain) conditions. The most common causes of back pain generally worsen with activity and improve with rest, postural modifications (eg, spinal stenosis worsens with back extension and is relieved with flexion), and analgesic therapy.

However, this patient's **constant** back pain that fails to improve with positional changes, rest, or analgesics is concerning for a more serious condition (infection, malignancy). This pattern of pain in an **older patient** (age >50) without a recent history of intravenous drug use should raise suspicion for a **neoplastic process**, particularly if the pain is worse at night (**nocturnal pain**). Other features that raise concern for malignancy include a personal history of cancer, weight loss, neurologic deficits (eg, weakness), and point tenderness on the spinous processes.

Malignancies with a propensity for bony metastasis include **P**rostate, **B**reast, **K**idney, **T**hyroid, and **L**ung (mnemonic: **Pb KTL**, or **"lead kettle"**). Prostate cancer is the most common malignancy in older men and frequently metastasizes to the axial skeleton and femur.

(Choice A) Degenerative disorders in the spine (eg, facet osteoarthritis) are typically relieved with rest and while in bed overnight; this patient's constant pain that persists overnight is more worrisome for malignancy.

(Choice B) Vertebral osteomyelitis (pain at rest, focal tenderness) and epidural abscess (nerve root compression, radicular symptoms) can be associated with intravenous drug use but typically occur following recent use, not decades later, and are usually associated with systemic symptoms (eg, fever, night sweats).

(Choice C) Inflammatory back pain (eg, spondyloarthropathy) is characterized by slowly progressive pain that is often worse at night. However, it is associated with prolonged morning stiffness (eg, hours) and improves with exercise. In addition, onset almost always occurs at age <45.

(Choice E) Back pain may be psychogenic (eg, factitious, malingering). Evidence of secondary gain (eg, litigation/compensation) and an unusual pattern of signs and symptoms can help identify these patients.

Educational objective:
Clinical features that suggest a malignant cause of back pain include persistent pain at night, no relief with rest, onset at age >50, and systemic symptoms. Common malignancies with a propensity for bony metastasis include prostate, breast, kidney, thyroid, and lung.

Pathology	Hematology & Oncology	Prostate cancer
Subject	System	Topic

A 45-year-old man comes to the office for progressive weakness and fatigue over the last year. The patient was adopted and does not know his family history. After a comprehensive physical examination and laboratory evaluation, the patient undergoes genetic testing. A loss of expression mutation is identified in a gene coding for a protein found on the basolateral surface of hepatocytes and enterocytes. The protein is known to interact with the transferrin receptor. Which of the following conditions is this patient at greatest risk of developing?

- A. Basal ganglia atrophy
- B. Fat malabsorption and osteoporosis
- C. Iron deficiency anemia
- D. Liver cirrhosis and hepatocellular carcinoma
- E. Pulmonary emphysema

Submit

A 45-year-old man comes to the office for progressive weakness and fatigue over the last year. The patient was adopted and does not know his family history. After a comprehensive physical examination and laboratory evaluation, the patient undergoes genetic testing. A loss of expression mutation is identified in a gene coding for a protein found on the basolateral surface of hepatocytes and enterocytes. The protein is known to interact with the transferrin receptor. Which of the following conditions is this patient at greatest risk of developing?

- A. Basal ganglia atrophy (4%)
- B. Fat malabsorption and osteoporosis (1%)
- C. Iron deficiency anemia (39%)
- ✓ D. Liver cirrhosis and hepatocellular carcinoma (52%)
- E. Pulmonary emphysema (1%)

Omitted
Correct answer
D

52%
Answered correctly

01 sec
Time Spent

01/16/2020
Last Updated

Explanation

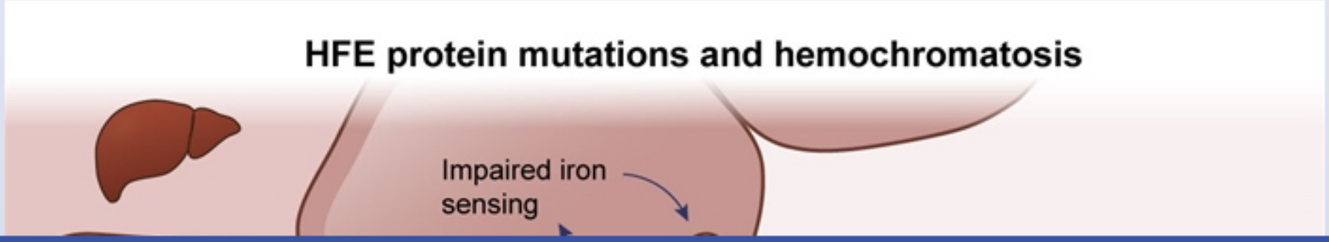

HFE protein mutations and hemochromatosis

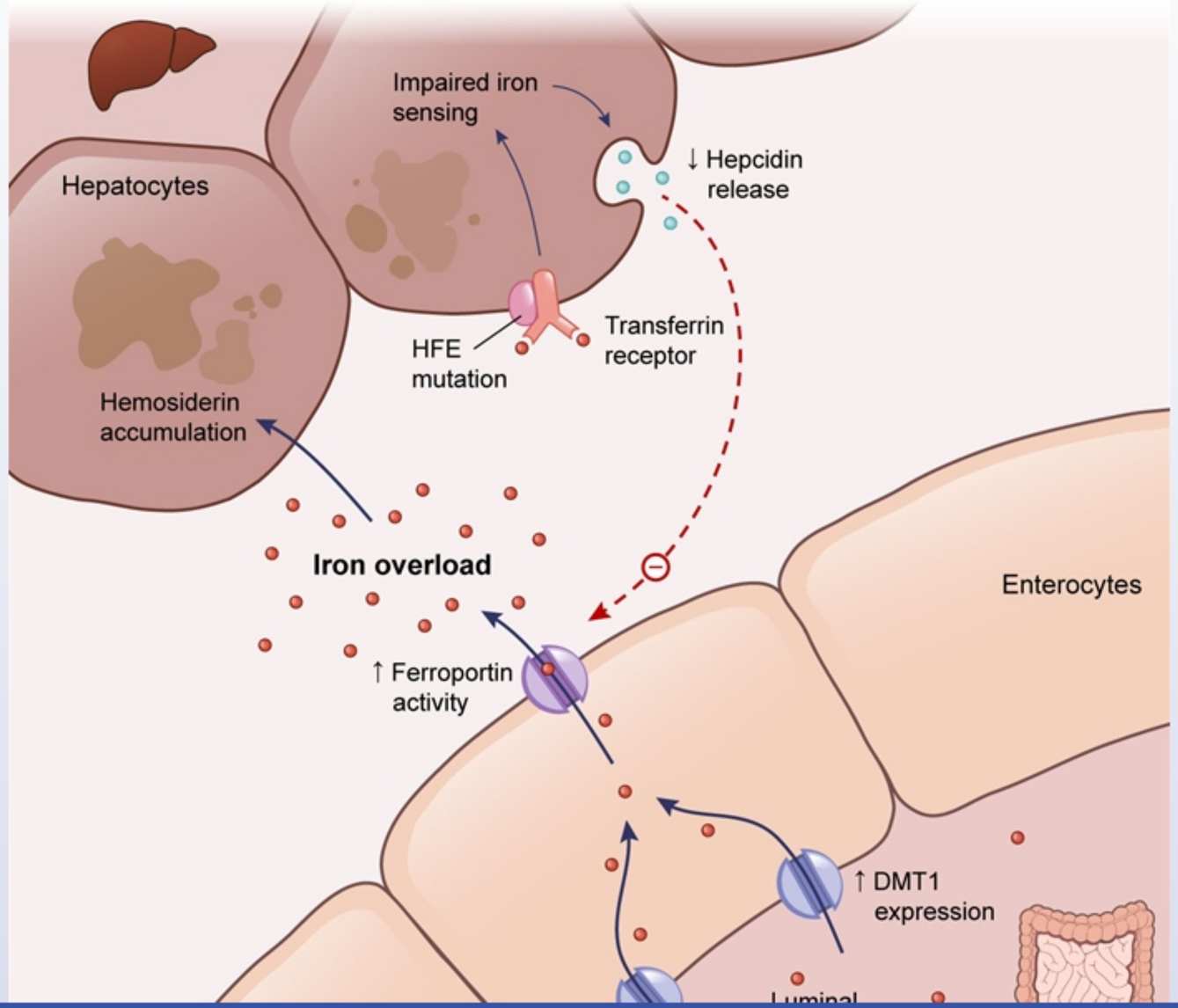

DMT1 = divalent metal transporter 1.
©UWorld

Primary hemochromatosis (ie, hereditary hemochromatosis) is most commonly caused by mutations affecting the **HFE protein**. This protein normally interacts with the transferrin receptor to form a complex that functions as a sensor of iron stores. Mutations that inactivate the HFE protein cause enterocytes and hepatocytes to **detect falsely low iron levels**. This increases iron accumulation in the body through the following 2 mechanisms:

1. **Enterocytes** respond by increasing apical expression of divalent metal transporter 1 (DMT1), increasing iron absorption from the intestinal lumen
2. **Hepatocytes** respond by decreasing hepcidin synthesis; low hepcidin levels result in increased ferroportin expression on the basolateral surface of enterocytes. This allows increased iron secretion into the circulation, leading to iron overload

When body iron levels exceed 20 g, patients typically develop the classic triad of **micronodular cirrhosis**, diabetes mellitus, and skin pigmentation (ie, "bronze diabetes"). These patients are at an increased risk for **hepatocellular carcinoma**, congestive heart failure, and testicular atrophy/hypogonadism.

(Choice A) Basal ganglia atrophy is a potential complication commonly seen in Wilson disease (ie, hepatolenticular degeneration).

(Choice B) Exocrine pancreatic function is usually preserved in patients with hemochromatosis. Therefore, fat malabsorption and osteoporosis (due to decreased vitamin D) would not typically be seen.

(Choice C) Iron deficiency anemia is a potential complication of blood loss, lack of dietary iron, or an inability to absorb iron (eg, celiac disease). Hemochromatosis results in iron overload, not iron deficiency.

(Choice E) Pulmonary emphysema is a potential complication of alpha-1 antitrypsin deficiency.

Educational objective:
HFE protein mutations are the most common cause of primary hemochromatosis. Inactivation of the HFE protein results in decreased hepcidin synthesis by hepatocytes and increased DMT1 expression by enterocytes, leading to iron overload. Patients with hemochromatosis are at an increased risk for liver cirrhosis and hepatocellular carcinoma.

References

2 mechanisms:

1. **Enterocytes** respond by increasing apical expression of divalent metal transporter 1 (DMT1), increasing iron absorption from the intestinal lumen
2. **Hepatocytes** respond by decreasing hepcidin synthesis; low hepcidin levels result in increased ferroportin expression on the basolateral surface of enterocytes. This allows increased iron secretion into the circulation, leading to iron overload

When body iron levels exceed 20 g, patients typically develop the classic triad of **micronodular cirrhosis**, diabetes mellitus, and skin pigmentation (ie, "bronze diabetes"). These patients are at an increased risk for **hepatocellular carcinoma**, congestive heart failure, and testicular atrophy/hypogonadism.

(Choice A) Basal ganglia atrophy is a potential complication commonly seen in Wilson disease (ie, hepatolenticular degeneration).

(Choice B) Exocrine pancreatic function is usually preserved in patients with hemochromatosis. Therefore, fat malabsorption and osteoporosis (due to decreased vitamin D) would not typically be seen.

(Choice C) Iron deficiency anemia is a potential complication of blood loss, lack of dietary iron, or an inability to absorb iron (eg, celiac disease). Hemochromatosis results in iron overload, not iron deficiency.

(Choice E) Pulmonary emphysema is a potential complication of alpha-1 antitrypsin deficiency.

Educational objective:
HFE protein mutations are the most common cause of primary hemochromatosis. Inactivation of the HFE protein results in decreased hepcidin synthesis by hepatocytes and increased DMT1 expression by enterocytes, leading to iron overload. Patients with hemochromatosis are at an increased risk for liver cirrhosis and hepatocellular carcinoma.

References

- Hepcidin regulation of iron transport.

Pathology	Hematology & Oncology	Hemochromatosis
Subject	System	Topic

Enterocytes

Exhibit Display

Hepcidin and body iron regulation

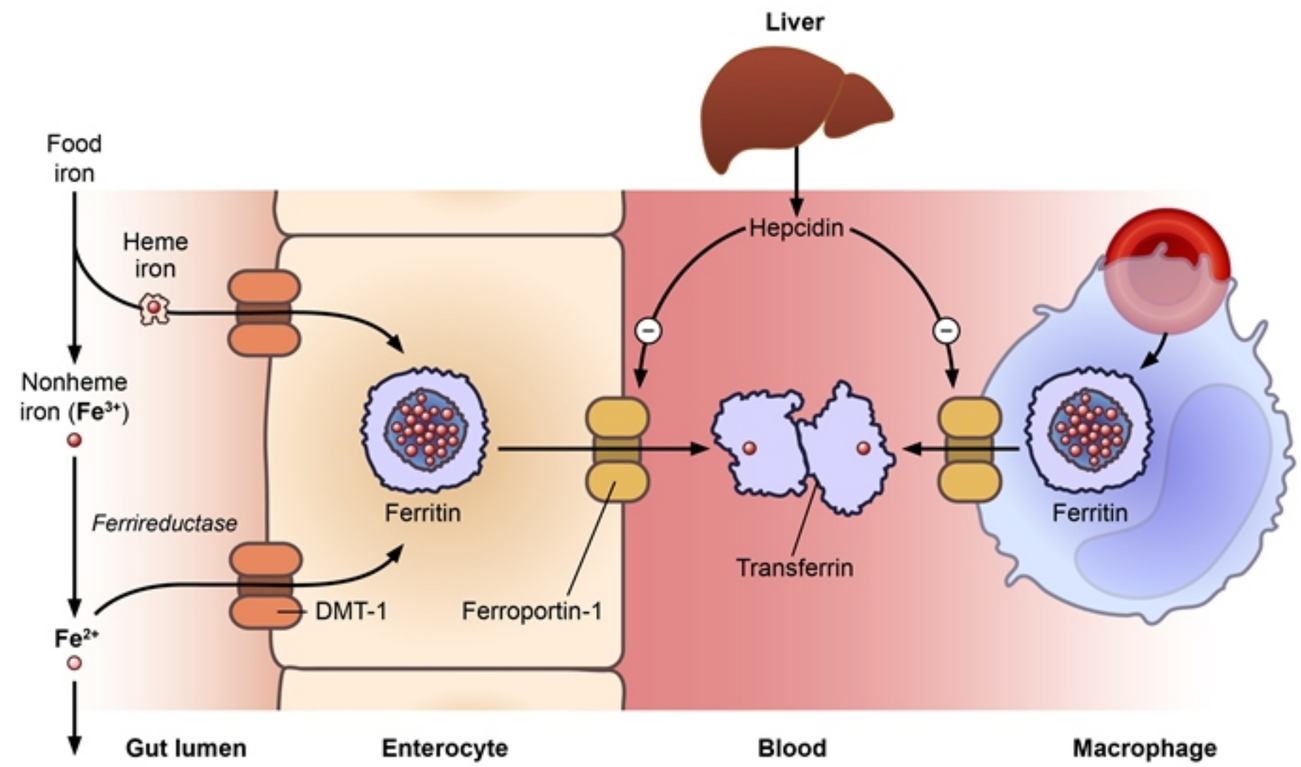

©USMLEWorld, LLC

Zoom In | Zoom Out | Reset | Add To New Card | Existing Card

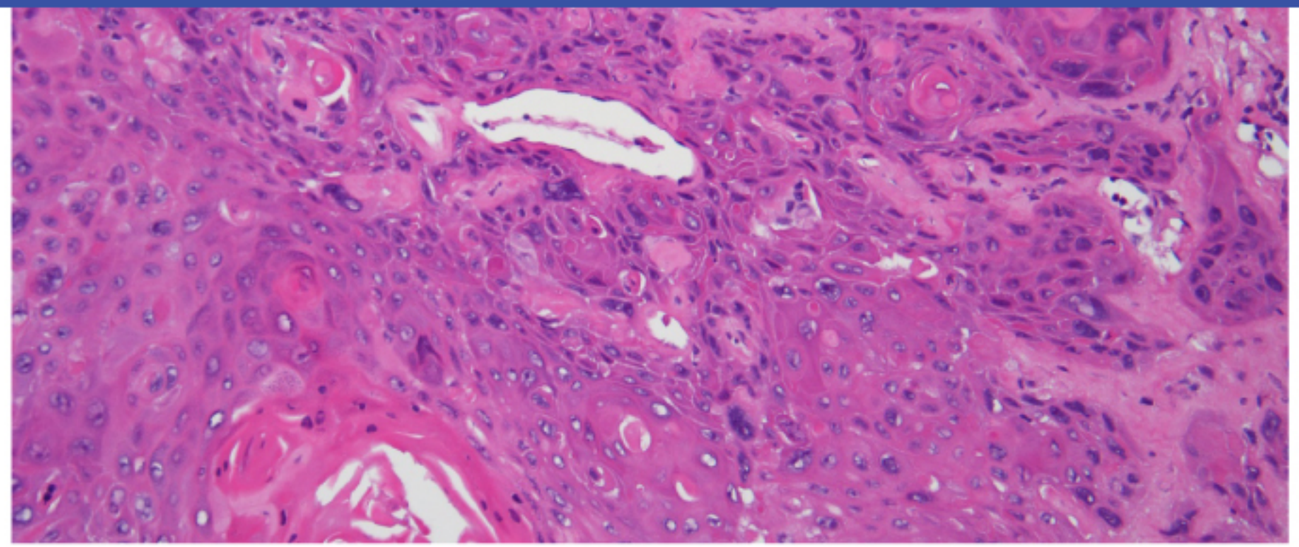

© UWorld

Which of the following most likely played the most significant role in the pathogenesis of this patient's condition?

A. Coxsackievirus

B. Epstein-Barr virus

C. Herpes simplex virus

D. Human immunodeficiency virus

E. Human papilloma virus

Submit

A 45-year-old man comes to the office due to a sore throat for the past 3 months. The patient also has pain with swallowing. He has never smoked, drinks alcohol occasionally, and does not use illicit drugs. On physical examination, the right tonsil is enlarged with a small area of ulceration. The rest of the physical examination is unremarkable. Biopsy of the right tonsil is shown in the image below:

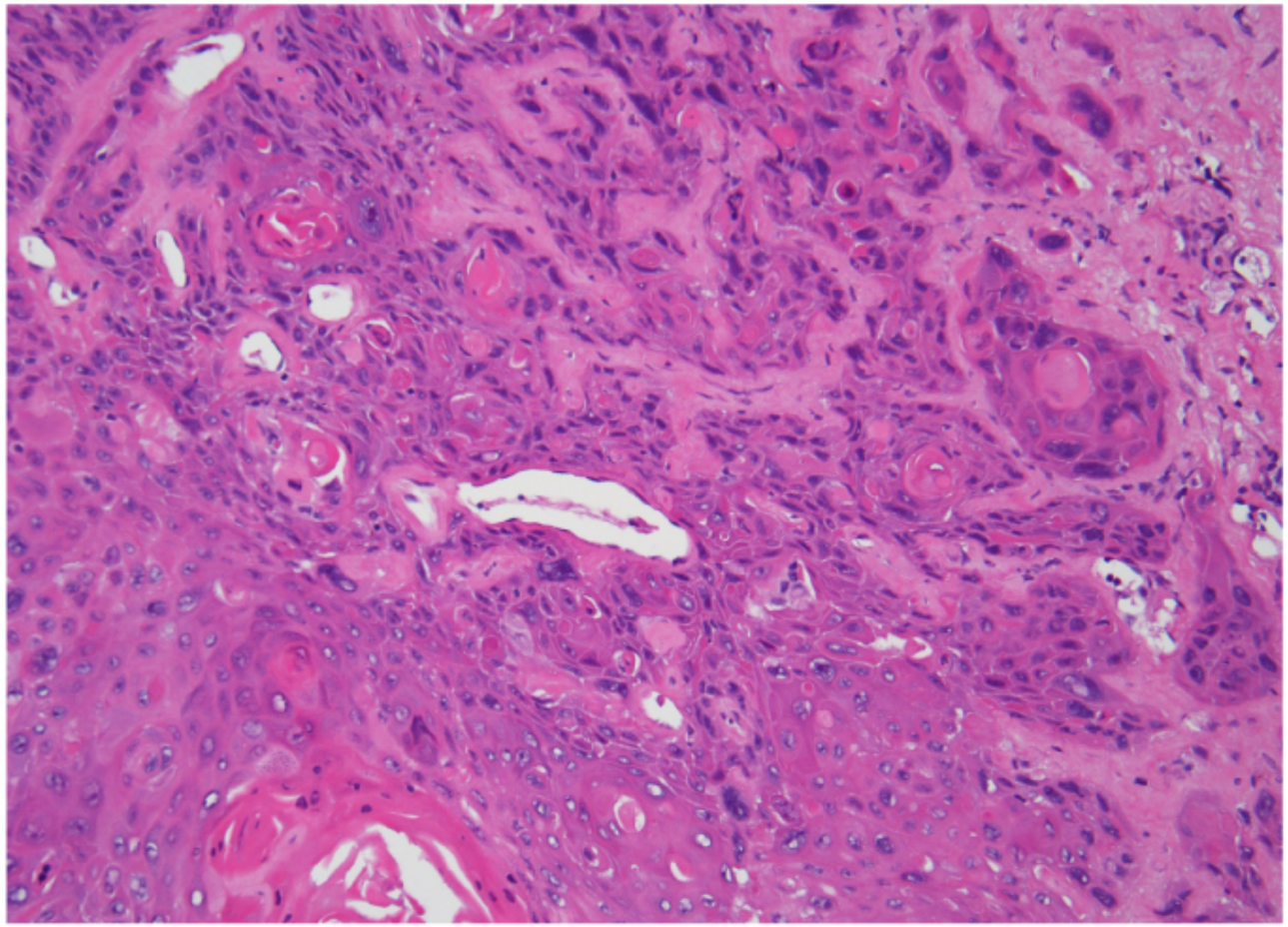

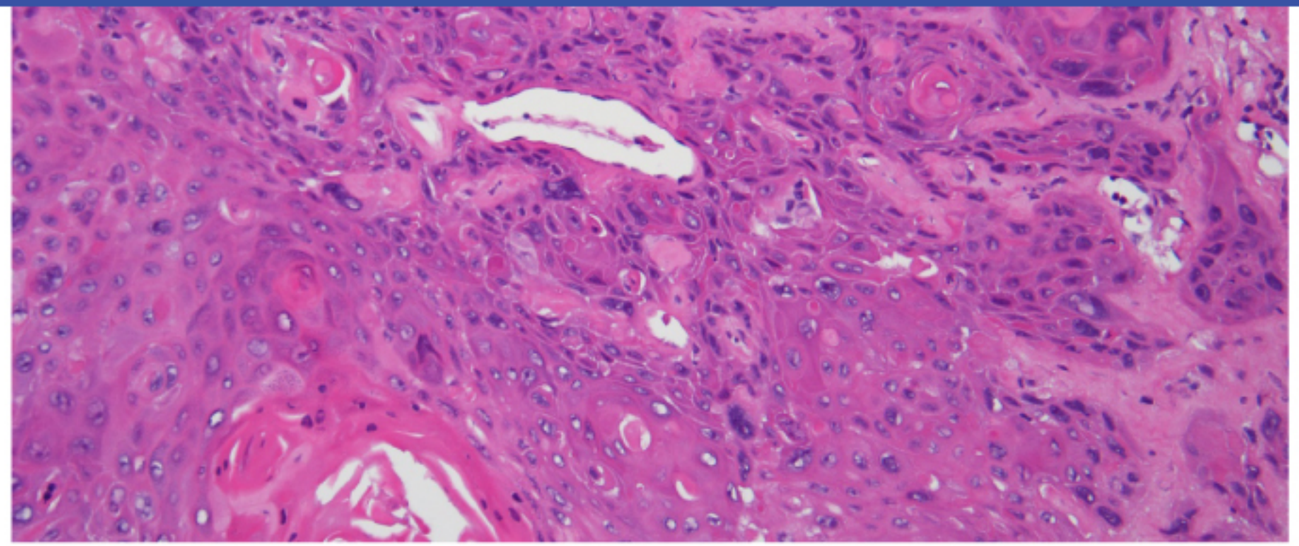

© UWorld

Which of the following most likely played the most significant role in the pathogenesis of this patient's condition?

A. Coxsackievirus

B. Epstein-Barr virus

C. Herpes simplex virus

D. Human immunodeficiency virus

E. Human papilloma virus

Submit

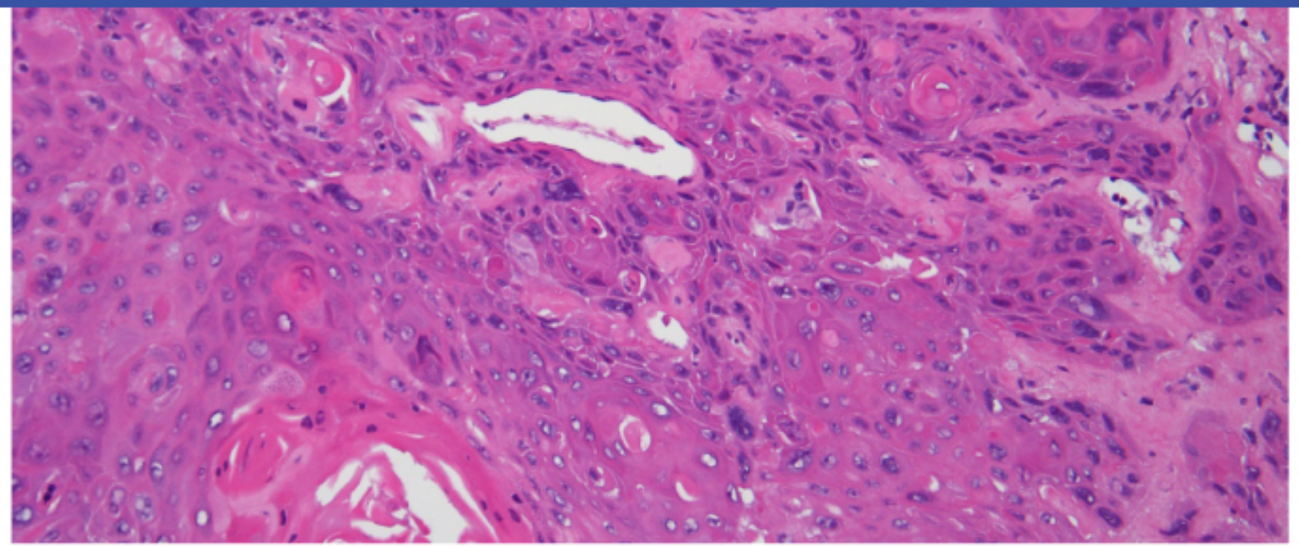

© UWorld

Which of the following most likely played the most significant role in the pathogenesis of this patient's condition?

- A. Coxsackievirus (2%)
- B. Epstein-Barr virus (34%)
- C. Herpes simplex virus (9%)
- D. Human immunodeficiency virus (4%)
- ✓ E. Human papilloma virus (48%)

Omitted
Correct answer

48%
Answered correctly

10 secs
Time Spent

04/27/2020
Last Updated

Keratinizing squamous cell carcinoma

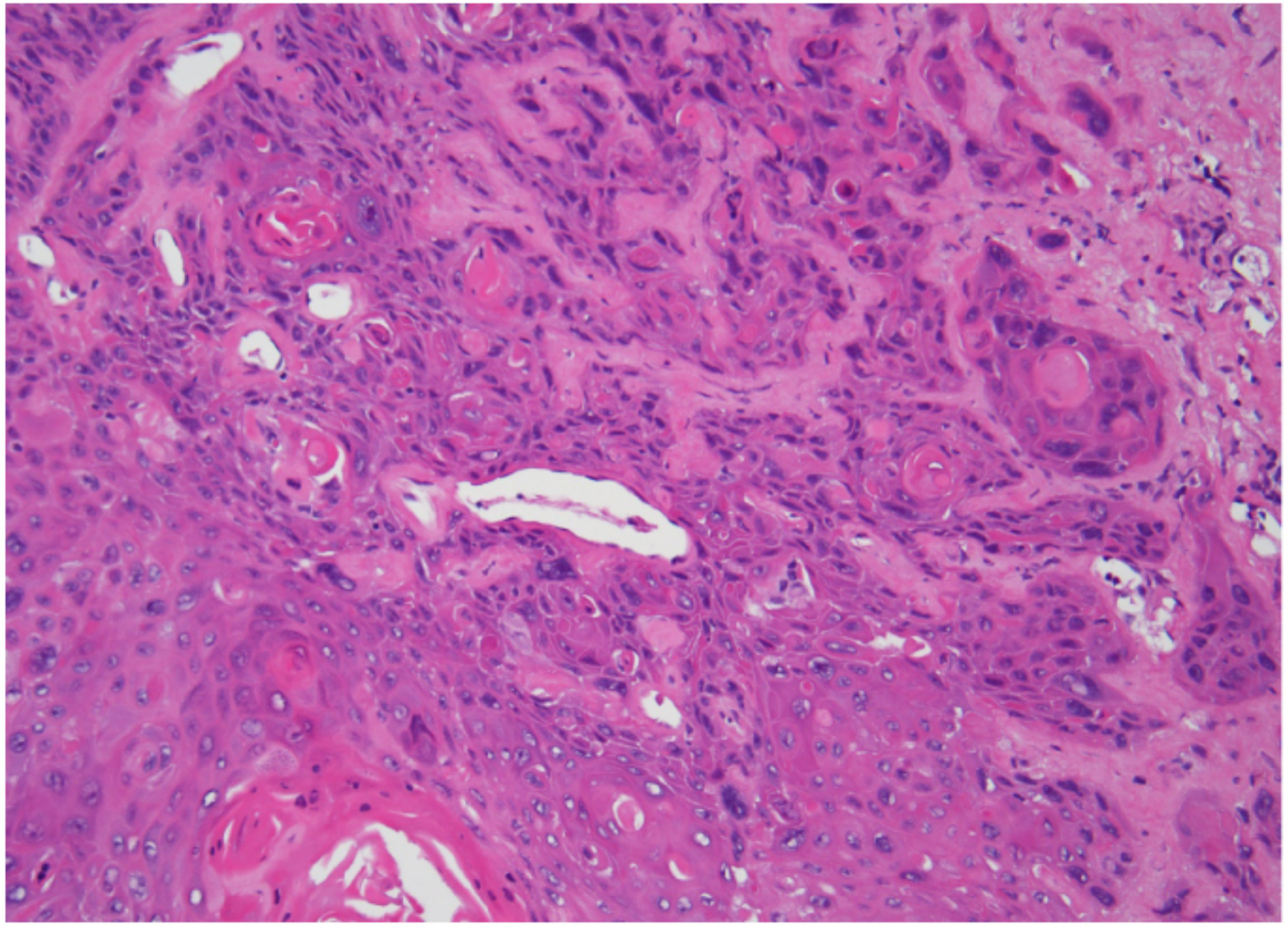

© UWorld

Biopsy of the ulcerative tonsil lesion in this patient with persistent throat pain shows malignant cells with atypical mitotic figures and keratin pearls, findings consistent with **head and neck mucosal squamous cell carcinoma** (HNSCC).

© UWorld

Biopsy of the ulcerative tonsil lesion in this patient with persistent throat pain shows malignant cells with atypical mitotic figures and keratin pearls, findings consistent with **head and neck mucosal squamous cell carcinoma** (HNSCC).

Although most head and neck cancers are linked to tobacco and excessive alcohol use, patients with **oropharyngeal carcinoma** (eg, tonsil, base of tongue) often **lack traditional risk factors**. Instead, oropharyngeal cancer is frequently associated with **human papillomavirus** (HPV) exposure, particularly in **younger** patients. HPV-positive HNSCC primarily affects the oropharynx, possibly due to the higher concentration of lymphatic tissue facilitating viral processing. The most common causative subtypes are **HPV-16 and 18**, which are covered by the HPV vaccine.

HPV is a nonenveloped, double-stranded DNA virus that infects cutaneous and mucosal tissues. Some strains (eg, HPV-1, HPV-2) cause skin warts. Others (eg, HPV-6, HPV-11) cause anogenital papillomas or papillomas that affect the upper respiratory tract (ie, recurrent respiratory papillomatosis). **High-risk strains** (eg, HPV-16, HPV-18) produce proteins **(E6, E7)** that prevent apoptosis, promote cellular proliferation, and cause genetic instability; they are also linked to cancer of the cervix, vulva, anus, and penis.

(Choice A) Coxsackievirus is the leading cause of hand-foot-and-mouth disease, which is characterized by low-grade fever, oral macules/vesicles, and a macular/papular/vesicular rash on the hands, feet, and extremities. This virus does not typically cause malignant transformation.

(Choice B) Epstein-Barr virus (EBV) can also cause HNSCC; however, it is most specifically implicated in the *nasopharynx*, rather than the oropharynx. The classic triad of nasopharyngeal carcinoma is a neck mass, nasal obstruction, and a unilateral, persistent middle ear effusion due to obstruction of the eustachian tube.

(Choice C) Herpes simplex virus causes latent infection in the sensory nerves. It is associated with vesicular lesions of the orolabial mucosa, not tonsillar ulcers, and does not cause HNSCC.

(Choice D) HIV increases the risk of many types of cancer due to immune dysregulation. The risk of cancers related to underlying infections, such as human herpesvirus 8 (Kaposi sarcoma), HPV, EBV, and hepatitis B and C viruses (hepatocellular carcinoma), is particularly increased. However, oropharyngeal cancer is most tightly linked to underlying HPV infection even in the setting of HIV.

Educational objective:
Most oropharyngeal carcinomas (eg, tonsil, base of tongue) are caused by human papilloma virus (HPV) infection. HPV-16 and HPV-18 are

warts. Others (eg, HPV-6, HPV-11) cause anogenital papillomas or papillomas that affect the upper respiratory tract (ie, recurrent respiratory papillomatosis). **High-risk strains** (eg, HPV-16, HPV-18) produce proteins **(E6, E7)** that prevent apoptosis, promote cellular proliferation, and cause genetic instability; they are also linked to cancer of the cervix, vulva, anus, and penis.

(Choice A) Coxsackievirus is the leading cause of hand-foot-and-mouth disease, which is characterized by low-grade fever, oral macules/vesicles, and a macular/papular/vesicular rash on the hands, feet, and extremities. This virus does not typically cause malignant transformation.

(Choice B) Epstein-Barr virus (EBV) can also cause HNSCC; however, it is most specifically implicated in the *nasopharynx*, rather than the oropharynx. The classic triad of nasopharyngeal carcinoma is a neck mass, nasal obstruction, and a unilateral, persistent middle ear effusion due to obstruction of the eustachian tube.

(Choice C) Herpes simplex virus causes latent infection in the sensory nerves. It is associated with vesicular lesions of the orolabial mucosa, not tonsillar ulcers, and does not cause HNSCC.

(Choice D) HIV increases the risk of many types of cancer due to immune dysregulation. The risk of cancers related to underlying infections, such as human herpesvirus 8 (Kaposi sarcoma), HPV, EBV, and hepatitis B and C viruses (hepatocellular carcinoma), is particularly increased. However, oropharyngeal cancer is most tightly linked to underlying HPV infection even in the setting of HIV.

Educational objective:
Most oropharyngeal carcinomas (eg, tonsil, base of tongue) are caused by human papilloma virus (HPV) infection. HPV-16 and HPV-18 are particularly likely to cause malignant transformation.

References

- HPV associated head and neck cancer.

Pathology	Hematology & Oncology	Head and neck cancers
Subject	System	Topic

Copyright © UWorld. All rights reserved.